

Case Series

Case series of mucormycosis occurring in patients of COVID-19

Drashti J. Patel^{1*}, Paras G. Patel¹, Purvi P. Patel¹, Brijeshkumar Sapariya¹,
Moxa B. Parmar¹, Nehal S. Diwanji²

¹Department of Pathology, ²Department of Radiology, SMIMER, Surat, Gujarat, India

Received: 21 April 2021

Revised: 16 May 2021

Accepted: 17 May 2021

***Correspondence:**

Dr. Drashti J. Patel,

E-mail: drashtipatel1216@gmail.com

Copyright: © the author(s), publisher and licensee Medip Academy. This is an open-access article distributed under the terms of the Creative Commons Attribution Non-Commercial License, which permits unrestricted non-commercial use, distribution, and reproduction in any medium, provided the original work is properly cited.

ABSTRACT

Mucormycosis is an umbrella term used for diseases caused by many non-septate filamentous fungal species which is caused by sub-phylum Mucormycotina. It is an acute opportunistic and aggressive fulminant invasive infection that can occur in immunocompromised patients, such as uncontrolled diabetes, renal failure, organ transplant, long-term corticosteroid and immunosuppressive therapy, AIDS, malignancy and corona virus disease 2019 (COVID 19) infections. Mucormycosis is now third most common invasive mycoses after candidiasis and aspergillosis. The COVID-19 infection is characterised by wide range of disease patterns, ranging from mild to life-threatening pneumonia. Many bacterial and fungal co-infections may exist and may be associated with preexisting morbidity or may develop as a hospital-acquired infection such as ventilator-associated pneumonia. Extensive use of corticosteroids and broad-spectrum antibiotics lead to exacerbation of preexisting disease. The aim of this study is to identify the risk factors along with high index of suspicion, early diagnosis and aggressive management of mucormycosis.

Keywords: Mucormycosis, Diabetes, COVID-19, Fungal infections, Nasal cavity

INTRODUCTION

Coronavirus disease 2019 (COVID-19) is contagious infection caused by inhalation of novel severe acute respiratory syndrome coronavirus-2 (SARS-CoV-2).¹ There have been many twirls in pathophysiology, diagnosis, treatment and fate of COVID-19 infections. On account of this, various complications are being emerged. Respiratory failure and acute respiratory distress syndrome (ARDS) are the most common complications of severe infections.² Many new complications are being added with each passing day.³ Amid this pandemic in India, rhino-orbital-cerebral Mucormycosis (ROCM) is came to light. It is present globally, but certain agents are prevalent in India.⁴ Mucormycosis is rare but aggressive, angioinvasive and opportunistic fungal disease caused by Mucorales. It mainly involves the patients with deranged immune system among which uncontrolled diabetes mellitus

associated with COVID-19 is being the most common cause. Current guidelines in moderate to severe COVID patients in India include intravenous methylprednisolone. Such treatment of corticosteroids in comorbid individuals mention the risk of secondary infection. Mucormycosis also catches to those who have been on oxygen support due to non-sterile tap water used in humidifier bottle, which leads to severe life-threatening fungal infection. A complex coaction of various factors such as COVID-19 infection, preexisting co-morbidity, use of immunosuppressive drugs and risk of opportunistic infections lead to secondary Mucormycosis.²

The mainstay of treatment of Mucormycosis is use of amphotericin B and surgical debridement. In this scenario, histological examination can reveal optimal uses of such nephrotoxic drug and radical surgeries.

CASE SERIES

Case 1

A 49-years-old man was admitted to the ENT ward of SMIMER hospital, Surat, India. He had complaints of pain and numbness in right side of face, fever and headache since 15 days.

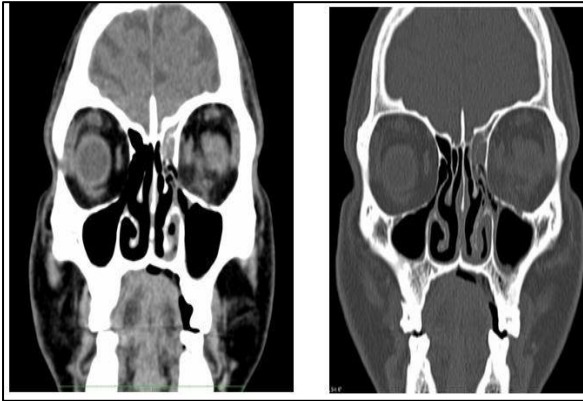


Figure 1: CT scan of paranasal sinuses.

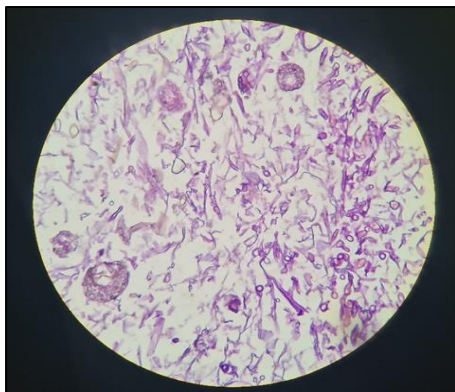


Figure 2: Hematoxylin and eosin stain of wide non-septate and empty looking hyphae characteristic of mucormycosis, 10x.

The patient was hospitalized for bilateral pneumonia and difficulty in breathing. After few days left eye discharge appeared. On examination necrotic collection was found in maxillary and sigmoid sinus and left eye proptosis. Patient had history of diabetes mellitus since 10 years. CBC was normal and RBS 403 mg%, SPO2 92%.

RT-PCR for COVID-19 was positive and HRCT shows ground glass opacities with interlobular septal thickening in subpleural, antral and peri-bronchiolar regions, S/O atypical viral etiology- CORAD-5. Interleukin-6 103.9 pg/ml, D-dimer 169 ng/ml, CRP 30.1 mg/L. Intravenous tocilizumab was given along with routine COVID treatment.

CT scan of the paranasal sinuses (PNS) was performed. Mucosal thickening noted in the left frontal, ethmoid,

maxillary and bilateral sphenoid sinuses. Bone erosions involving inferior and medial wall of left orbit also seen. Possibility of acute invasive fungal sinusitis suggested (Figure 1). Treatment including injection Amphotericin B course was administered, and debridement of sinuses, FESS was performed using a video endoscopy.

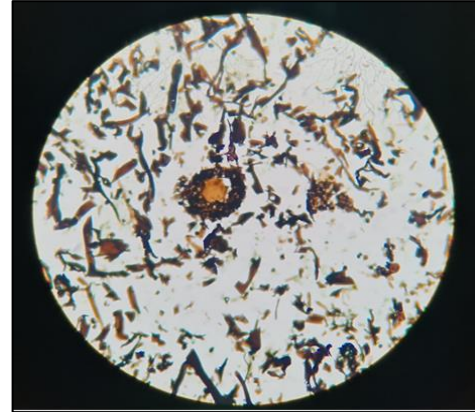

Figure 3: GMS (Grocott methenamine silver) stain of biopsy, showing dense colonies of broad, aseptate and irregular branching filamentous hyphae-mucormycosis in necrotic background.

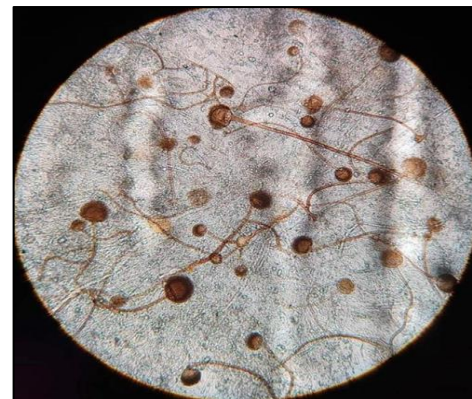

Figure 4: KOH mount from the growth showed aseptate hyphae along with nodal rhizoids and short sporangiophores and globose sporangia filled with brownish sporangiospores, suggestive of *Rhizopus* microspores.

Disease was progressive and patient was admitted 4 times in last six months for recurrent invasive fungal sinusitis. Biopsy was sent three times and histopathological findings of Mucormycosis (Figure 2) was noted in all biopsies which was confirmed by Periodic acid-Schiff (PAS) and Grocott methenamine silver (GMS) stain (Figure 3). Fungal KOH mount was performed three times and nonseptate hyphae with branched sporangiospores were seen in one tissue biopsy, which was identified as Mucormycosis (Figure 4).

At present patient is discharged from hospital and having no complaints.

Case 2

A 49-years-old man who had complaints of nasal congestion, nasal discharge, difficulty in breathing and raw area in mouth since 15 days. He had past history of COVID 19 infection before a month. He was admitted to the ENT ward of SMIMER hospital, Surat, India. He had 2 years' history of diabetes (diabetes mellitus type 2). Biochemical tests indicated data on FBS of 370 mg/dl and HbA1c of 10%.

CT Paranasal sinuses showed deviated nasal septum to the right and bilateral inferior turbinate hypertrophy. Bilateral maxillary, ethmoidal and sphenoid sinusitis. Occlusion of the right osteomeatal unit, bilateral fronto-ethmoidal and sphenoidal recesses. Ground glass attenuation with few air foci seen involving the hard palate and maxillo-osteitis.

Histopathological findings from biopsy of necrotic tissue from bilateral nasal cavity showed aseptate hyphae in necrotic tissue (Figure 5). PAS and GMS stain for fungus was done for confirmation. Figure 6 dictate PAS positive wide and irregular hyphae. The culture result was positive. Debridement of sphenoidal sinus and necrotic tissues was done and treatment including injection Amphotericin B course was prescribed.

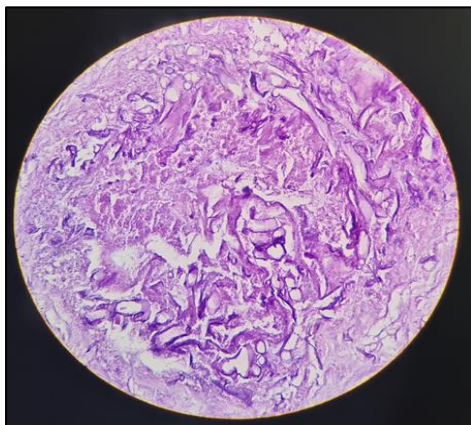


Figure 5: Hematoxylin and eosin stain of wide non-septate hyphae characteristic of mucormycosis; 40x.

Case 3

A 68-years-old man had left sided facial pain since 1 month. Past history of COVID-19 before 1.5 months.

CT paranasal sinuses showed mucosal thickening in left frontal, maxillary, sphenoid sinuses and left ethmoid air cells. S/O infective sinusitis.

Opacification of paranasal sinuses and nasal cavity was seen, mainly on the right side which was extent end to the right orbit. Due to involvement of fundus of right orbit and optic Cochleate-amphotericin B was prescribed and maxillary and ethmoid sinuses were debrided.

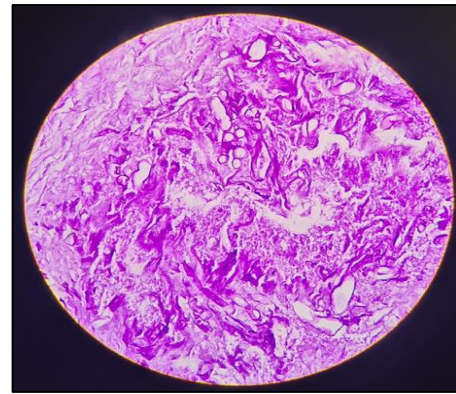


Figure 6: PAS stain showing the presence of broad-based, irregularly branching hyphae characteristic of mucormycosis, 40x.

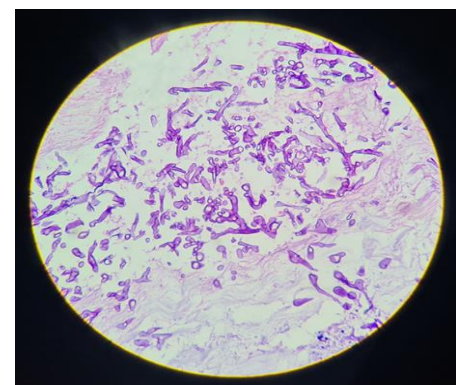


Figure 7: Hematoxylin and eosin stain of wide non-septate hyphae, 10x.

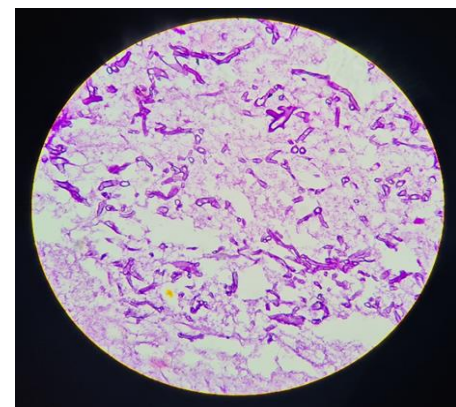


Figure 8: PAS stain showing the presence of wide, irregularly branching hyphae, 40x.

A biopsy specimen from left maxillary sinus and left sphenoid sinus was taken. Hematoxylin and eosin stain displayed broad aseptate hyphae with granuloma formation in the background of necrotic debris (Figure 7), but in this case, the isolate did not grow on the synthetic media. PAS stain was positive for fungus (Figure 8). Few weeks later, posaconazole was added to his antifungal regimen. After 15 days he was stable and discharged.

DISCUSSION

Mucormycosis is very rapidly progressive disease and may prove fatal if timely diagnosis and treatment are not given. Several genera are associated with this disease, the most common forms are *Rhizopus*, *Rhizomucor* and *Absida*. *Rhizopus* is the predominant pathogen accounting for 90% of the cases of rhinocerebral mucormycosis.⁵ According to its clinical presentation and site, invasive mucormycosis is classified in 6 major clinical forms: rhinocerebral, pulmonary, cutaneous, gastrointestinal, disseminated, and uncommon rare forms, such as endocarditis, osteomyelitis, peritonitis, and renal infection.⁶

Rhinocerebral mucormycosis is most common and fulminating type of mucormycosis, which may lead to fatal consequences if left untreated especially in patients of diabetes mellitus, hyperglycemia, ketoacidosis, leukemia and lymphoma. It is spread by inhalation of affected mold spores in the air via nasal mucosa to turbinate bones, paranasal sinuses, orbit and palate with extension into brain where massive invasion of blood vessels cause major infarct. The symptoms include facial pain, headache, nasal discharge and nasal congestion. Physical examination reveals brownish, bloodstained nasal discharge, black eschar on palate, tissue necrosis, fixed and dilated pupil, proptosis, ptosis and visual loss in later stages. Infection may disseminate to lungs and other organs.

Diabetes is India's fastest growing epidemic. A recent cross-sectional study from all states of India, revealed that 47% of Indians are unaware of their diabetic status and only a quarter of all patients achieved adequate glycemic control on treatment.⁷

In pandemic of COVID-19, with the absence of an effective vaccine or antiviral therapy, supportive treatment with glucocorticoids and remdesivir play vital role in COVID-19 management. Glucocorticoids are inexpensive, widely available, and have been shown to reduce mortality in hypoxemic patients with COVID-19.⁸

Steroids can cause drug induced hyperglycemia by making liver resistant to insulin.⁹ They not only exacerbate hyperglycemia in patients of diabetes mellitus, but also cause diabetes mellitus in patients without documented hyperglycemia before the initiation of glucocorticoids therapy.¹⁰ Higher blood sugar levels and more acidic blood creates a fertile environment for Mucorales fungi to thrive.

Glucocorticoids increase the risk of secondary infections. The immune dysregulation caused by reduced numbers of T lymphocytes, CD4+T, and CD8+T cells by the virus and the use of concurrent immunomodulatory drugs such as tocilizumab could further increase the risk of infections in COVID-19 patients.^{11,12}

Invasive mucormycosis has been diagnosed in mild to moderate SARS-CoV-2 infections. In undiagnosed or uncontrolled diabetics, the strongest predisposing factor

appears to be hyperglycemia which leads to increased expression of the endothelial receptor GRP78, resulting in polymorphonuclear dysfunction, impaired chemotaxis and defective intracellular killing.¹³

In histological examination of tissue involved by mucormycosis show varying amounts of necrosis which is infiltrated by higher number of fungal organisms.¹⁴

These fungal elements include broader hyphae, which can point out histological differential diagnosis of mucormycosis. Special stains for fungus and microbiological culture from necrotic tissue confirm the diagnosis. By this protocol, the histopathologists can help the clinician in assessing prognosis at the time of tissue diagnosis, and thus considering the risk/benefit, the clinicians could optimize the treatment accordingly.¹⁴

CONCLUSION

COVID-19 is associated with a higher incidence of secondary infections, including fungal infection because of immune dysregulation. Moreover, widespread use of glucocorticoids in COVID-19 causes deterioration of preexisting fungal diseases. So, the clinicians must be aware of possibility of invasive fungal infection in such COVID patients with history of diabetes and other comorbidities. Unless diagnosed and treated early, this type of mucormycosis is often fatal due to cerebral involvement. Early diagnosis with surgical excision, appropriate debridement, proper antifungal treatment and management of risk factors lead to subsequent reduction in mortality and morbidity.

Funding: No funding sources

Conflict of interest: None declared

Ethical approval: Not required

REFERENCES

1. Alinaghi S, Afsahi AM, Pour M, Behnezhad F, Salehi MA, Barzegary A, et al. Late Complications of COVID-19; a Systematic Review of Current Evidence. *Arch Acad Emerg Med.* 2021;9(1):e14.
2. Sharma S, Grover M, Bhargava S, Samdani S, Kataria T. Post coronavirus disease mucormycosis: a deadly addition to the pandemic spectrum. *J Laryngol Otol.* 2021;1-6.
3. Prakash, H.; Chakrabarti, A. Epidemiology of Mucormycosis in India. *Microorganisms.* 2021;9: 523.
4. Tamez-Pérez HE, Quintanilla-Flores DL, Rodríguez-Gutiérrez R, González-González JG, Tamez-Peña AL. Steroid hyperglycemia: Prevalence, early detection and therapeutic recommendations: A narrative review. *World J Diabetes.* 2015;6(8):1073-81.
5. Auluck A. Maxillary necrosis by mucormycosis. A case report and literature review. *Med Oral Patol Oral Cir Bucal.* 2007;12:360-4.

6. Petrikkos G, Skiada A, Patel J, Roilides E, Thomas J, Walsh, Dimitrios P. Kontoyiannis. Epidemiology and Clinical Manifestations of Mucormycosis, *Clinical Infectious Diseases.* 2012;54:S23-34
7. Prenissl J, Jaacks LM, Mohan V. Variation in health system performance for managing diabetes among states in India: a cross-sectional study of individuals aged 15 to 49 years. *BMC Med.* 2019;17:92.
8. Sterne JAC, Murthy S, Diaz JV, Slutsky AS, Villar J. Association between administration of systemic corticosteroids and mortality among critically ill patients with COVID-19 a meta-analysis. *JAMA.* 2020;324(13):1330-41.
9. Trence DL. Management of patients on chronic glucocorticoid therapy: an endocrine perspective. *Prim Care.* 2003;30:593-605.
10. Orlandi M, Lepri G, Bruni C, Wang Y, Bartoloni A, Zammarchi L, et al. The systemic sclerosis patient in the COVID-19 era: the challenging crossroad between immunosuppression, differential diagnosis and long-term psychological distress. *Clinical Rheumatology.* 2020;39(7), 2043-7.
11. Kumar G, Adams A, Herrera M, Rojas ER, Singh V, Sakhuja A, et al. Predictors and outcomes of hais in COVID-19 patients. *Int J Infect Dis.* 2020;104(3):287-92.
12. Kimmig LM, Wu D, Gold M, Pettit NN, Pitrak D, Mueller J, et al. IL-6 inhibition in critically ill COVID-19 patients is associated with increased secondary infections. *Front Med (Lausanne)* 2020;7:583897.
13. Soman R, Sunavala A. Post COVID-19 Mucormycosis - from the Frying Pan into the Fire. *Journal of the association of Physicians of India.* 2021;69:13-14.
14. Goel A, Kini U, Shetty S. Role of histopathology as an aid to prognosis in rhino-orbito-cerebral zygomycosis. *Indian J Pathol Microbiol.* 2010;53:253-7.

Cite this article as: Patel DJ, Patel PG, Patel PP, Sapariya B, Parmar MB, Diwanji NS. Case series of mucormycosis occurring in patients of COVID-19. *Int J Res Med Sci* 2021;9:1746-50.