

Case Report

Anesthetic management of pulmonary endarterectomy in a patient with suprasystemic pulmonary pressure: a case report

Pravinkumar H. Patel*, Harvesp Panthakey, Sandip Katkade, Hemant Mehta

Department of Anesthesia and Pain Management, Sir H. N. Reliance Foundation Hospital, Mumbai, Maharashtra, India

Received: 14 April 2020

Accepted: 05 May 2020

*Correspondence:

Dr. Pravinkumar H. Patel,

E-mail: dr.pravinpatel7@gmail.com

Copyright: © the author(s), publisher and licensee Medip Academy. This is an open-access article distributed under the terms of the Creative Commons Attribution Non-Commercial License, which permits unrestricted non-commercial use, distribution, and reproduction in any medium, provided the original work is properly cited.

ABSTRACT

Pulmonary endarterectomy (PEA) is a potentially curative procedure for chronic thromboembolic pulmonary hypertension. A 34-year Indian male presented with supra-systemic pulmonary pressure was taken for PEA after achievable optimization. A successful PEA was performed with the help of total cardiac arrest. Patient developed reperfusion pulmonary edema post operatively, which was managed medically. The problems encountered by anesthesiologists in this case were preoperative pulmonary hypertension with chronic hypoxia and postoperative management of reperfusion pulmonary edema.

Keywords: Anesthetic management, Chronic thromboembolic pulmonary hypertension, Pulmonary endarterectomy, Reperfusion pulmonary edema

INTRODUCTION

Chronic thromboembolic pulmonary hypertension (CTEPH) is characterized by intraluminal organized fibrous clot leading to complete obliteration of the pulmonary arteries, resulting in increased pulmonary vascular resistance (PVR), pulmonary hypertension (PH) and finally right heart failure.¹ Pulmonary endarterectomy (PEA) is currently the most appropriate treatment for CTEPH; medical management offers only limited and temporary relief from the symptoms.² Other alternative to PEA is lung transplantation; however, PEA has advantages like lower surgical mortality, improved long term survival, fewer long-term complications and no postoperative immunosuppressive therapy.

CASE REPORT

A 34-year male, nonsmoker and protein C deficient was admitted with New York Heart Association (NYHA) 4 symptoms. After acceptable optimization, patient was

posted for pulmonary endarterectomy. Preoperative investigation were performed including electrocardiogram (S1Q3T3), chest X-ray, 2 dimensional echocardiography showing left ventricular ejection fraction 60%, Catheterization study showed supra-systemic pulmonary pressure and pulmonary vascular resistance index as 124/38/70 mmHg and 48.6 WU/m² respectively. Lung ventilation perfusion (V/Q) study and computed tomography pulmonary angiography (CTPA) scan showing right and left pulmonary artery embolus (Figure 1). In preoperative area, oxygen was started at 2.5 lit/min via nasal prongs as the room air oxygen saturation was 81%. Fiberoptic bronchoscope, bronchial blocker, double lumen tube and extracorporeal membrane oxygenation (ECMO) were made available preoperatively to counteract bronchial bleed intraoperatively. After securing all invasive lines under local anesthesia, induction was started with minimum dose of noradrenaline and adrenaline preemptively to maintain systemic vascular resistance (SVR). Midazolam, fentanyl and etomidate were used for induction with

rocuronium as a muscle relaxant. Isoflurane was used as maintenance with 50% oxygen in air along with midazolam, fentanyl and atracurium. Transesophageal echocardiography (TEE) probe guided after induction and Swan-Ganz catheter inserted after median sternotomy. Post induction blood pressure (BP) and pulmonary artery pressure (PAP) were 97/50 mmHg and 153/43 mmHg respectively. Nitric oxide (NO) at 20 ppm via inhalation and milrinone were started to neutralize the rise of pulmonary pressure. After cardio pulmonary bypass (CPB) and with 4 cycle of total cardiac arrest (TCA), pulmonary arteries were dissected and endarterectomy performed (Figure 2).

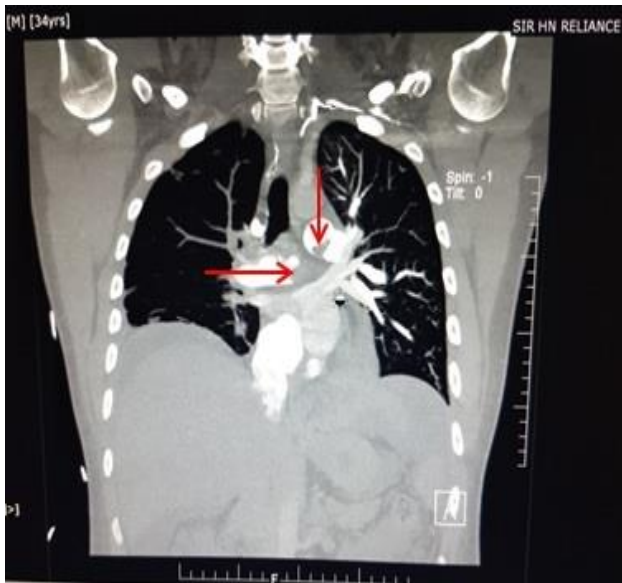

Figure 1: CTPA of embolus in right and left pulmonary artery (red arrows).

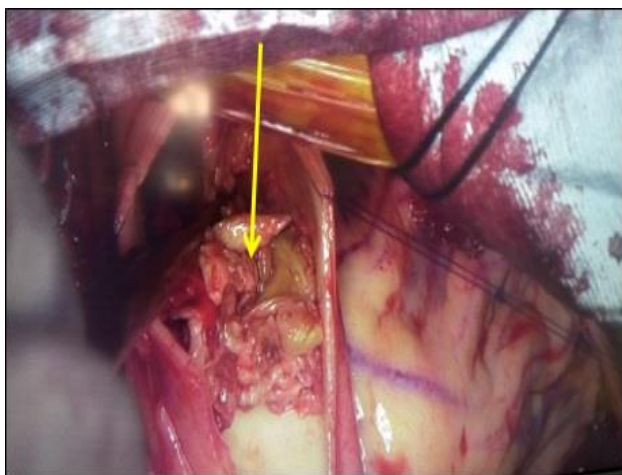

Figure 2: Pulmonary embolus in pulmonary artery (yellow arrow).

Post procedure BP and PA pressure were 124/42 mmHg and 64/16 mmHg respectively, with inotropic supports. Patient developed reperfusion pulmonary edema on 2nd postoperative day (Figure 3) in intensive care unit (ICU),

which was managed conservatively. Patient was extubated on 4th postoperative day and discharged on 10th postoperative day.

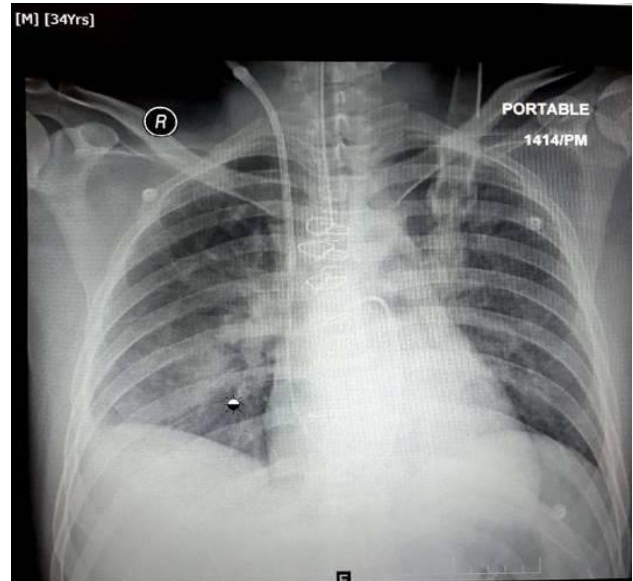


Figure 3: Chest X-ray of reperfusion pulmonary edema.

DISCUSSION

Pulmonary endarterectomy is a technically demanding procedure currently performed in very few selected centers across the globe. Challenges faced during management were chronic hypoxia, supra-systemic pulmonary pressure and residual pulmonary edema. TEE proved helpful not only to locate pulmonary thrombi but also for immediate detection of residual emboli post procedure and in monitoring of cardiac performance. Inotropes may be required both before induction as well as after weaning from CPB due to presence of right ventricular dysfunction in these patients. Authors used inotropes prior to induction as well as post operatively to maintain SVR. One of the most commonly used pulmonary vasodilator agent is milrinone, a phosphodiesterase-3 inhibitor.³ For selective pulmonary vasodilatation, the most investigated agent is NO, which acts directly on pulmonary smooth muscle to cause localized vasodilatation. Thus, pulmonary vascular resistance is decreased with increased right ventricular output, VQ matching is improved, and SVR is unchanged.⁴ Both were used to tackle the supra-systemic pulmonary pressure.

Two of the most severe complications of PEA are airway bleeding and reperfusion pulmonary edema.⁵ Later was found in this case patient on 2nd postoperative day which was managed with continued mechanical ventilation with lung protective strategy, furosemide and riociguat, which is the first approved medication from the class of soluble guanylate cyclase (sGC) stimulator for CTEPH management.⁶

CONCLUSION

A successful outcome of PEA depends on the proper preoperative diagnosis, evaluation, treatment of pulmonary hypertension (PH), intraoperative care and conscientious postoperative management. Complications such as reperfusion injury and persistent PH should be remembered and needs multidisciplinary approach for management.

Funding: No funding sources

Conflict of interest: None declared

Ethical approval: Not required

REFERENCES

1. Banks DA, Pretorius GV, Kerr KM, Manecke GR. Pulmonary endarterectomy: part I. Pathophysiology, clinical manifestations, and diagnostic evaluation of chronic thromboembolic pulmonary hypertension. In Seminars in cardiothoracic and vascular anesthesia 2014;18(4):319-30.
2. Lewczuk J, Piszko P, Jagas J, Porada A, Sobkowicz B, Wrabec K, et al. Prognostic factors in medically treated patients with chronic pulmonary embolism. Chest. 2001;119(3):818-23.
3. Tempe DK. Perioperative management of pulmonary hypertension. Ann Card Anaesth. 2010;13(2):89-91.
4. McNeil K, Dunning J, Morrell N. The pulmonary physician in critical care• 13: The pulmonary circulation and right ventricular failure in the ITU. Thorax. 2003;58(2):157.
5. Manecke Jr GR, Kotzur A, Atkins G, Fedullo PF, Auger WR, Kapelanski DP, Jamieson SW. Massive pulmonary hemorrhage after pulmonary thromboendarterectomy. Anesth Analg. 2004;99(3):672-5.
6. Makowski CT, Rissmiller RW, Bullington WM. Riociguat: a novel new drug for treatment of pulmonary hypertension. Pharmacotherapy: J Human Pharmacol Drug Ther. 2015;35(5):502-19.

Cite this article as: Patel PH, Panthakey H, Katkade S, Mehta H. Anesthetic management of pulmonary endarterectomy in a patient with suprasystemic pulmonary pressure: a case report. Int J Res Med Sci 2020;8:2323-5.