

Original Research Article

Abdominal tuberculosis: a surgical emergency

Rajandeep Singh Bali, Rahul Jain, Yawar Zahoor*, Ankul Mittal

Department of General Surgery, Maulana Azad Medical College and Lok Nayak Hospital, New Delhi, India

Received: 20 July 2017

Accepted: 24 July 2017

***Correspondence:**

Dr. Yawar Zahoor,

E-mail: dr.yawar@hotmail.com

Copyright: © the author(s), publisher and licensee Medip Academy. This is an open-access article distributed under the terms of the Creative Commons Attribution Non-Commercial License, which permits unrestricted non-commercial use, distribution, and reproduction in any medium, provided the original work is properly cited.

ABSTRACT

Background: To study and assess the clinico-pathologic profile, intra-operative findings, surgical intervention performed and outcome in terms of morbidity and mortality of the patients included in the study group.

Methods: This study was carried out at Lok Nayak Hospital and Maulana Azad Medical College, New Delhi, a tertiary care hospital between November 2011 to March 2015. It was a retrospective study in which the records of the patients operated upon in the emergency department as peritonitis or acute intestinal obstruction and whose diagnosis was later confirmed as tuberculosis on histopathology were analysed with regards clinic-pathologic profile, intra-operative findings, surgical intervention performed and outcome in terms of morbidity and mortality.

Results: The mean age of our study group was 28.7 years. 70% of our patients were found to be in the underweight category and 30% were in the normal category. Forty three (56.6%) presented to the hospital with features suggestive of peritonitis and thirty-three (43.4) were suffering from acute intestinal obstruction. The commonest intra-operative finding encountered was ileal perforation followed by multiple small bowel perforations, solitary stricture of the small bowel with perforation, ileo-cecal mass, adhesions or bands, single or multiple strictures, stricture with impending small bowel perforation and jejunal perforation. The frequently performed surgical procedures were ileostomy, resection and anastomosis of the involved bowel, primary repair of the perforation, right hemicolectomy, adhesiolysis, stricturoplasty (done in case of single stricture, mostly), jejunostomy and peritoneal and omental biopsy.

Conclusions: Tuberculosis is a very grave disease, studies with larger number of patients need to be conducted to standardise its surgical management as at present there is no standardised surgical management protocol.

Keywords: Abdominal tuberculosis, No standardised management protocol, Varied presentation

INTRODUCTION

The earliest recorded connection between tuberculosis and gastro-intestinal symptoms was found by Hippocrates in the 5th century BC, when he recorded that diarrhoea in a person with phthisis was a mortal symptom.¹

Tuberculosis is a communicable disease caused by *Mycobacterium tuberculosis*. It has been declared a global emergency by WHO. It can affect all the systems of our body with abdominal tuberculosis being the 6th most common site of affection in extra-pulmonary tuberculosis after lymphatic, genitourinary, bone and

joint, military and meningeal tuberculosis.^{2,3} According to WHO, nearly one third of the world population is affected by tuberculosis with the highest incidence observed in South-East Asia followed by Western Pacific regions, India, China, Indonesia and Pakistan.^{4,5}

In this country, the exact prevalence of abdominal tuberculosis has not been determined due to the lack of proper surveys whereas the intestinal tuberculosis forms a very significant cause of various intestinal pathologies. Gastro-intestinal tract, peritoneum, lymph nodes and solid organs (liver, spleen and pancreas) are the four areas of involvement in abdominal tuberculosis.⁶

Intestinal tuberculosis afflicts in three forms, i.e., ulcerative, hypertrophic or ulcero-hypertrophic and fibrous (stricture) type. Peritoneal involvement may present as ascitis, loculated, plastic or purulent forms. Mesentric and retro-peritoneal lymph nodes when affected may get caseated and calcify later. Focal granulomas, generally multiple, are found involving the solid intra-abdominal viscera. Involvement of the gastro-intestinal tract, peritoneum, lymph nodes and solid organs simultaneously is the disseminated abdominal form of the disease.^{7,8}

Abdominal tuberculosis may present in acute, chronic or acute on chronic forms and yet many at times it may be an incidental finding.⁹ In the chronic form fever, pain, altered bowel habits, anorexia, weight loss and malaise are the most common symptoms of abdominal tuberculosis. Perforation peritonitis due to bowel perforation or acute intestinal obstruction are the acute presentations of abdominal tuberculosis.^{10,11} Abdominal tuberculosis (uncomplicated) is mainly managed by anti-tubercular drugs but the complications, such as perforation peritonitis and acute intestinal obstruction, require prompt surgical intervention followed by anti-tubercular drug therapy.¹²

The objective of this study was to study and assess the clinico-pathologic profile, intra-operative findings, surgical intervention performed and outcome in terms of morbidity and mortality of the patients included in the study group.

METHODS

The study was a retrospective study conducted at Lok Nayak Hospital and Maulana Azad Medical College, New Delhi, a tertiary care hospital. The records of the patients operated upon, in the Surgery emergency department, as perforation peritonitis or acute intestinal obstruction and whose diagnosis was later on confirmed by histopathology to be tuberculosis were included in the study. The study included patients operated between November 2011 and March 2015. Case records of the patients were retrospectively analysed with regards to clinic-pathologic profile, intra-operative findings, surgical intervention performed and outcome in terms of morbidity and mortality. All the patients were adequately resuscitated with intra-venous fluids before being operated upon under the cover of broad spectrum parenteral antibiotics (amoxy-clavulanate and metronidazole). Post operatively after conformation of the histopathology report, patients were started on oral anti tubercular intensive phase drugs. Discharged patients were kept on regular follow up.

RESULTS

This study group consisted of 76 patients, out of which 46 were male and 30 were female. The youngest patient was a 13 years old boy and the eldest was a 73-year-old

lady. The mean age of our study group was 28.7 years. According to the WHO BMI classification, 70% of our patients were found to be in the underweight category and 30% were in the normal category. Forty three (56.6%) presented to the hospital with features suggestive of peritonitis and thirty-three (43.4) were suffering from acute intestinal obstruction.

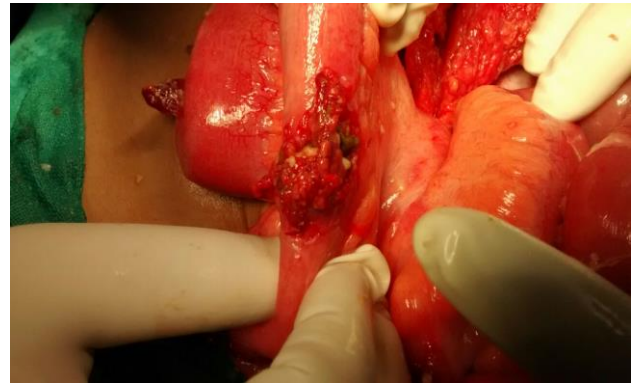

Figure 1: Intraoperative finding of tubercular ileal perforation.

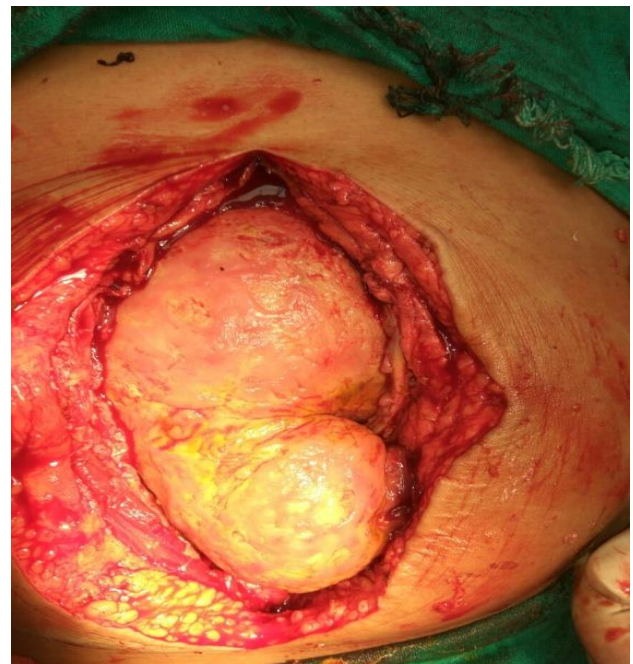


Figure 2: Intraoperative finding of with dense adhesion of bowel loops due to tuberculosis.

The commonest intra-operative finding encountered was ileal perforation (Figure 1) found in 23 (30.3%) of the patients followed by, in order of decreasing frequency, multiple small bowel perforation in 14 (18.4%), solitary stricture of the small bowel with perforation in 9 (11.8%), ileo-cecal mass in 9 (11.8%), adhesions or bands in 7 (9.2%) (Figure 2), single or multiple strictures in 5 (6.6%), stricture with impending small bowel perforation in 5 (6.6%) and jejunal perforation in 4 (5.3%) patients (Table 1).

Table 1: Intraoperative findings.

Intraoperative Finding	No. of patients	% cases
Ileal perforation	23	30.3%
Multiple small bowel perforations	14	18.4%
Solitary stricture with perforation	9	11.8%
Ileocecal mass	9	11.8%
Adhesion and bands	7	9.2%
Single or multiple strictures	5	6.6%
Stricture with impending perforation	5	6.6%
Jejunal perforation	4	5.3%

The frequently performed surgical procedures in order of decreasing frequency were ileostomy (32 patients), resection and anastomosis of the involved bowel (12 patients), primary repair of the perforation (10 patients), right hemicolectomy (8 patients), adhesiolysis (6 patients), stricturoplasty (4 patients) (done in case of single stricture, mostly), jejunostomy (3 patients) and peritoneal and omental biopsy in 1 patient respectively (Table 2).

Table 2: Operative procedures performed.

Operative procedure	No. of patients
Ileostomy	32
Resection and anastomosis	12
Primary repair of perforation	10
Right hemicolectomy	8
Adhesiolysis	6
Stricturoplasty	4
Jejunostomy	3
Peritoneal and omental biopsy	1

Amongst our study group patients, 41 developed post-operative complications in the form of surgical site infections in 24 patients, pulmonary complications in 10 patients, enterocutaneous fistula in 4 patients and primary repair or anastomotic breakdown leak in 3 patients respectively. Out of these only two succumbed to their morbidity. The patients with primary repair or anastomotic breakdown leakage of gastrointestinal contents were managed by re-exploration with exteriorization the affected small bowel and were later on followed up with closure of the stoma after 8-12 weeks postoperatively. This was done whilst the patients were on anti-tubercular drug regimen. Rest all the patients responded to the treatment.

Eleven patients in our study group expired in the immediate post-operative period and the cause of death were the sequelae to sepsis and septic shock, i.e. MODS.

DISCUSSION

The total number of patients in our study group was 76, with males and females being 46 (60%) and 36 (40%),

respectively. Charokar K reported 61% females and 39% females in their study group.¹³

The youngest and the oldest patient in our study group were 13 years old boy and a 73 years old lady, respectively. The mean age of the patients in our study was 28.9 years. Sadia J reported mean age in their study to be 35.9 years. This difference in mean ages in this study and hers is probably due to the larger sample size of 161 patients in her study as compared to our sample size of 76 patients.

Majority of study patients (70%) were in the undernourished category and 30% were in the normal weight category as per the WHO-BMI classification. This points to a strong association between malnourishment and tuberculosis. Tuberculosis affects primarily the malnourished and later on due to anorexia and mal-absorption leads to further malnourishment. Similar findings have been reported by other researchers like Charokar K, who reported 68% of his study group patients to be in underweight category and 32% in the normal weight category.¹³

Fourty three of our patients presented to our surgery emergency with features suggestive of peritonitis and thirty-three with acute intestinal obstruction. The most frequent complaint in history was pain (90%) followed by anorexia (80%), weight loss (73%), fever (64%) and altered bowel habits (52%). Sharma MP have reported similar findings in their research.¹⁰

Study found that ileal perforation was the commonest intra-operative finding followed in decreasing order of frequency by multiple small bowel perforations, small bowel strictures with perforation, ileo-cecal mass, adhesions or bands, single or multiple small bowel strictures, small bowel strictures with impending perforation, small bowel perforation and jejunal perforations. Charokar K and Sadia J have reported similar results in their research.^{13,14}

Ileostomy was the commonest surgical intervention performed in our study followed by resection anastomosis of the involved bowel segment, primary repair of the perforated viscus, right hemi-colectomy or limited ileocecal resection, adhesiolysis, stricturoplasty, jejunostomy and in a solitary case only omental and peritoneal biopsy with peritoneal lavage was done. Different authors and researchers, Charokar K, Sadia J and Ali N have suggested and reported a multitude of surgical procedures in the surgical management of abdominal tuberculosis but it has been rightly stated by Sabooni K, that given the diverse presentation and characteristics of abdominal tuberculosis, no definite surgical procedure can be regarded as the standard of care. Hence, we may say that the appropriate surgical procedure has to be decided by the operating surgeon based on the performance status and general condition of the patient at the time of

surgery, the site and extent of the disease and the expertise of the operating surgeon.

The high rate of morbidity (54%) and mortality (14.5%) in our study group may be explained due to the reason that our study group included only those patients suffering from abdominal tuberculosis who underwent a surgical operative procedure due to failure or non-responsiveness to conservative management, a majority of them were under-nourished, had sepsis at admission and were having fecal peritonitis at the time of surgery. Similar findings have been reported by Sadia J and Chalya PL.^{14,17}

CONCLUSION

Abdominal tuberculosis is a disease entity which is commonly encountered in the surgery emergency in our part of the world. Under-nourishment and malnutrition play a very important role in the disease progression and the outcome. No surgical procedure has been recommended as the standard of surgical care due to the wide spectrum of the disease. As abdominal tuberculosis is uncommon in the developed world, it has not attracted the amount of attention it deserves in the literature. We conducted our study to highlight the burden and graveness of abdominal tuberculosis in the developing world and hence we suggest that more studies, with larger patient numbers, be conducted on abdominal tuberculosis to have a standardized management protocol.

Funding: No funding sources

Conflict of interest: None declared

Ethical approval: The study was approved by the Institutional Ethics Committee

REFERENCES

1. Addison NV. Abdominal tuberculosis-a disease revived. Ann R Coll Surg Engl. 1983;65:105-11.
2. Marshall JB. Tuberculosis of the gastrointestinal tract and peritoneum. Am J Gastroenterol. 1993;88:989-99.
3. Aston NO. Abdominal tuberculosis. World J Surg. 1997;21:492-9.
4. Lonnroth K, Raviglioni M. Global epidemiology of tuberculosis: Prospects for control. Semin Respir Crit Care Med. 2008;29:481-4.
5. Mehmood N, Najam S, Yunus M. Analysis of presentation of cutaneous tuberculosis in surgical department. JIIMC. 2008;1(1):23-30.
6. Rao KVV, Rao KS. Surgical study of abdominal tuberculosis. IOSR-JDMS. 2016;15(6):32-5.
7. Skopin MS, Batyrov FA, Kornilova Z. The prevalence of abdominal tuberculosis and the specific features of its detection. Probl Tuberk Bolezn Legk. 2007;1:22-6.
8. Khan IA, Khattak IU, Asif S, Nasir M, Ziaur R. Abdominal tuberculosis an experience at Ayub Teaching Hospital Abbottabad. J Ayub Med Coll Abbottabad. 2008;20:115-8.
9. Baloch NA, Baloch MA, Baloch FA. A study of 86 cases of abdominal tuberculosis. J Surg Pak. 2008;13:30-2.
10. Sharma MP, Bhatia V. Abdominal tuberculosis. Indian J Med Res. 200;120:305-15.
11. Mohammed A. Clinical profile and surgical outcome of abdominal tuberculosis-a retrospective analysis. Int J Med Health Sci. 2013;2:402-6.
12. Gondal KM, Khan AFA. Changing pattern of abdominal tuberculosis. Pak J Surg. 1995;11:109-13.
13. Charokar K, Garg N, Jain AK. Surgical management of abdominal tuberculosis: a retrospective study from Central India. Int Surg J. 2016;3(1):23-31.
14. Jaskani S, Mehmood N, Khan NM. Surgical management of acute presentation and outcome of patients with complicated abdominal tuberculosis. J Rawalpindi Med Coll (JRMC). 2016;20(2):108-12.
15. Ali N, Hussein M, Israr M. Tuberculosis as a cause of small bowel obstruction in adults. Gomal J Med Sci. 2011;9:233-5.
16. Sabooni K, Khosravi MH, Pirmohammad H. Tuberculosis peritonitis with features of acute abdomen in HIV infection. Int J Mycobacteriol. 2015;02:04:151-3.
17. Chalya PL, Mchembe MD, Mshana SE. Clinicopathological profile and surgical treatment of abdominal tuberculosis: a single centre experience in north western Tanzania. BMC Infect Dis. 2013;13:270-3.

Cite this article as: Bali RS, Jain R, Zahoor Y, Mittal A. Abdominal tuberculosis: a surgical emergency. Int J Res Med Sci 2017;5:3847-50.