

Case Report

Osteofibrous dysplasia of the proximal tibia: an illustrative case report

Sastha K. Sharan*, J. K. Giriraj Harshavardahan, Ganesan Ganesan Ram,
Sundar Suriyakumar, Pagal Varthi Vijayaraghavan

Department of Orthopaedics, Sri Ramachandra Medical College and Research Institute, Chennai, Tamil Nadu, India

Received: 26 March 2015

Revised: 08 April 2015

Accepted: 07 May 2015

***Correspondence:**

Dr. Sastha K. Sharan,

E-mail: sastha_k_sharan@yahoo.co.in

Copyright: © the author(s), publisher and licensee Medip Academy. This is an open-access article distributed under the terms of the Creative Commons Attribution Non-Commercial License, which permits unrestricted non-commercial use, distribution, and reproduction in any medium, provided the original work is properly cited.

ABSTRACT

A 5 years old girl presented 3 years back with pain and swelling over the upper right leg for 2 years duration. X-ray, CT and MRI revealed osteolytic well defined lesion 2.5 × 2 cm in the meta-diaphyseal region of the proximal tibia with pathological fracture of anterolateral cortex. Child underwent thorough curettage of the lesion and the defect was filled with allograft (iliac crest graft) from mother which was harvested in an adjacent operation theatre. The limb was protected with a plaster splint for a period of 3 months. The graft gradually consolidated and new bone formation was apparent by 6 months. Remodelling of the medullary canal occurred at 1 year follow up. Child has been followed up to 3 years (till date) and there is no evidence of recurrence. The case illustrates that osteofibrous dysplasia can be effectively treated by curettage and replacement of defect by allograft from parents.

Keywords: Osteolytic, Osteofibrous dysplasia, Curettage

INTRODUCTION

Osteofibrous dysplasia is an unusual tumour like fibro osseous lesion, originally described by Frangenheim³ in 1921. The other terms describing this condition are - congenital fibrous dysplasia and ossifying fibroma of bone.² Though the lesion affects predominantly the proximal tibia, lesions in radius and ulna and fibula have been reported.⁴⁻⁷ Arvind Gupta has reported a lesion in proximal femur.⁴ There are two important differential diagnosis to this lesion, one is adamantinoma and the other fibrous dysplasia.¹ Osteofibrous dysplasia is more common in first decade of life. The treatment modalities available are conservative and surgical. Surgical options available are, curettage and bone grafting, and extra periosteal excision and managing the gap, so created. Curettage and bone grafting is associated with high rate of recurrence. We are presenting a case of osteofibrous dysplasia of proximal tibia in a 5 year old girl who was

successfully treated with curettage and bone grafting with a follow up of three years. There was no recurrence of the lesion.

First described by Frangenheim³ in 1921. Lee et al. had done a retrospective analysis of 16 patients from October 1992 - October 2002. This is the largest series of cases reported. Of these 16 cases, one was diagnosed as adamantinoma and two were OFD with coexistent adamantinoma on histological examination. Therefore the total number was only 13. This indicates that the condition is very rare. It is also clear therefore that a histological diagnosis is mandatory in all suspected cases of OFD. Five of these patients had curettage and bone grafting and on all there was recurrence. Recurrence rate was nil in extra periosteal excision, but there were other complications like non-union and decking site failure. They recommend that surgical treatment should be more radical to prevent recurrence. Fernando et al. had reported a case of OFD in a 45 year old woman. They had done

curettage and bone grafting and bone cementing with no recurrence after 1 year follow up.

CASE REPORT

Five year old female presented with pain and swelling over the upper right leg for 2 years. Patient had history of trivial fall eleven months back following which she was not to able weight bear and walk. Patient was treated then with a plaster of pop slab application by a local doctor. She again developed pain 5 months back for which plaster splintage was repeated. On local examination of right lower limb thickening of the bone over the metaphyseal-diaphyseal region proximal third of the tibia. X-ray showed eccentric lytic lesion in the proximal shaft of the tibia (Figure 1). MRI revealed well defined oval lesion with surrounding endosteal sclerosis 2.5 × 2 cm in the meta-diaphyseal region of the proximal tibia with pathological fracture involving the anterolateral cortex of the tibia suggestive of osteofibrous dysplasia or ossifying fibroma (Figure 2).

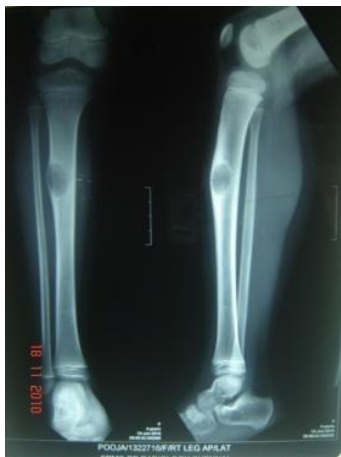

Figure 1: Preop X-ray showing osteolytic lesion in the metaphyseal diaphyseal junction of the proximal tibia.

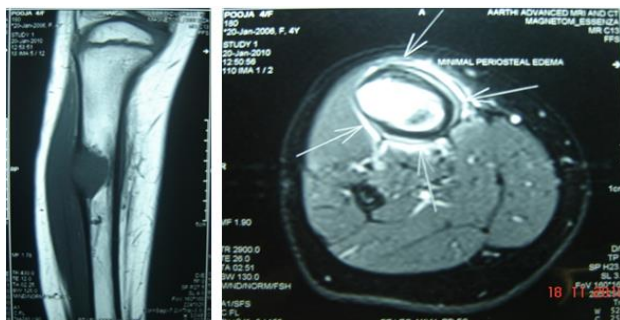

Figure 2: MRI showing a well-defined oval cortical lesion eccentrically located in the meta diaphyseal portion of the proximal tibia.

Patient underwent curettage and bone grafting of the lesion. 2 x 1 cm anterolateral cortical window was created at site of lesion (Figure 3a). Thorough curettage was done and the defect was filled with allograft (iliac

crest graft) from screened mother which was harvested in an adjacent operation theatre (Figure 3b). To confirm the diagnosis curetted material was sent for histological examination. On microscopy the section shows a portion of fibro-osseous lesion composed of spindle cell stroma interspersed by spicules of mineralised bone (Figure 4). The limb was protected with a plaster splint for a period of 3 months. The graft gradually consolidated and new bone formation was apparent by 6 months. Remodelling of the medullary canal occurred at 1 year follow up. Child has been followed up to 3 years (till date) and there is no evidence of recurrence (Figure 5). The case illustrates that osteofibrous dysplasia can be effectively treated by curettage and replacement of defect by allograft from parents.

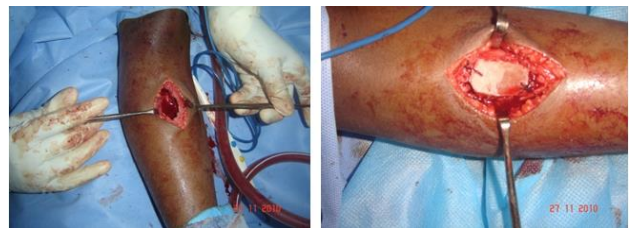

Figure 3: a) Intraoperative picture showing a large cortical window. b) The defect was filled with allograft.

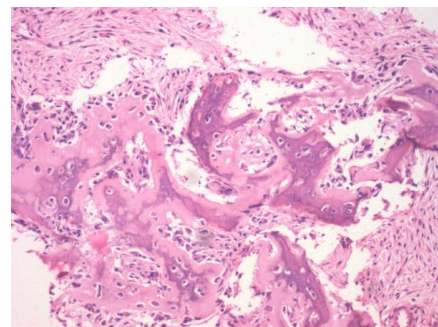


Figure 4: Histopathology showing fibrous lesion composed of spindle cell stroma interspersed by spicules of mineralised bone.

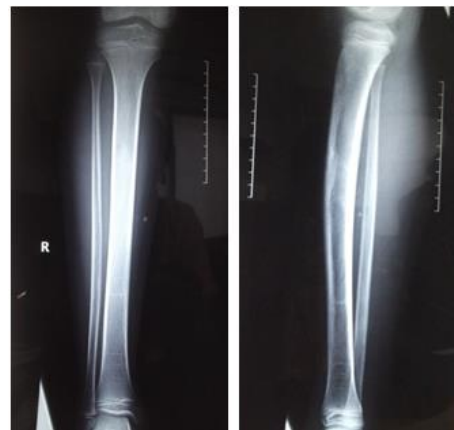

Figure 5: Postop x-ray at 3 years follow up.

DISCUSSION

In a study by Campanacci et al.² described that “osteofibrous dysplasia is histological similar to fibrous dysplasia. In a study by Kempson et al.⁵ described that the common site is the middle third of the diaphysis of the tibia, followed by the upper third and the distal third. Osteofibrous dysplasia is usually diagnosed in the first decade with high incidence of 1-5 years of age. Most of studies have reported that there is no sex preponderance. In a study by Park et al.⁸ reported that patient usually presents with pain, swelling and pathologic fracture. Our case presented with pain, swelling and pathological fracture of the proximal tibia. In a study by Komiya and Inoue et al.⁶ reported that duration of symptoms varied from 2 months to five years. Our patient presented to us with pain over the right leg for 11 months.

Radiologically it presents with an eccentric lytic lesion, surrounding margins with sclerosis, metaphyseal fibrous defect is usually present and bowing of tibia is seen if there is pathological fracture. Keeney et al.⁴ reported that the differentials of osteofibrous dysplasia has to be ruled out particularly in tibia to exclude other epithelioid tumors (fibrous dysplasia, non-ossifying fibroma, adamantinoma). On microscopy the section showed fragments of fibrous tissue with spicules of bone rimmed by active osteoblasts. Osteofibrous dysplasia should be confirmed histologically by biopsy for the correct diagnosis and appropriate treatment. Treatment options for osteofibrous dysplasia include either immobilization of the limb or surgical intervention. In skeletally immature patients treatment of choice is non-operative but surgical intervention is not contraindicated. Schoenecker et al.⁹ reported that recurrence rate in patients under fifteen years of age following curettage and bone grafting is repeated 69% to 100%. In our case as child had repeated pathological fractures and disability, we decided to surgically intervene in spite of the risk of recurrence.

CONCLUSION

The case illustrated that osteofibrous dysplasia in skeletally immature patients can be effectively treated by

curettage and replacement of defect by allograft from parents. With proper curettage through a large window, recurrence rates can be minimized.

Funding: No funding sources

Conflict of interest: None declared

Ethical approval: Not required

REFERENCES

1. Campanacci M, Laus M. Osteofibrous dysplasia of the tibia and fibula. *J Bone Joint Surg [Am]*. 1981;63-A:367-75.
2. Campanacci M. Osteofibrous dysplasia of long bones: a new clinical entity. *Ital J Orthop Traumatol*. 1976;2:221-37.
3. Frangenheim P. Angeborene ostitis fibrosa als Ursache einer intrauterinen Unterschenkelfraktur. *Arch Klin Chir*. 1921;117:22-9.
4. Keeney GL, Unni KK, Beabout JW, Pritchard DJ. Adamantinoma of long bones: a clinicopathologic study of 85 cases. *Cancer*. 1989;64:730-7.
5. Kempson RL. Ossifying fibroma of the long bones. A light and electron microscopic study. *Arch Pathol*. 1966;82:218-33.
6. Komiya S, Inoue A. Aggressive bone tumourous lesion in infancy: osteofibrous dysplasia of the tibia and fibula. *J Paediatr Orthop*. 1993;13:577-81.
7. Nakashima Y, Yamamuro T, Fujiwara Y, Kotoura Y, Mori E, Hamashima Y. Osteofibrous dysplasia (ossifying fibroma of long bones): a study of 12 cases. *Cancer*. 1983;52:909-14.
8. Park YK, Unni K, McLeod RA, Pritchard DJ. Osteofibrous dysplasia: clinicopathologic study of 80 cases. *Hum Pathol*. 1993;24:1339-47.
9. Schoenecker PL, Swanson K, Sheridan JJ. Ossifying fibroma of the tibia. *J Bone Joint Surg*. 1981;63-A:483-8.

DOI: 10.18203/2320-6012.ijrms20150179

Cite this article as: Sharan SK, Giriraj Harshavardhan JK, Ram GG, Suriyakumar S, Vijayaraghavan PV. Osteofibrous dysplasia of the proximal tibia: an illustrative case report. *Int J Res Med Sci* 2015;3:1518-20.