

Original Research Article

Outcome of clubfoot treatment in the pre-ponseti period in a Nigerian teaching hospital: a 14 year review

Olugboyega A. Oyewole*, Mosimabale J. Balogun, Richard A. Omoyeni, Samuel O. Ogunlade

Department of Orthopaedic and Trauma, University College Hospital, Ibadan, Nigeria

Received: 18 October 2019

Revised: 03 December 2019

Accepted: 10 December 2019

*Correspondence:

Dr. Olugboyega A. Oyewole,

E-mail: dokitagboe@gmail.com

Copyright: © the author(s), publisher and licensee Medip Academy. This is an open-access article distributed under the terms of the Creative Commons Attribution Non-Commercial License, which permits unrestricted non-commercial use, distribution, and reproduction in any medium, provided the original work is properly cited.

ABSTRACT

Background: Congenital Talipes Equinovarus (CTEV) is a common musculoskeletal congenital disorder. Historically, surgical treatment of various types was popular; however, currently the gold standard of treatment is non-operative care using the Ponseti method. This work evaluates the outcome of this former method of managing CTEV before author adopted the Ponseti Method and compares it with the reported outcomes of the Ponseti method in published literature.

Methods: A retrospective review of this data from January 1990 to December 2003 was done, the patients demographics, treatment given, duration and outcome of care were analysed using descriptive statistics. This finding was then compared with outcomes of Ponseti method in literature.

Results: Here, 145 patients had initial non operative care; eighteen of those patients (12.4%), eventually require either a posteromedial release, a combined posteromedial and posterolateral releases or a triple arthrodesis.

Conclusions: The study shows that the success rate of this method of manipulation preceding the adoption of the Ponseti method is 87.6%. This outcome is inferior when compared to the outcome of Ponseti method in published literature. Also, the extensive nature of eventual surgical intervention required to achieve correction is in contrast to the minimal surgeries needed achieve correction of residual deformities following the use of the Ponseti method.

Keywords: Congenital talipes equinovarus, Low income countries, Pre-Ponseti period, Ponseti method

INTRODUCTION

Congenital Talipes Equinovarus (CTEV) is a developmental disorder of the foot characterized by equinus at the ankle, varus at the heel, supination at the midfoot and adductus at the forefoot. It is a common disorder with reported incidence at 1-3/ 1000 births.¹ It is also the commonest congenital musculoskeletal disorder reported in Nigeria accounting for over fifty percent of all congenital musculoskeletal anomalies presenting to orthopedic clinics in the country.²⁻⁴

The causes are multifactorial.⁵ The aim of treatment of CTEV is to achieve a pain free plantigrade foot, that is

stable, has good mobility and aesthetically acceptable. Over the past two decades, the primary treatment of idiopathic CTEV has shifted from extensive surgical release to more conservative methods of correction.⁶

However, it has been said that there are as many techniques of manipulative treatment of CTEV as there are authors who wrote about the deformity.⁷

Ponseti developed his technique in the 1940s, and in 1995 a review of outcome of the technique after 35 years of follow up was done by Cooper and Dietz revealing good long-term outcome.⁸ A year later, Ponseti published a book describing his method.⁹

The Ponseti method has transformed the management of children with CTEV, producing good long-term results and in the last two decades has gained wide acceptance in the worldwide orthopaedic community has become the gold standard for the treatment of CTEV.⁵

The method has been particularly appealing to low income earning countries like Nigeria because it is simple and conservative. It is also economical when compared to the hitherto prevalent surgery-based care and it is effective, safe, quick and easy to learn.^{10,11}

The first Ponseti clubfoot management workshop in Nigeria was held in Ile-Ife in December 2009.^{11,12} One of the aims of the workshop is to build the capacity of local medical personnel on the use of Ponseti's method. The method had subsequently been adopted by many orthopedic units in Nigeria including this own hospital, and some have reported favorable early results.¹² Author have also noticed a sharp decline in clubfoot surgeries in this practice since author adopted the Ponseti method.

Adewole et al, reported that in the pre-Ponseti era, the manipulation techniques used by most orthopedic surgeons in Nigeria were based on the works of Hiram Kite but with different casting protocols in terms of types of cast used and interval of cast change, there were also variation in manipulation techniques varying from those who corrected the deformities one at a time and those who attempt to correct all at once. However, they alluded to the fact that the outcomes of those various methods used previously in Nigeria are unknown.¹²

Before the adoption of the use of Ponseti method in this unit, manipulation based on Kite's method was used, above knee casts were used and the casts were changed fortnightly for three months and later changed monthly for up to another 6 months if necessary. When acceptable correction is achieved (plantigrade feet) the patients were referred to the physiotherapist for regular foot joint mobilization exercises and splintage for 2-3 years. Those with inadequate correction had surgery, and patients who presented above the age of 9 months are usually offered straightforward surgery if the deformity is marked or a short period of manipulation followed by surgery if their deformity is not marked. All operated patients had post-operative physiotherapy and splintage to their feet.

The aim of this work to evaluate the outcome of this previous method of managing CTEV while comparing it with the reported outcomes of the Ponseti method in published literature.

METHODS

Inclusion criteria

- All the patients who were managed for CTEV in this centre over the study period and whose case note could be retrieved were recruited.

Exclusion criteria

- All the patients whose case note could not be retrieved were excluded.

Study period and study methodology

The case notes of patients with CTEV treated in this unit over the study period of January 1990 to December 2003 were retrieved and analysed retrospectively. The diagnosis of CTEV was based on the presence of a record of deformity incorporating equinus at the ankle, varus at the heel, supination at the midfoot and adductus at the forefoot. All diagnosis was made by any of the three orthopedic consultant staff in the unit over the study period. Data was extracted from the case notes using a proforma designed by the researchers to retrieve the patients' biodata, pregnancy history, fetal lie at delivery, birth order, affected foot, and presence of other congenital anomaly in the patient and in the family was extracted. Also, the type of treatment given, duration and outcome of conservative care, age at which surgery was done, type and numbers of surgical procedure done as well as the outcome of surgery were extracted as well as the duration of follow up.

Statistical analysis

Results were analysed with SPSS 17 using descriptive statistics.

RESULTS

The total number of retrieved cases was 181. There were 110 males and 71 females in a ratio of 1.5: 1, and the age at presentation ranges from 1 to 336 weeks with a median of 12 weeks.

Sixty eight percent of this patients are either the first or second child of their mother (Figure 1), eight patients were products of multiple births (7 twin and 1 triplet).

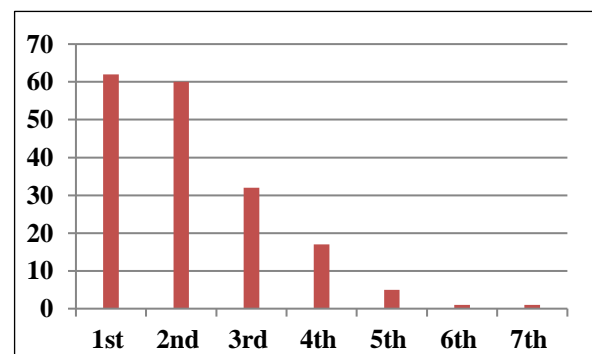


Figure 1: Birth order of patients.

Ninety patients (50.8%) had bilateral deformities, while amongst those with unilateral deformities there were more deformities of the right foot compared to the left (Figure 2).

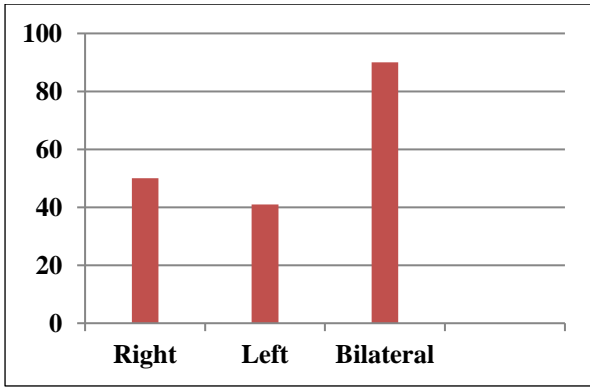


Figure 2: Foot involved.

Twenty-four patients (13.3%) had other associated congenital anomalies (Figure 3). Eleven spinal defects, six upper limb abnormalities (polydactyly, syndactyly, webbed fingers, clamptodactyly and amniotic bands), five lower limb abnormalities (proximal focal femoral deficiency, fibula hemimelia, tibial pseudoarthrosis, and arthrogyphosis), there was one patient each with Down’s syndrome and neurofibroma; however only 1.7% had a family history of any congenital anomaly (Figure 4).

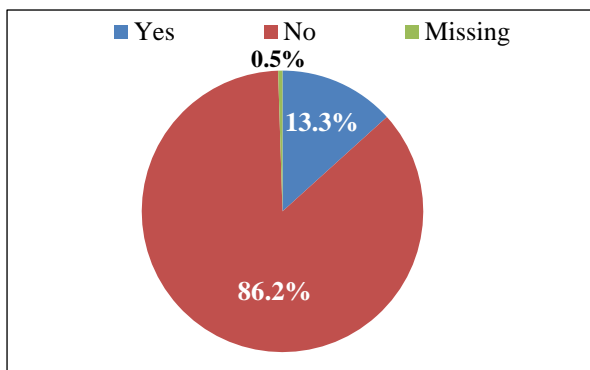


Figure 3: Other deformities.

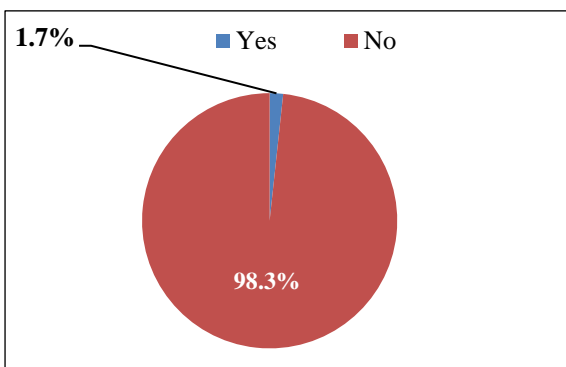


Figure 4: History of congenital anomaly in family.

Majority of this patients are products of normal intrauterine pregnancy out of which five patients had preterm deliveries, however two patients were products of extrauterine pregnancy (one tubal pregnancy and one abdominal pregnancy (Figure 5).

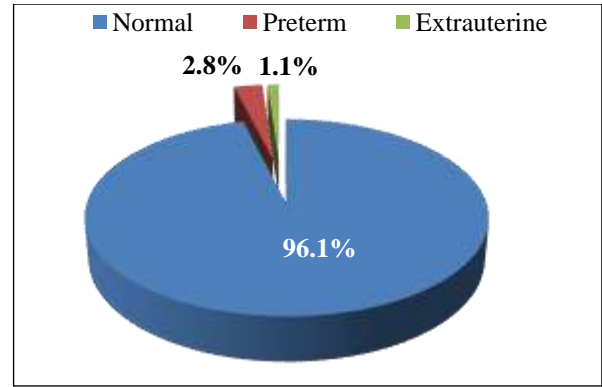


Figure 5: Pregnancy history.

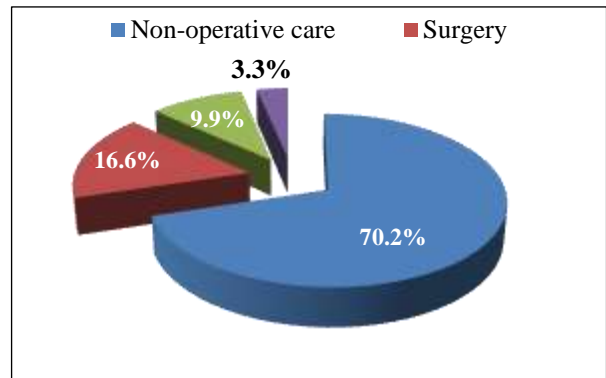


Figure 6: Treatment option.

Among 145 patients (80.1%) had initial non operative care; eighteen of those patients eventually proceed to have surgical care because of poor outcome (16 Posteromedial release, one posteromedial and posterolateral release and one posteromedial release with triple arthrodesis).

Among 16.6% of this patient had surgical treatment without an initial period of conservative care. The mode of treatment in six patients (3.3%) was missing from the records (Figure 6).

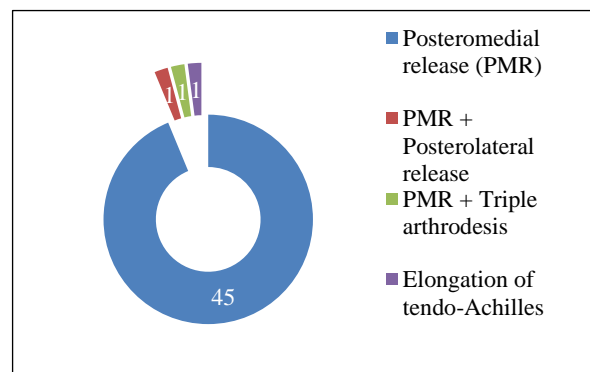


Figure 7: Type of surgery.

The median age at surgery for our patients was 72 weeks (range 36-336 weeks). Majority (93.8%) had a single

surgical procedure, while 6.2% of them had two surgeries. Posteromedial release was the most performed surgery in the study (Figure 7). The outcome following surgery was adjudged to be good in 97.8% of patients and fair in 2.2%. The mean follow up period was 13.8 months (range 3-36 months).

DISCUSSION

In this study, 145 patients had initial non operative care; eighteen of those patients (12.4%), eventually require surgery thus suggesting that the success rate of this method of manipulation preceding the adoption of the Ponseti method is 87.6%.

Adewole et al, in Lagos, Nigeria reported that only six of the 158 feet they treated with the Ponseti method required surgery hence having a success rate of 96.2%.¹² Furthermore, their surgeries were minimal (3 elongation of tendo-Achilles (ETA) and 3 ETA+posterior capsulotomy) when compared to the extensive surgeries required in this own patients who had at least a posteromedial release following the period of manipulation.

Herzenberg et al, used the need to perform Posteromedial Release (PMR) within the first year as the parameter to judge success between the Ponseti method and traditional method of CTEV management.¹³ In their study only one of thirty four feet required PMR compared to 31 out of 34 in the non-Ponseti group showing a 97% success rate with the Ponseti method also Pavone et al, reported 94% success in the 207 feet they treated using the Ponseti method after a mean follow up of 69 months.¹⁴

All these studies corroborate the work of Morcuende and Ponseti in which they reported a 98% success rate and significant reduction in the need for extensive corrective surgeries.¹⁵

The results of Smythe et al, in Zimbabwe who reported 85% success rate with the Ponseti method (using Pirani score of 1 or less as their parameter) is however similar to this own pre- Ponseti outcome, this may however reflect the effect of a learning curve while using a new method as the Ponseti method was introduced to Zimbabwe in 2011 and they recruited only patients managed between 2011 and 2013 into their study.¹⁶⁻¹⁷

Limitations of the study was being a retrospective study; some data were not consistently recorded in the case notes, hence the number of casts, duration of conservative care, objective assessment of severity of deformity and outcome of treatment - recorded in this study as achievement of a plantigrade foot, could not be analysed. Also 22 of our 24 patients with other congenital anomaly had initial non operative care and they were analysed with the idiopathic clubfeet, however two of them proceeded to have surgery while the others had good to fair outcomes following manipulation and casting. Importantly, author analysed based on the 181 patients

managed and not on the number of feet treated (265 feet) as the proforma did not differentiate whether patients with bilateral deformities eventually had surgery on one or both feet.

CONCLUSION

This study aim to provide information on the outcome of clubfoot management in this practice before the adoption of Ponseti method, and author are able to show that these outcome was inferior in terms of achieving a plantigrade foot when compared to the outcome of Ponseti technique in published literature and author are also able to show the extensive nature of eventual surgical intervention required to achieve correction which is in contrast to the minimal surgeries needed achieve correction of residual deformities following the use of the Ponseti technique. Author hope to review this outcome since the adoption of Ponseti method in the future.

Funding: No funding sources

Conflict of interest: None declared

Ethical approval: Not required

REFERENCES

1. Boakye H, Nsiah A, Thomas A, Bello AI. Treatment outcome of Ponseti method in the Management of Club Foot at Komfo Anokye teaching hospital, Ghana: a retrospective study. *Archives Curr Res Intern.* 2016;18:1-8.
2. Omololu B, Ogunlade SO, Alonge TO. Pattern of congenital orthopaedic malformations in an African teaching hospital. *West African J Med.* 2005;24(2):92-5.
3. Orimolade EA, Ikem IC, Akinyoola AL, Adegbehingbe OO, Oginni LM, Esan O. Pattern of Congenital Musculoskeletal Abnormalities in South West, Nigeria: A Hospital Based Study. *Niger J Orthopaed Trauma.* 2013;12(1):52-5.
4. Adewole OA, Giwa SO, Kayode MO, Shoga MO, Balogun RA. Congenital club foot in a teaching hospital in Lagos, Nigeria. *African J Med Med Sci.* 2009;38(2):203-6.
5. Macnicol MF. The management of club foot: issues for debate. *The J bone joint surg. Brit Volume.* 2003;85(2):167-70.
6. Halanski MA, Davison JE, Huang JC, Walker CG, Walsh SJ, Crawford HA. Ponseti method compared with surgical treatment of clubfoot: a prospective comparison. *JBJS.* 2010;92(2):270-8.
7. Cummings RJ, Davidson RS, Armstrong PF, Lehman WB. Congenital clubfoot. *JBJS.* 2002;84(2):290.
8. Cooper DM, Dietz FR. Treatment of idiopathic clubfoot. A thirty-year follow-up note. *The Journal of bone and joint surgery. Am Vol.* 1995;77(10):1477-89.
9. Ponseti IV. Idiopathic congenital talipes equinovarus. In: Ponseti IV, eds. *Congenital Clubfoot*

- Fundamentals of Treatment. 1st ed. New York: Oxford University Press Inc. 1996:448-454.
10. Kumar R. Management of idiopathic clubfoot by Ponseti's method: a comparative clinical study on toddlers with radiological correlation. *Int J Res Orthop.* 2016;2(2):52.
 11. Akintayo OA, Adegbehingbe O, Cook T, Morcuende JA. Initial program evaluation of the Ponseti method in Nigeria. *Iowa Orthop J.* 2012;32:141.
 12. Adewole OA, Williams OM, Kayode MO, Shoga MO, Giwa SO. Early experience with Ponseti Club foot management in Lagos, Nigeria. *East Central African J Surg.* 2014;19(2):72-7.
 13. Herzenberg JE, Radler C, Bor N. Ponseti versus traditional methods of casting for idiopathic clubfoot. *J Pediatr Orthop.* 2002;22(4):517-21.
 14. Pavone V, Testa G, Alberghina F, Lucenti L, Sessa G. Effectiveness of Ponseti method for the treatment of congenital talipes equinovarus: personal experience. *Pediat Therapeut.* 2015;5(3):1-4.
 15. Morcuende JA, Dolan LA, Dietz FR, Ponseti IV. Radical reduction in the rate of extensive corrective surgery for clubfoot using the Ponseti method. *Pediatr.* 2004;113(2):376-80.
 16. Smythe T, Chandramohan D, Bruce J, Kuper H, Lavy C, Foster A. Results of clubfoot treatment after manipulation and casting using the Ponseti method: experience in Harare, Zimbabwe. *Trop Med Int Health.* 2016;21(10):1311-8.
 17. Munambah N, Chiwaridzo M, Mapingure T. A cross-sectional study investigating impressions and opinions of medical rehabilitation professionals on the effectiveness of the Ponseti method for treatment of clubfoot in Harare, Zimbabwe. *Archiv Physioth.* 2016;6(1):7.

Cite this article as: Oyewole OA, Balogun MJ, Omoyeni RA, Ogunlade SO. Outcome of clubfoot treatment in the pre-ponseti period in a Nigerian teaching hospital: a 14 year review. *Int J Res Med Sci* 2020;8:401-5.