

## Case Report

# Ossifying fibroma in an adolescent boy and his mother: a case report

Jaseela T. K.\*, Priya P. V., Sankar Sundaram

Department of Pathology, Government Medical College Kottayam, Kerala, India

**Received:** 14 June 2021

**Accepted:** 09 July 2021

**\*Correspondence:**

Dr. Jaseela TK,

E-mail: [drjaseelatk@gmail.com](mailto:drjaseelatk@gmail.com)

**Copyright:** © the author(s), publisher and licensee Medip Academy. This is an open-access article distributed under the terms of the Creative Commons Attribution Non-Commercial License, which permits unrestricted non-commercial use, distribution, and reproduction in any medium, provided the original work is properly cited.

### ABSTRACT

Cemento-ossifying fibroma is a rare benign neoplasm occurring in the tooth bearing areas of mandible and maxilla. Here we report a case of an adolescent boy who presented with swelling in the right side of mandible. It was excised surgically and histopathological diagnosis of cement-ossifying fibroma was made. His mother also had history of cemento-ossifying fibroma 10 years back. This case is being reported for its rare incidence and familial occurrence.

**Keywords:** cemento-ossifying fibromas, Mandible swelling, Familial

## INTRODUCTION

cemento-ossifying fibromas is a benign fibro-osseous tumour composed of well demarcated proliferation of cellular fibrous tissue with varying quantities of osseous products including bone, cementum or a mixture of both.<sup>1</sup> Because of the bone and cementum like products, these lesions have been named as ossifying fibroma, central ossifying fibroma and cementifying fibroma. All these terms describe the same lesion.<sup>2</sup> It generally occurs between second and fourth decade. There is a definite female predilection with a male:female ratio of 1:5.<sup>3</sup> The most frequent location is mandible and less commonly in maxilla.<sup>4</sup> Pathogenesis of this remain unknown but trauma induced stimulation has been hypothesised by some authors as an underlying mechanism.<sup>5</sup> The cell of origin is believed to be multipotent mesenchymal cells of the periodontal ligament which has the ability to form bone, fibrous tissue and cementum.<sup>4</sup>

This paper describes a rare case of familial cemento-ossifying fibroma of the mandible in 17 years old boy with a history of similar swelling for his mother.

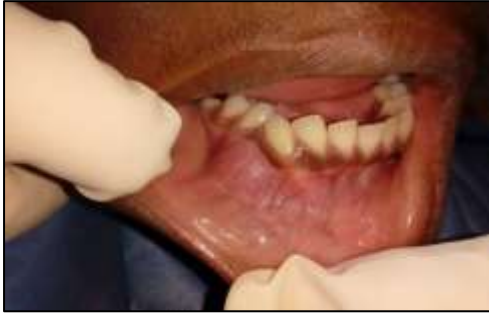## CASE REPORT

A 17 year old boy presented with a history of swelling in the right lower chin and tooth displacement in that region since 2 months. He had no history of pain or fever. His mother gave a history of similar swelling in her lower jaw 10 years back. It was diagnosed as cemento-ossifying fibroma after surgical excision and histopathological examination. On extraoral examination of the boy there was a swelling in the right side of lower face with facial asymmetry. No change in colour of skin overlying the swelling was noted. On palpation the swelling was firm in consistency. Intra oral examination revealed a well defined hard swelling of size 3x3 cm. Surface of the swelling was smooth with normal overlying mucosa. Obliteration of buccal vestibule was present. Patients serum calcium level was normal. He had no history of any swelling in the neck or elsewhere.

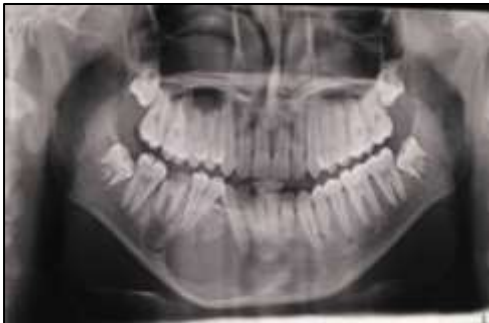In OPG a well demarcated mixed radiopaque and radiolucent lesion was noted in the body of right mandible. The lesion was seen extending from 32 to 45 region with teeth displacement in relation to 31, 41, 42, 43, 44, 45 and thinning of inferior border of mandible also was noted.

Excision of the mass was done under general anaesthesia and it was easily separated from the bony bed.

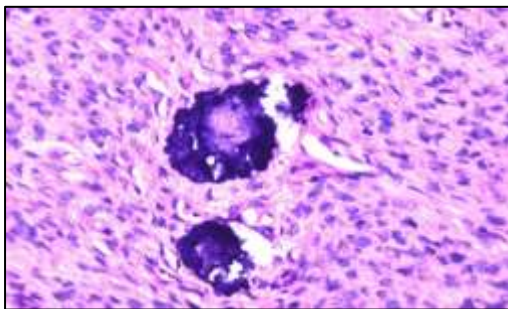
Gross examination of the specimen showed multiple tissue fragments together measuring 5x4.5x1.5 cm. Cut section was light brown with whitish specks. Extracted tooth also was present along with this.



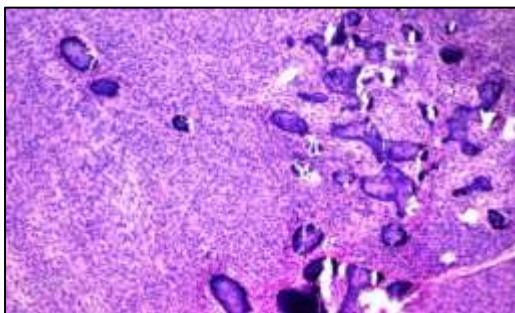
**Figure 1: Swelling right mandible.**



**Figure 2: Orthopantomogram.**



**Figure 3: H and E (400X).**



**Figure 4: H and E (100X).**

Microscopy showed a neoplasm composed of spindle cells arranged haphazardly with interspersed osteoid and cementum like material. No atypia or mitosis was noted. A diagnosis of cementoossifying fibroma was made by correlating clinical and radiological findings with histopathology.

Genetic analysis could not be performed. On follow up after 6 months patient showed no clinical or radiological evidence of recurrence. His mother also never had recurrence.

## DISCUSSION

Cemento-ossifying fibroma was first described by Menzel in 1872 according to Sciubba et al.<sup>6</sup> Since then lack of standardized terminology and classification of cemento-osseous lesions of the jaws have always posed a dilemma for the clinicians as well as histopathologists. Various terms have been used to describe these neoplasms. When bone predominates it is called ossifying fibroma. The term cementifying fibroma is assigned when curved or linear trabeculae or psammoma like calcifications are encountered. When both cementum and bone are observed it is referred to as cemento-ossifying fibroma. In earlier days COF and ossifying fibromas were classified separately because the former was considered to be of odontogenic origin and latter to be osteogenic.<sup>4</sup> But now it is agreed that both types fall under the same classification as osteogenic neoplasms and in current WHO classification of Head and neck tumours (4th edition) it comes under fibroosseous and osteochondromatous lesion of maxillofacial bones.<sup>7</sup>

COF of bone usually manifest in second to fourth decade of life with a female predilection. In our case patient was 17 year old male. Most frequent clinical feature is bone swelling or expansion at the buccal or lingual cortical plates. They are slow growing tumours and are generally asymptomatic until patient notices a deformity or swelling. Because of their slow growth they have an intact cortical plates of bone, overlying mucosa and skin.<sup>4</sup> Root divergence, displacement of teeth or tooth resorption may be associated with the tumour. Our patient had teeth displacement. Ossifying fibromas are usually solitary, but bilateral and multiple familial ossifying fibromas have been described.<sup>1</sup> In the present case patient's mother had history of ossifying fibroma 10 years back and was surgically excised. His grandmother also had a similar swelling, but she never consulted medical professionals. So this is a familial case of ossifying fibroma affecting two generations. Familial ossifying fibromas are very rare and only a few cases are reported in the literature.<sup>8</sup>

Radiographically they have well circumscribed sharply defined border. And it can have different appearances depending on the duration of the lesion. If early they are typically radiolucent then it becomes progressively radiopaque as the stroma mineralizes and becomes mixed

radiopaque and radiolucent lesion. Eventually it may become sclerotic or radiopaque lesion.<sup>9</sup> OPG of our patient revealed a well-defined mixed radiopaque radiolucent lesion extending from 32 to 45 region with teeth displacement in relation to 31,41,42,43,44,45 and thinning of inferior border of mandible. Another well-defined radiolucency in relation to decayed 46.

During surgical excision the lesion was easily separated from its bony bed. Some ossifying fibromas show a fibrous capsule around the tumour and are well demarcated from the surrounding bone. This would have permitted its easy separation during surgery. Microscopically COF consist of cellular fibrous stroma which shows variable admixture of osteoid, bone (which can be both woven and or lamellar) and cementum like spherules. Peripheral osteoblastic rimming will be present. The cementum like spherules demonstrates brush borders that blend into the surrounding stroma.<sup>10</sup> In ossifying fibroma the hard tissue of the tumour usually does not fuse with the surrounding bone.<sup>4</sup> the classical histology was seen in this case (Figure 3, 4).

Our case was a familial ossifying fibroma with the disease affecting two generations and possibly three. Patient and his mother had no features of hyperparathyroidism jaw tumour syndrome (HPT-JT). The main differential diagnosis of ossifying fibroma is fibrous dysplasia. It is very challenging and correlation of clinical, radiographical and microscopic features are very important. Both can exhibit similar features. Well circumscribed radiographical picture of COF and its easy separation from bony bed is an important distinguishing feature. Histologically fibrous dysplasia commonly displays fusion of the lesional metaplastic bone to the bordering cortical bone.<sup>11</sup> Earlier it was presumed that fibrous dysplasia contain only woven bone without any evidence of osteoblastic rimming of the bone whereas ossifying fibroma have more mature lamellar bone. But now these criteria are considered unreliable since both types of bone and cellular features may be encountered in either lesion. Other differentials to be considered are osteoblastoma, and focal cement-osseous dysplasia. Osteoblastoma occurs in slightly younger age group and they will complain of pain. Histology shows osseous trabeculae rimmed by abundant plump osteoblast and loosely fibrovascular stroma having dilated channels and focal hemorrhagic areas. Cementoosseous dysplasia may appear radiologically similar and biopsy is required to distinguish from ossifying fibroma.<sup>4</sup>

Initial treatment of COF include surgical curettage or enucleations. Prognosis is good and chance of recurrence are rare. But some studies have reported a recurrence rate of 28% following surgical curettage.<sup>9</sup> Our patient showed no clinical or radiological evidence of recurrence after 6 months following surgery. His mother also has no recurrence.

## CONCLUSION

Cemento-ossifying fibroma is a rare benign fibro-osseous neoplasm. A boy presented with swelling in the right side of mandible which was excised surgically and histopathological diagnosis of cemento-ossifying fibroma was made. His mother also had same neoplasm which was excised 10 years back. This case is being reported because of its rarity and diagnostic difficulty. Only few cases of familial cemento-ossifying fibromas have been reported in the literature.

*Funding: No funding sources*

*Conflict of interest: None declared*

*Ethical approval: Not required*

## REFERENCES

1. Emin M C, Peruze C, Saadettin K, Alper A, Omer G. Familial ossifying fibromas: Report of two cases. *J Oral Science.* 2004;46:61-4.
2. Chia-Chuan C, Hsei-Yen H, Julia YC, Chuan-Hang Y, Yi Ping W, Bu-Yuvan L, et al. Central Ossifying Fibroma: A clinicopathological study of 28 cases. *J Formos Med Assoc* 2008;107:288-94.
3. Antunes T, Bouca A, Carracha C, Costa A, Oliveira H, Silva L, et al. Giant cement-ossifying fibroma of the mandible-report on a clinical case. *International Journal of Oral & Maxillofacial Surgery.* 2019;48:224.
4. Khan SA, Sharma NK, Raj V, Sethi T. Ossifying fibroma of maxilla in male child: Report of a case and review of the literature. *Natl J Maxillofac Surg.* 2011;2:73-9.
5. Wenig BL, Sciubba JJ, Goldstein MN, Cohen A, Abramson AL. A destructive maxillary cement0-ossifying fibroma following maxillofacial trauma. *Laryngoscope.* 1984;94:810-5.
6. Sciubba JJ, Younai F. Ossifying fibroma of the mandible and maxilla: Review of 18 cases. *J Oral Pathol Med.* 1989;18:315-21.
7. El-Mofty SK, Nelson B, Toyosawa S. Ossifying fibroma. In :El-Naggar A.K, Chan J.K.C, Grandis J.R, Takata T, Slootweg P.J.(Eds):WHO classification of head and neck tumours (4th edition).IARC Lyon. 2017;251-2.
8. Yih WY, Pederson GT, Bartley MH Jr. Multiple familial ossifying fibromas:relationship to other osseous lesions of the jaws. *Oral Surg Oral Med Oral Pathol.* 1989;68:754-8.
9. Eversole R, Su L, ElMofty S. Benign fibro-osseous lesions of the craniofacial complex. A review. *Head and neck pathol.* 2008;2:177-202.
10. Neville BW, Damm DD, Allen CM, Bouquot JE. *Oral and Maxillofacial Pathology.* 3rd ed. India. Elsevier Publishers. 2009;648.
11. Riechert PA, Philipensen HP. Ossifying fibroma. Odontogenic tumour and allied lesions. Surrey: Quintessence. 2004;273-80.

12. Wang T, Zhang R, Wang L, Chen Y, Dong Q, Li T. Two cases of multiple ossifying fibromas in the jaws. *Diagn Pathol.* 2014;9:75.
13. Toyosawa S, Yuki M, Kishino M, Ogawa Y, Ueda T, Murakami S, et al. Ossifying fibroma vs fibrous

dysplasia of the jaw: molecular and immunological characterization. *Mod Pathol.* 2007;20:389-96.

**Cite this article as:** Jaseela TK, Priya PV, Sundaram S. Ossifying fibroma in an adolescent boy and his mother: a case report. *Int J Res Med Sci* 2021;9:2478-81.