

Original Research Article

Impact of 18F-FDG PET/CT on the staging of patients with non-small cell lung cancer

Ngo Minh Xuan¹, Huynh Quang Huy^{2*}

¹Department of Pediatric, Pham Ngoc Thach University of Medicine, Ho Chi Minh city, Vietnam

²Department of Radiology, Pham Ngoc Thach University of Medicine, Ho Chi Minh city, Vietnam

Received: 25 March 2020

Accepted: 28 April 2020

*Correspondence:

Dr. Huynh Quang Huy,

E-mail: huyhq@pnt.edu.vn

Copyright: © the author(s), publisher and licensee Medip Academy. This is an open-access article distributed under the terms of the Creative Commons Attribution Non-Commercial License, which permits unrestricted non-commercial use, distribution, and reproduction in any medium, provided the original work is properly cited.

ABSTRACT

Background: Non-small cell lung cancer (NSCLC) accounts for approximately 80% of new diagnoses of pulmonary carcinoma. This study investigated the correlation between 18 F-fluorodeoxyglucose uptake in computerized tomography integrated positron emission tomography and tumor size, lymph node metastasis, and distant metastasis in patients with NSCLC.

Methods: The records of 318 NSCLC patients (220 male, 98 females; mean age 60.94 years) were evaluated retrospectively.

Results: 278 cases were adenocarcinomas; 28 squamous cell carcinomas; and 12 large cell carcinoma. When the cases were categorized according to tumor size (group 1, ≤ 3 cm; group 2, >3 and ≤ 5 cm; group 3, >5 cm), the maximum standardized uptake value (SUVmax) was significantly lower in groups 1 and 2 compared with group 3 ($p < 0.001$ for each). Considering all cases, tumor SUVmax was not correlated with age, gender or histopathological type. Lymph node metastases were seen in 250 cases: 80.2% of these were adenocarcinomas, 71.4% squamous cell carcinomas, and 58.3% large cell carcinomas. Neither lymph node involvement nor distant metastases were correlated with tumor SUVmax, although lymph node size was positively correlated with lymph node SUVmax ($r = 0.758$; $p < 0.001$).

Conclusions: SUVmax was significantly associated with tumor size, but not with distant metastases or lymph node involvement. Therefore, SUVmax on positron emission tomography is not predictive of the presence of metastases.

Keywords: Computed tomography, Non-small cell lung cancer, Positron emission tomography, Standardized uptake value

INTRODUCTION

Pulmonary carcinoma is the most commonly diagnosed cancer worldwide (1.61 million cases, 12.7% of total carcinomas) and is the most common cause of cancer death (1.38 million deaths, 18.2% of total cancer deaths). Non-small cell lung cancer (NSCLC) accounts for approximately 80% of new pulmonary carcinoma diagnoses and includes the histological subtypes adenocarcinoma, squamous cell carcinoma, large cell undifferentiated carcinoma, and mixed histologies.¹

Recently, the uptake of 18 F-fluorodeoxyglucose (FDG) as determined by computerized tomography integrated positron emission tomography (PET-CT) has become a widely used non-invasive diagnostic test. Fluorodeoxyglucose PET-CT measures the standardized uptake value (SUV) of a pulmonary mass, which quantifies the glucose avidity of the tumor. Fluorodeoxyglucose PET-CT has been shown to be useful for evaluating an indeterminate pulmonary nodule, staging lymph nodes, and evaluating local nodal and distant metastases. Fluorodeoxyglucose uptake correlates

with the proliferative activity of tumor and is an independent prognostic factor in patients with lung cancer.²

The objective of the present study is to assess whether the maximum SUV (SUVmax) in PET-CT correlates with tumor size, lymph node metastasis, distant metastasis, and tumor histopathological type in patients with NSCLC.

METHODS

The records of 318 patients newly diagnosed with NSCLC between November 2015 and October 2018 were evaluated retrospectively. The subjects were examined by Fluorodeoxyglucose PET-CT and histological diagnosis of masses. A total of 220 males and 98 females were included in the study, with a mean age 60.9±9.1 years (range 28-88 years). Pathologically, there were 278 adenocarcinomas (ACC), 28 squamous cell carcinomas (SCC), and 12 large cell carcinomas (LCC).

All patients underwent a PET/CT scan before treatment with the primary lesion greater than 1 cm were included in this study under the approval of the Ethics Committee Board of Bach Mai hospital. Authors excluded the patients who histology could not be confirmed or was confirmed as other than NSCLC, previous history or concurrent diagnosis of another type of cancer.

PET/CT imaging technique

All the patients underwent imaging in a mobile van with a PET/CT scanner (Discovery, GE Healthcare) (no breath-hold; section thickness, 5 mm; pitch, 1.5; 30 mAs; 130 kVp). Acquisition extended from skull base to mid-thigh. The images were reconstructed with a 512×512 matrix and 700-mm² field of view. For fusion with the PET data, images also were reconstructed with a 128×128 matrix. The PET/CT data were reviewed and postprocessed at a PET/CT workstation (MIM, MIMvista).

All patients were asked to avoid strenuous exercise for 24 hours before PET/CT. Nondiabetic patients fasted for 6 hours before imaging. Medications were taken as usual. Patients with non-insulin-dependent diabetes were asked to fast and not take their medication for 6 hours before imaging.

Patients with insulin-dependent diabetes underwent imaging at midday. They were instructed to eat a light breakfast, take their insulin as usual, and fast for the next 4 hours.

All patients underwent blood glucose measurements before injection, and those with a blood glucose concentration less than 10 mmol/L received the FDG injection and underwent scanning. All patients rested for

1 hour in a quiet environment for a 1-hour uptake period after injection and before scanning.

Statistical analysis

Statistical analysis was performed using SPSS software (version 12.0). Values were expressed as means±standard deviation. Statistical significance was assessed at the p <0.05 level. One-way analysis of variance was performed to compare SUVmax among the histological types. Spearman’s correlations were computed between tumor SUVmax and tumor diameter, mediastinal lymph node diameter, and lymph node SUVmax. Independent samples t-test was used to determine the significance of the difference in tumor SUVmax according to the presence of lymph node or distant metastases.

RESULTS

Between November 2015 and October 2018, 318 patients were diagnosed with NSCLC in this hospital, and FDG-PET/CT was performed in all patients. Patient characteristics are summarized in Table 1. The vast majority were men and the predominant histology was adenocarcinoma.

Table 1: Characteristics and SUVmax of the NSCLC cases.

	n (%)	SUV (mean±SD)
Sex		
Male	220 (69.2%)	11.36±5.83
Female	98 (30.8%)	10.02±4.25
Histology		
Adenocarcinoma	278 (87.4%)	10.75±5.30
Squamous cell carcinoma	28 (8.8%)	12.367±6.81
Large cell carcinomas	12 (3.8%)	12.17±4.22
Tumor size		
≤3 cm	88 (22.7%)	7.31±2.97
>3≤5 cm	114 (35.8%)	10.62±4.19
>5 cm	116 (36.5%)	14.03±6.11
Lymph node metastases		
N0	68 (21.4%)	9.81±5.72
N1	18 (5.7%)	9.04±3.98
N2	130 (40.9%)	11.48±5.34
N3	102 (32.1%)	11.36±5.42
Distant metastasis		
M0	144 (45.3%)	10.83±5.15
M1	28 (8.8%)	11.53±6.22
M2	61 (19.2%)	10.83±6.05
M3	85 (26.7%)	11.04±5.20

A significant relationship was found between tumor SUVmax and tumor size (r=0.541; p<0.001). When the cases were divided into three groups based on tumor size (group 1, ≤3 cm; group 2, >3 cm and≤5 cm; and group 3,

>5 cm), tumor SUVmax was differ significantly between groups 1, 2 and 3 ($p<0,001$). Considering all cases, tumor SUVmax was not significantly correlated with age, gender or histological type (adenocarcinoma, squamous cell carcinoma, and large cell carcinomas).

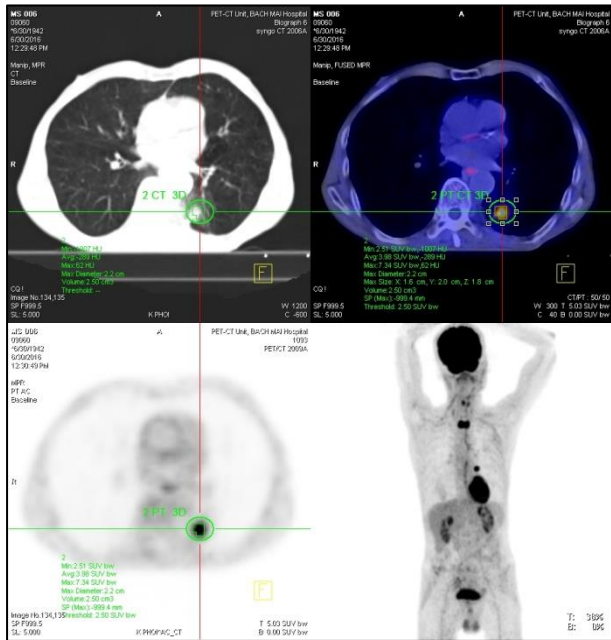


Figure 1: NSCLC patient with primary tumor.

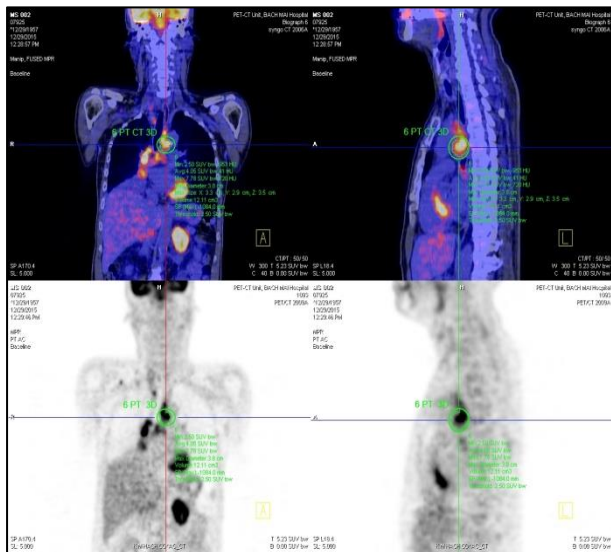


Figure 2: NSCLC patients with mediastinal metastase.

Among the 318 cases, lymph node metastases were seen in 250 cases (78.6%). Lymph node metastases were present in 80.2% (223/278) of adenocarcinomas, 71.4% (20/28) of squamous cell carcinomas, and 58.3% (7/12) of large cell carcinomas. When cases were divided into 4 groups according to lymph node involvement, there was no difference in tumor SUVmax between the groups. However, lymph node size was positively correlated with lymph node SUVmax ($r=0.758$, $p<0.001$). Tumor

SUVmax did not differ significantly according to the presence of distant metastases.

Some PET/CT images of NSCLC patients was showed in Figure 1 (the primary tumor with diameter of 2.2 cm and SUVmax 7.34), Figure 2 (mediastinal metastase with diameter of 3.8 cm and SUVmax 7.78) and figure 3 (adrenal gland metastase with diameter of 4.4 cm and SUVmax 9.06).

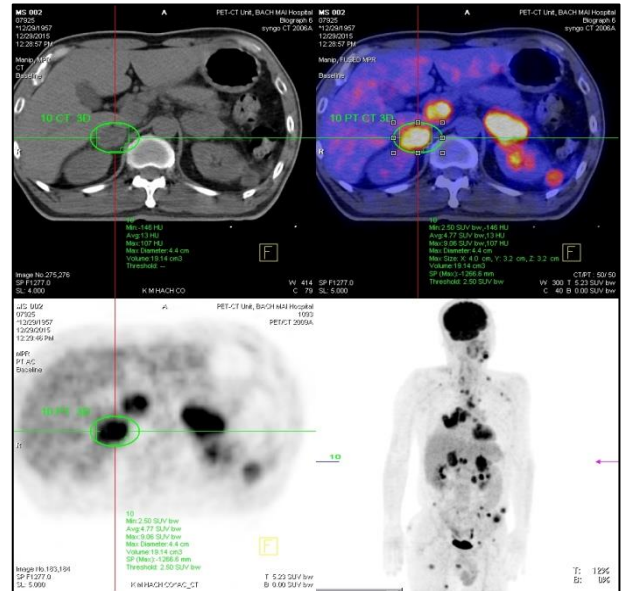


Figure 3: NSCLC with adrenal gland metastase.

DISCUSSION

Most of these results are descriptive. The usefulness of FDG-PET/CT in the staging process of NSCLC has been previously demonstrated, and this examination has become standard.³⁻⁷ In order to confirm this in this daily practice, authors decided to assess the impact of the use of FDG-PET/CT, the reason for conducting this study. So, authors analyzed each case of lung cancer in which FDG-PET/CT was performed including all histologies.

Aquino et al, reported a significant difference in FDG uptake between the well-differentiated adenocarcinoma subtype bronchioloalveolar carcinoma (BAC) and non-BAC adenocarcinomas, including well-differentiated non-BAC tumors.⁸ Adenocarcinomas with mixed features that included BAC had a peak SUV (1.5 ± 0.2) lower than that of all other non-BAC adenocarcinomas (SUV, 3 ± 1.5), which included one poor tumor, three moderate tumors, and one well-differentiated tumor.⁸ Vesselle et al, showed that the uptake by large cell carcinomas was greater than that by adenocarcinomas and was not significantly different from uptake by squamous cell carcinomas.¹ However, authors observed no difference in SUVmax among histological types. Our data were in concordance with previous studies that documented lower uptake by adenocarcinomas compared with squamous

cell carcinomas and lower uptake by BAC adenocarcinomas compared with non-BAC adenocarcinomas.

Fluorodeoxyglucose-PET-CT is already an indispensable modality for evaluating lymph node and distant metastases. Many reports have suggested that FDG-PET-CT is superior to CT in the accuracy of N-staging for lung cancer. Therefore, FDG-PET-CT is now regarded as the most accurate imaging modality for N-staging of lung cancer. However, a significant number of false-negative and false-positive findings of lung cancer, including N-staging, on FDG-PET-CT have been reported. Nambu et al, demonstrated that the likelihood of lymph node metastasis increased with an increase in SUVmax of the primary tumor; for primary lung cancer with a SUVmax greater than 12, the probability of lymph node metastasis was high, reaching 70%, irrespective of the degree of FDG accumulation in the lymph node stations.⁹

They concluded that this finding would allow a more sensitive prediction of the presence of lymph node metastases, including the microscopic ones that cannot be detected by direct evaluation of lymph node stations. Consistent with these results, Higashi et al, documented in a multicenter study that the incidence of lymphatic vessel invasion and lymph node metastasis in NSCLC were associated with 18 F-FDG uptake, concluding that 18 F-FDG uptake by a primary tumor is a strong predictor of lymphatic vessel invasion and lymph node metastasis.¹⁰ In the present study, although tumor SUVmax was higher in patients with lymph node metastasis than in those without, the difference did not reach statistical significance. Authors also observed that the frequency of lymph node metastasis was higher in adenocarcinomas (80.2%) than in squamous cell carcinomas (71.4%), suggesting that pathological subtype may be a significant factor associated with lymph node metastasis. In contrast, a previous study showed no difference in the frequency of lymph node metastasis between the two pathological subtypes.

Based on univariate analysis, Jeong et al, concluded that metastasis detected by PET imaging, which can affect staging by aiding in the discovery of metastasis to contralateral lymph nodes or distant organs, was an insignificant factor, and that metastatic findings on PET had weak discriminative power.¹¹

According to Cerfolio et al, FDG-PET-CT does not replace the need for tissue biopsies for staging N1 or N2 lymph nodes, or metastatic lesions, as false positives and false negatives were observed in all stations in their study.¹² However, FDG-PET-CT resulted in better patient selection before pulmonary resection. FDG-PET can also help in targeting areas for biopsy and identifying unsuspected N2 and M1 disease.² In the present study, tumor SUVmax was not significantly correlated with distant metastases. This may be attributable to the finding

of increased 18 F-FDG uptake by subclinical inflammatory lesions as well as by malignant tumors.

CONCLUSION

SUVmax was associated with tumor size, but not with distant metastases or lymph node involvement. Thus, SUVmax determined by FDG-PET-CT is not predictive of the presence of metastases. Moreover, SUVmax was not related to histological tumor. Larger prospective and randomized analyses may potentially reveal more significant relationships.

Funding: No funding sources

Conflict of interest: None declared

Ethical approval: The study was approved by the Institutional Ethics Committee

REFERENCES

1. Vesselle H, Salskov A, Turcotte E, Wiens L, Schmidt R, Jordan CD, et al. Relationship between non-small cell lung cancer FDG uptake at PET, tumor histology, and Ki-67 proliferation index. *J Thorac Oncol.* 2008 Sep 1;3(9):971-8.
2. Cerfolio RJ, Ojha B, Bryant AS, Bass CS, Bartalucci AA, Mountz JM. The role of FDG-PET scan in staging patients with nonsmall cell carcinoma. *Ann Thorac Surg.* 2003 Sep 1;76(3):861-6.
3. Lardinois D, Weder W, Hany TF, Kamel EM, Korom S, Seifert B, et al. Staging of non-small-cell lung cancer with integrated positron-emission tomography and computed tomography. *New Engl J Med.* 2003 Jun 19;348(25):2500-7.
4. Pieterman RM, van Putten JW, Meuzelaar JJ, Mooyaart EL, Vaalburg W, Koeter GH, et al. Preoperative staging of non-small-cell lung cancer with positron-emission tomography. *New Engl J Med.* 2000 Jul 27;343(4):254-61.
5. Toloza EM, Harpole L, McCrory DC. Noninvasive staging of non-small cell lung cancer: a review of the current evidence. *Chest.* 2003 Jan 1;123(1):137S-46S.
6. Crino L, Weder W, Van Meerbeeck J, Felip E. Early stage and locally advanced (non-metastatic) non-small-cell lung cancer: ESMO Clinical Practice Guidelines for diagnosis, treatment and follow-up. *Ann Oncol.* 2010 May;21(S 5):v103-15.
7. Ettinger DS, Akerley W, Bepler G, Blum MG, Chang A, Cheney RT, et al. Non-small cell lung cancer. *J Nation Comprehens Cancer Netw.* 2010 Jul 1;8(7):740-801.
8. Aquino SL, Halpern EF, Kuester LB, Fischman AJ. FDG-PET and CT features of non-small cell lung cancer based on tumor type. *Int J Mol Medi.* 2007 Mar 1;19(3):495-9.
9. Nambu A, Kato S, Sato Y, Okuwaki H, Nishikawa K, Saito A, et al. Relationship between maximum standardized uptake value (SUVmax) of lung cancer

- and lymph node metastasis on FDG-PET. *Ann Nuclear Med.* 2009 May 1;23(3):269-75.
10. Higashi K, Ito K, Hiramatsu Y, Ishikawa T, Sakuma T, Matsunari I, et al. 18F-FDG uptake by primary tumor as a predictor of intratumoral lymphatic vessel invasion and lymph node involvement in non-small cell lung cancer: analysis of a multicenter study. *J Nucl Med.* 2005 Feb 1;46(2):267-73.
 11. Jeong HJ, Min JJ, Park JM, Chung JK, Kim BT, Jeong JM, et al. Determination of the prognostic value of [18F] fluorodeoxyglucose uptake by using positron emission tomography in patients with non-small cell lung cancer. *Nucl Med Comm.* 2002 Sep 1;23(9):865-70.
 12. Cerfolio RJ, Bryant AS, Ohja B, Bartolucci AA. The maximum standardized uptake values on positron emission tomography of a non-small cell lung cancer predict stage, recurrence, and survival. *J Thor Cardiovasc Surg.* 2005 Jul 1;130(1):151-9.

Cite this article as: Xuan NM, Huy HQ. Impact of 18F-FDG PET/CT on the staging of patients with non-small cell lung cancer. *Int J Res Med Sci* 2020;8:2023-7.