

Original Research Article

Colorectal polyps and heterotrophic esophageal polyp of colon in a paediatric cohort in South India

Vishnu Abishek R., L. Venkatakrisnan, Mukundan S.*

Department of Gastroenterology, PSG Institute of Medical Sciences and Research, Coimbatore, Tamil Nadu, India

Received: 04 August 2018

Accepted: 10 August 2018

***Correspondence:**

Dr. Mukundan S.,

E-mail: mukund_444@yahoo.com

Copyright: © the author(s), publisher and licensee Medip Academy. This is an open-access article distributed under the terms of the Creative Commons Attribution Non-Commercial License, which permits unrestricted non-commercial use, distribution, and reproduction in any medium, provided the original work is properly cited.

ABSTRACT

Background: Clinical profile of polyps in paediatric cases are less in South India. Juvenile Polyps were the most common polyps in paediatric cases described in literature, presenting as LGI bleed. The aim of the study is to describe the clinical profile of colorectal polyps in paediatric population in a single tertiary care centre in South India.

Methods: Paediatric cases between 0 and 16 years of age who underwent colonoscopy in our department from January 2002 to July 2018 were included from database. These cases were retrospectively analysed for presence of polyps, clinical presentation, indication for colonoscopy, histopathology of the resected polyps and other demographic details. Incomplete procedures were excluded.

Results: About 166 paediatric cases underwent colonoscopy in the study period. 21 cases (12.65%) had colorectal Polyps. 85.7% of the polyps were in recto sigmoid region. Most common histological type was Juvenile Polyp (51.6%). One infant had sessile polyp in descending colon which was reported as heterotrophic esophageal mucosa in histopathology. LGI bleed was the most common presentation in children with polyps (66.6%).

Conclusions: The prevalence of polyps in our cohort was 12.65%. Solitary Juvenile Polyp was the most common polyp in children, with lower GI bleed as the most common presenting feature. Rare case of heterotrophic esophageal polyp was seen in descending colon.

Keywords: Colorectal polyps, Heterotrophic esophageal mucosa, Juvenile polyp, LGI bleed, Paediatric colonic polyp

INTRODUCTION

Colorectal polyps are well studied in the adult population with respect to type, clinical presentation, neoplastic potential and surveillance programmes. Polyps are less common in children than in adults. Various studies show a reported prevalence of 4 to 12 % for colorectal polyps in children.¹⁻³

Majority of colorectal polyps reported in the paediatric population are isolated Juvenile polyps predominantly located in the rectum and sigmoid colon with no malignant potential.^{4,5} The most common presentation of a polyp in children is rectal bleeding.⁶⁻⁸ Few studies have

reported the occurrence of adenomas and carcinomas in patients with solitary juvenile polyps.^{9,10} Data regarding the prevalence of colorectal polyps, clinical spectrum, demographic profile and histology which are essential for understanding the significance of polyps and their follow up are scanty in South India.

In this study we present the prevalence, clinical spectrum and histology of colorectal polyps from a tertiary care centre in South India.

Aim of the study was to assess the prevalence of colorectal polyps in paediatric population and to study the clinical and demographic profile of patients with polyps.

METHODS

Study design

This is a retrospective analysis of paediatric cases that underwent colonoscopy in our centre. Patients aged between 0 and 16 years of age who underwent colonoscopy in our department from January 2002 to July 2018 were retrieved from database. Those patients who had full length colonoscopy examination under general anaesthesia were included in the study.

These cases were analysed for presence of polyps based on the keywords polyps and polypectomy in the report. All colonoscopy cases were analysed for demography, clinical presentation, indication for colonoscopy and findings in colonoscopy. Polyps were analysed in detail regarding site of polyp, type of polyp, number of polyps in each case, size of each polyp, completeness of polypectomy and histopathology of the resected polyps. Incomplete colonoscopy procedures and polypectomy cases without proper follow up with histology reports were excluded.

Definition of polyp

An abnormal growth of tissue in the lining of the bowel.

Classification of polyp

Based on Paris classification, polyps are classified in to sessile or pedunculated. Type Is and Ip were included in the study. None of the patients had type II or type III polyps.

Abnormal colonoscopy findings description

Inflammation of colon was described in specific detail like inflammatory bowel disease or as non specific inflammation. Lymphoid nodules are commonly seen in terminal ileum in paediatric age group. Colonoscopic appearance was described as terminal ileal nodularity. Ulcers were identified by breach in mucosa with a crater. Nodules, ulcers in rectum are included in the diagnosis of solitary rectal ulcer syndrome.

Inclusion criteria

Colonoscopy cases with polyps as finding in the report and those subjected to polypectomy. Age of the patients should be between 1 month and 16 years. All cases should have undergone colonoscopy between January 2002 and mid July 2018.

Exclusion criteria

Colonoscopy cases with missing data, incomplete procedures and polypectomy cases with missing histopathology reports were excluded.

Statistical methods

Descriptive data was analysed using SPSS software version 24. Categorical variables were tabulated for frequency and percentage. No quantitative data available for calculating test of significance.

RESULTS

About 166 patients aged between 11 months and 16 years underwent colonoscopy under general anaesthesia between January 2002 and July 2018. 62% of the patients (n=103) were males. The most common indication for colonoscopy was abdominal pain 39.1% (n=65). Lower gastro intestinal tract bleed (LGI) was the indication for colonoscopy in 21.7% (n=36). Out of 166 colonoscopies 36.7% (n=60) had normal study, 12.6% (n=21) had polyps, followed by terminal ileal nodularity, inflammatory bowel disease (IBD) and solitary rectal ulcer (SRU) in 11.4%, 8.4% and 7.8% respectively. Table 1 shows the findings of colonoscopy in this cohort.

Table 1: Colonoscopy findings in 166 paediatric cases.

Normal	60/166 (36.7%)
Polyps	21/166 (12.65%)
Colonic and ileal non specific ulcers	21/166 (12.65%)
Terminal Ileal nodularity	19/166 (11.4%)
Inflammatory bowel disease	14/166 (8.43%)
Solitary rectal ulcer	13/166 (7.8%)
Others	18/166 (10.84%)

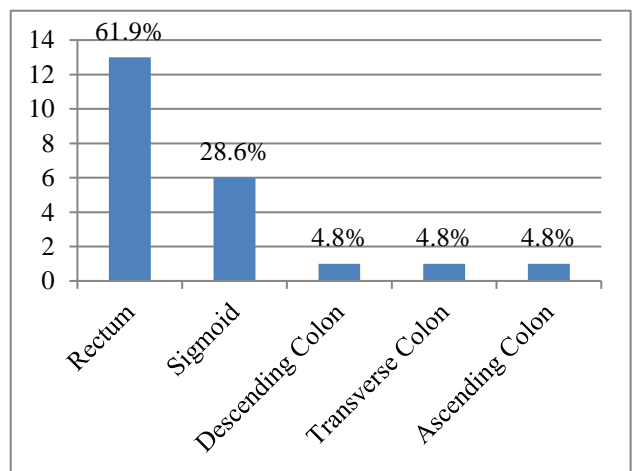


Figure 1: Site of polyps.

Total of 31 polyps were seen in 21 patients. 71.4% (n=15/21) of patients with polyps were males. The most common presentation in patients with polyps was LGI bleed (n=14, 66.6%) followed by diarrhoea (33.3%, n=7). The most common type of polyp seen in histology was juvenile polyps (51.6%, n=16/31), followed by inflammatory polyps (32%, n=10/31), pseudopolyps (9.6%, n=3/31) and 1 each of lymphoid polyp and heterotrophic esophageal mucosa. The location of polyps

was rectum in 61.9% (n=13/21), sigmoid colon in 23.8% (n=5/21) and 1 each in descending, transverse and ascending colon (Figure 1). About 76% of patients (n=16/21) had a single polyp, 23.8% (n=5) had multiple

polyps. 38.8% (n= 14/36) patients with LGI bleed had polyps and 66.6% (n=14/21) of patients with polyps presented with LGI bleed. Table 2 summarises the clinical profile of polyp cases.

Table 2: Clinical profile of paediatric cases with polyps.

Age in years	Sex	Indication	Site of polyp	Type of polyp	Biopsy
14	M	Mucus diarrhoea	Transverse colon	Sessile (5)	Inflammatory polyp
1	F	Abdominal pain	descending colon	pedunculated	Heterotrophic esophageal mucosa
13	M	Mucus Diarrhoea	Sigmoid	pedunculated	Inflammatory polyp
10	M	LGI Bleed	Rectum	pedunculated	Juvenile polyp
15	M	Diarrhoea, LGI bleed	Rectum	Sessile	Inflammatory polyp
13	F	LGI Bleed	Rectum	sessile	Juvenile polyp
10	F	LGI Bleed	Rectum	sessile	Juvenile
12	M	LGI Bleed	Rectum	pedunculated	Juvenile
1	M	LGI Bleed	Rectum	pedunculated	Juvenile polyp
1	M	LGI Bleed	Rectum	pedunculated	Juvenile polyp
15	M	Mucus diarrhoea	rectum	Pedunculated (2)	Inflammatory polyp
1	F	LGI Bleed	Sigmoid	Pedunculated	Juvenile retention polyp
1	M	LGI Bleed	Rectum	pedunculated	Juvenile polyp
14	M	Chronic diarrhoea	Sigmoid	sessile	Pseudo polyp
1	F	LGI Bleed	Rectum	pedunculated	Juvenile polyp
14	F	LGI Bleed	Sigmoid	pedunculated	Juvenile Polyp
11	M	Mucus diarrhoea	Sigmoid	pedunculated	Juvenile Polyp
1	M	LGI Bleed	Rectum	pedunculated	Juvenile polyp
15	M	Mucus diarrhoea	Rectum	Pedunculated	Inflammatory polyp
11	M	LGI Bleed	Ascending colon, rectum	sessile, pedunculated	Lymphoid polyp and Juvenile polyp
3	M	LGI Bleed	Sigmoid colon	Sessile (3), pedunculated	Juvenile Polyp

All the juvenile polyps were located in the distal colon (rectum 75% and sigmoid colon 25%). The most common presentation of juvenile polyps was LGI bleed (93.7%).

Out of the 166 colonoscopies, 9.6% (n=16) were done in toddlers (n=1) and infants (n=15). Indication for colonoscopy in infants was LGI bleed in 56.2% (9/16 cases). Among 21 patients with polyps 38% (n=8) were toddlers or infants. Seven out of the 8 infants had solitary juvenile polyp, with LGI bleed as the most common presentation. One infant had heterotropic esophageal mucosa in the descending colon. All polypectomy patients were followed up to a minimum duration of three years, and none of them had recurrence of symptoms.

DISCUSSION

Colorectal polyps are less common in the paediatric population compared to the adults. Only few studies in India have described the prevalence of polyps, the predominant histological type and clinical presentation in

the paediatric population. In our study, authors present the prevalence, clinical spectrum and histology of colorectal polyps from a tertiary care centre in South India. In this cohort of 166 children who underwent colonoscopy, 12.6% (n=21) had polyps which is in concordance with the prevalence seen in various studies (1, 2, 3). In this study, 71.4% of the patients with polyps were boys. 21.7% of the 166 cases subjected to colonoscopy had lower gastrointestinal tract bleed. However, in 21 patients who had polyps, the predominant presentation was LGI bleed (66.6%). Cumulatively, 31 polyps were seen in 21 patients. The most common type of polyp seen in histology was juvenile polyp (51.6%, n=16) followed by inflammatory polyp (32 %).

About 9.6% of the colonoscopies done for paediatric population were for infants and toddlers. Most common indication for the colonoscopy was lower gastrointestinal bleed. About 11/16 cases of colonoscopy performed in infants showed abnormal findings, making it a reliable investigation with good yield. 50% of colonoscopies in infants identified polyps and they were subjected to

polypectomy. About 6 cases had solitary juvenile polyps. One toddler had 3 juvenile polyps in sigmoid colon. The histology of polyps in this cohort was similar to other studies reported from North India.^{11,12} Most of the studies in literature have reported solitary juvenile polyps as the predominant histological type in children with colorectal polyps.^{2,11,13}

In a study by Poddar et al, in a tertiary care centre in North India male gender as a risk factor for polyps. In their study majority of children with polyps had bleeding per rectum as the main presenting feature.^{6,11} Thakkar et al, Gupta et al and Poddar et al reported painless bleeding per rectum as the single most common presenting feature in children you had polyps.^{2,6-8,11}

Juvenile polyps are mostly found in the left colon (90%) distal to the splenic flexure. Various studies done later have also reported an increased detection (5-26%) of juvenile polyps in the proximal or right colon.^{2,11,14} This increased detection rate of proximal polyps was seen in studies in which a pan colonoscopy was done. In our study all the juvenile polyps were located in the distal colon, 75% in the rectum and 25% in the sigmoid. Lower incidence of proximal juvenile polyps is reported from India and increased incidence reported from North American studies.² The exact reason for this difference is not clear but may be related to genetic and environmental factors.

Solitary Juvenile Polyp (JP) is histologically a non neoplastic hamartoma that is seen in 2% of children. It is characterised by distinctive cystic architecture, mucus-filled glands, a prominent lamina propria and dense infiltration with inflammatory cells. Colonoscopic appearance of this polyp is one to three cm smooth and reddish polyp head which may bleed easily.¹⁵ They do not have potential to turn malignant. Surveillance is not recommended.⁵ However, cases of single JP have been reported to show adenomatous changes and few incidences of colorectal cancer.^{2,10} Also, solitary JP cases with a family history of Juvenile Polyposis Syndrome (JPS) and multiple JP (more than 5 polyps) are both a criteria to suspect JPS.¹⁶ Family history may not be reliable in few instances. Hence a complete and careful pan colonoscopy examination is mandatory in juvenile polyp cases to identify JPS and juvenile polyps with malignant potential.

Heterotrophic esophageal mucosa was reported in one infant who had single sessile polyp in descending colon. The presenting feature in that case was implied abdominal pain and recurrent diarrhoea. Endoscopy and colonoscopy were performed in that child as part of pain and diarrhoea evaluation. Heterotrophic mucosa in polyp is very rare and has never been reported in paediatric polyps. This case was a rare instance. Previously reported case had described heterotrophic mucosa in terminal ileum and cecum in surgically resected specimen in a newborn.¹⁷

CONCLUSION

The prevalence of polyps in our cohort was 12.65%. Solitary Juvenile Polyp was the most common polyp in children, with lower GI bleed as the most common presenting feature. Rare case of heterotrophic esophageal polyp was seen in descending colon.

Funding: No funding sources

Conflict of interest: None declared

Ethical approval: The study was approved by the Institutional Ethics Committee

REFERENCES

1. Mougnot JF, Baldassarre ME, Mashako LM, Hanteclair GC, Dupont C, Leluyer B. Recto-colic polyps in the child. Analysis of 183 cases. Archives francaises de pediatrie. 1989 Apr;46(4):245-8.
2. Gupta SK, Fitzgerald JF, Croffie JM, Chong SK, Pfefferkorn MC, Davis MM, Faught PR. Experience with juvenile polyps in North American children: the need for pancolonoscopy. Am J Gastroenterol. 2001 Jun;96(6):1695.
3. Latt TT, Nicholl R, Domizio P, Walker-Smith JA, Williams CB. Rectal bleeding and polyps. Archives of disease in childhood. 1993 Jul 1;69(1):144-7.
4. Corredor J, Wambach J, Barnard J. Gastrointestinal polyps in children: Advances in molecular genetics, diagnosis, and management. J Pediatr. 2001;138:621-8.
5. Nugent KP, Talbot IC, Hodgson SV, Phillips RK. Solitary juvenile polyps: Not a marker for subsequent malignancy. Gastroenterol. 1993;105:698-700.
6. Holgersen LO, Mossberg SM, Miller RE. Colonoscopy for rectal bleeding in children. J Pediatr Surg 1978;13:83.
7. Waitayakul S, Singhavejsakul J, Ukarapol N: Clinical characteristics of colorectal polyp in Thai children: a retrospective study. J Med Assoc Thai 2004; 87:41-6.
8. Güitrón A, Adalid R, Nares J, Mena G, Gutierrez JA. Colonic polyps in children. Experience with polypectomy. Revista de gastroenterologia de Mexico. 1999;64(1):19-22.
9. Giardiello FM, Hamilton SR, Kern SE, Offerhaus GJ, Green PA, Celano P, et al. Colorectal neoplasia in juvenile polyposis or juvenile polyps. Archives of disease in childhood. 1991 Aug 1;66(8):971-5.
10. Mestre JR. The changing pattern of juvenile polyps. Am J Gastroenterol 1986;81(5):312-4.
11. Poddar U, Thapa BR, Vaiphei K, Singh K. Colonic polyps: experience of 236 Indian children. Am J Gastroenterol. 1998 Apr;93(4):619.
12. Jalihal A, Misra SP, Arvind AS, Kamath PS. Colonoscopic polypectomy in children. J Pediatric Surg. 1992 Sep 1;27(9):1220-2.
13. Thakkar K, Alsarraj A, Fong E, Holub JL, Gilger MA, El Serag HB, et al. Prevalence of colorectal

- polyps in pediatric colonoscopy. *Dig Dis Sci.* 2012;57(4).
14. Cynamon HA, Milov DE, Andres JM. Diagnosis and management of colonic polyps in children. *J Pediatr.* 1989;114:593-6.
 15. Perisic VN. Colorectal Polyps: An Important Cause of Rectal Bleeding. *Arch Dis Child.* 1987;62:188-9.
 16. Jass JR, Williams CB, Bussey HJ, Morson BC. Juvenile polyposis-a precancerous condition. *Histopathology.* 1988 Dec;13(6):619-30.
 17. Aterman K, Abaci F. Heterotopic Gastric and Esophageal Tissue in the Colon. *Am J Dis Child.* 1967;113(5):552-9.

Cite this article as: Vishnu AR, Venkatakrishnan L, Mukundan S. Colorectal polyps and heterotrophic esophageal polyp of colon in a paediatric cohort in South India. *Int J Res Med Sci* 2018;6:2969-73.