

Case Report

Accessory belly of flexor digitorum superficialis - case report of a rare variant

Umesh Choudhary¹, Shrish S. Patil^{1*}, Mahesh G.M.¹, Amit K. Singh²

¹Department of Anatomy, Basaveshwara Medical College and Hospital, Chitradurga, Karnataka-577502, India

²Department of Forensic Medicine & Toxicology, Basaveshwara Medical College and Hospital, Chitradurga, Karnataka-577502, India

Received: 02 January 2015

Accepted: 19 January 2015

***Correspondence:**

Dr. Shrish S. Patil,

E-mail: patilssp_2003@yahoo.co.in

Copyright: © the author(s), publisher and licensee Medip Academy. This is an open-access article distributed under the terms of the Creative Commons Attribution Non-Commercial License, which permits unrestricted non-commercial use, distribution, and reproduction in any medium, provided the original work is properly cited.

ABSTRACT

Variations of the muscles pose a challenge to diagnosis and knowledge about them is important during surgeries and other interventions. At times these variations may cause symptoms per se. Variations of the Flexor digitorum superficialis: a muscle of the anterior compartment of forearm, are not very common. We present a rare variation of this muscle in the right upper limb of a male cadaver. The variant was an accessory belly arising from and under the Flexor digitorum superficialis and inserting into the base of proximal phalanx of the index finger. We also review the evolutionary and embryological concepts of such variations.

Keywords: Variation, Flexor digitorum superficialis, Accessory belly, Carpal tunnel syndrome, Evolution

INTRODUCTION

Variations of muscles of the limbs are very common. Most of the times, these variations are asymptomatic and are incidental findings during post-mortem studies or surgeries in patients for some other indication. The exact incidence of variations cannot be estimated since many are undiagnosed or go unreported. Variations of the muscles involve absence of muscles, duplication of muscles, variant origin and/or insertion or deviations in relations to other nearby structures. The muscular variations are usually overlooked during imaging studies.¹ Even with newer imaging techniques being available, the diagnosis is still incidental and usually nothing needs to be done for the variant as they are asymptomatic. The usual reason a patient may present with symptoms is due to the mass effect of the anomalous muscle on local or adjacent structures- especially nerves and arteries.^{2,3} Of all the muscles, variations of the flexor digitorum longus muscle are said to be one of the commonest in man.⁴

CASE REPORT

During routine dissection for undergraduate classes we came across a variation of the Flexor digitorum superficialis (FDS) muscle in the right upper limb of a 65 year old male cadaver. An accessory belly was observed taking origin from a tendon on the middle of undersurface of FDS (Figure 1). The tendon gave rise to a muscle belly which again became tendinous. The total length of the accessory muscle with its tendons measured 20 cm. The tendon of origin, the muscle belly and the tendon of insertion measured 4.0 cm, 2.5 cm and 13.5 cm respectively. The tendon of insertion was joined by a few muscle fibers from the first lumbrical, which was otherwise normal. The accessory muscle inserted by its own tendon into the base of proximal phalanx of the index finger (Figure 2). The tendon of insertion passed under the flexor retinaculum along-with the tendons of FDS and Flexor digitorum profundus (FDP); was medially related to the FDS tendon of index finger and laterally to the thenar muscles, distal to the level of wrist

joint. A separate nerve supply to the accessory belly could not be found.

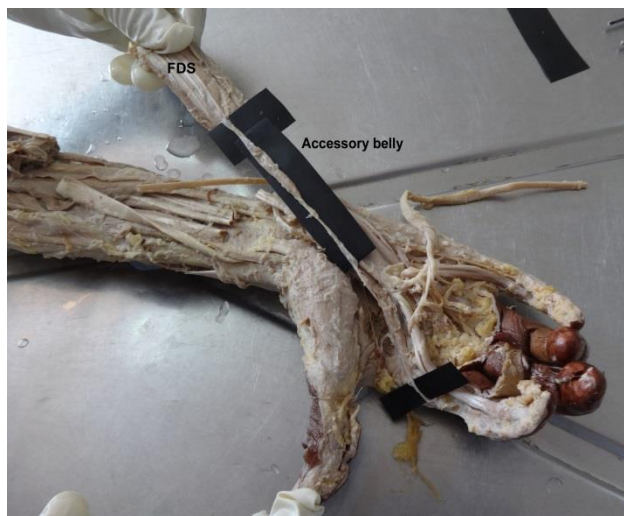

Figure 1: Accessory belly on the undersurface of Flexor Digitorum Superficialis.

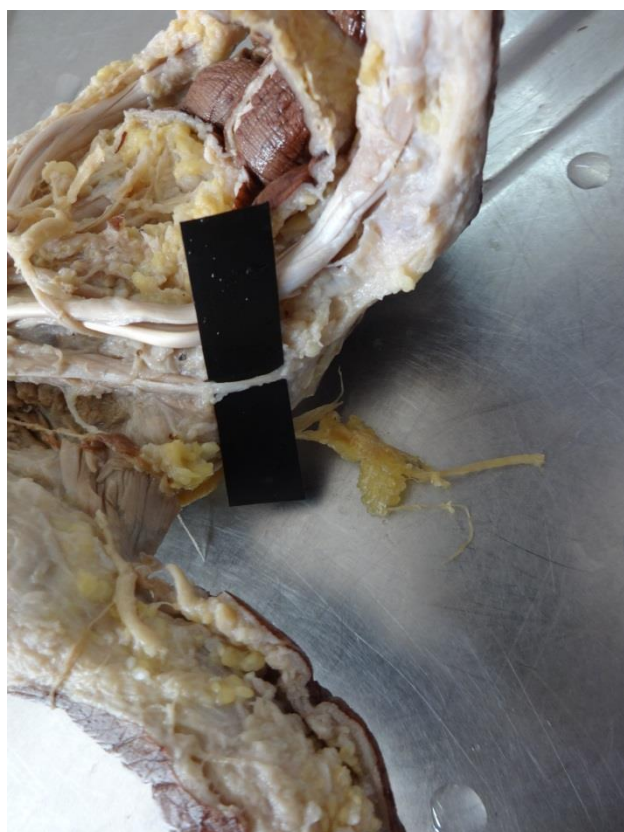


Figure 2: The insertion of the accessory belly into the base of proximal phalanx of the index finger.

DISCUSSION

FDS is the largest of the superficial flexors of the anterior compartment of forearm and acts as a flexor of wrist and joints (Proximal Inter Phalangeal and Metacarpo-

Phalangeal) of second to fifth digits. Some authors do mention it as being the sole member of intermediate group of muscles of front of forearm.^{5,6} It takes origin from two heads- Humero-ulnar head and Radial head. The two origins are connected to each other by an aponeurosis covering the median nerve and ulnar artery. It has individual muscle slips to each finger, which is in contrast to FDP.⁷ The bulk of the muscle is usually disposed in two strata. The superficial stratum gives off tendons to middle and ring fingers and the deep to the ring, index and little fingers. The four tendons of the muscle pass under the flexor retinaculum in two pairs- the superficial going to middle and ring fingers, and the deeper two to the index and the little finger. The FDS tendon for each digit splits into two, pass around the profundus tendon, reunite and insert into the middle phalanx. The muscle gets its nerve supply from the Median nerve (C7, C8 and T1).⁶⁻⁸

Variations of FDS

Several variations have been reported with respect to FDS. Bergman et al have listed some of them.⁹ A review of published reports show that the variations of the flexor digitorum superficialis are mainly associated with the tendon to little finger.¹⁰⁻¹² Quite often splitting of bellies of FDS to a particular digit are seen.¹⁰ However an accessory belly of Flexor Digitorum superficialis is rare. Within this rare group, variations of the origin and insertion have been reported.¹³⁻¹⁵ Cases of a rare accessory FDS indicis muscle have been reported by some researchers.^{2,16}

A case of accessory muscle bellies arising from FDS and inserting into the fifth tendon of FDP has been reported.¹⁷ Bergman et al. have described an anomalous muscle which they have termed 'Palmar flexor digitorum superficialis accessorius' which took origin from the palmar fascia and distal border of the transverse carpal ligament and inserted into a tendon that joined the flexor tendon of the index finger at the metacarpophalangeal joint.⁹

Anita et al. have reported a bilateral case of accessory belly of FDS; but in both sides the bellies rejoined the original tendon of FDS to index finger.¹⁸ D'Costa et al. have described an accessory belly replacing the tendon of FDS to index finger.¹⁹

Concepts of evolution of forearm and hand muscles

In amphibians the flexor digitorum is considered to be an intrinsic muscle of the palm. During evolution, the muscles of the hand have undergone reduction in number: The FDS having lost its connection with the carpals attach to the common flexor muscles of the forearm.^{6,20} Romer proposes that the long flexors of digits in aquatic animals underwent a modification in reptiles to overcome the difficulty of passing around a curve on the ventral aspect of the wrist.²¹ Theories proposed by Mainland for

the appearance of variations of FDS include migration, rearrangement or division of the primitive muscle.²² Congdon denies the supposition that such anomalous muscles arose from paired short superficial flexors, since cases having the sublimis tendon coexisting with rudiments of short flexors are rarely seen.²³ McMurrich in his detailed description of the evolution of the long flexors in man, has recognized three stages.²⁴ Probably, the accessory muscle belly encountered by us is an atavistic muscle as proposed by Romer.

Clinical significance of our case

As the carpal tunnel is a restricted space which cannot expand, pressure effects may arise due to decreased space or increased thickness of its contents. Some systemic conditions like diabetes mellitus, amyloidosis, gout have been implicated in the causation of carpal tunnel syndrome (CTS).^{25,26} Kerasnoudis has reported a case of an elongated muscle belly of FDS causing CTS- the first of its kind.²⁷

CONCLUSIONS

Knowledge of variations of muscles is important for general surgeons, orthopaedicians and radiologists. The exact incidence of the variations cannot be arrived at since majority of them go unnoticed as they do not cause any disability. The evolutionary theories do throw light on the causes of such variations.

ACKNOWLEDGEMENTS

Authors would like to gratefully acknowledge the help rendered by Dr. K. Shekharappa, Dr. M. Gurushanthaiah, Dr. S. Vijayakumar, Dr. Saryu Sain, Mr. Sateesh Naik, Ms. T. Sharmila, Mrs. Madhavi K, Mr. Mahendraverma and the staff of Anatomy department.

Funding: No funding sources

Conflict of interest: None declared

Ethical approval: Not required

REFERENCES

- Zammit J, Singh D. The peroneus quartus muscle. Anatomy and clinical relevance. J Bone Joint Surg Br. 2003;85(8):1134-7.
- Sookur PA, Naraghi AM, Bleakney RR, Jalan R, Chan O, White LM. Accessory muscles: anatomy, symptoms, and radiologic evaluation. Radiographics. 2008;28(2):481-99.
- Ciftcioglu E, Kopuz C, Corumlu U, Demir MT. Accessory muscle in the forearm: a clinical and embryological approach. Anat Cell Biol. 2011;44(2):160-3.
- Tan JS, Oh L, Louis DS. Variations of the flexor digitorum superficialis as determined by an expanded clinical examination. J Hand Surg Am. 2009;34(5):900-6.
- Snell RS. The upper limb. In: Clinical anatomy by regions. 8th Ed. New Delhi, Wolters Kulwer, LWW; 2008.
- Vichare NA. Anomalous muscle belly of the flexor digitorum superficialis. J Bone Joint Surg 1970; 52(4);757-9.
- Salmons S. Muscle. In: Williams PL, Bannister LH, Berry MM, Collins P, Dyson M, Dussek JE, et al , eds. Gray's Anatomy 38th Ed. New York: Churchill Livingstone, 1995.
- Wheless' text book of orthopaedics, Ed- Wheelless CR. Available at http://www.whelessonline.com/ortho/flexor_digitorum_superficialis. Accessed 1 January 2015.
- Bergman R A, Afifi AK, Miyauchi R- Illustrated Encyclopedia of Human Anatomic Variation: Opus I: Muscular System: Alphabetical Listing of Muscles: F, Flexor Digitorum Superficialis (Sublimis). Available at <http://www.anatomyatlases.org/AnatomicVariants/MuscularSystem/Text/F/17Flexor.shtml> Accessed on 1 December 2015.
- Rao M, Ashwini LS, Nagabhushana S, Mishra S, Guru A, Rao A. Separate belly and tendon of flexor digitorum superficialis to the fifth digit. Oman Med Jour 2011;26(6).
- Austin GJ, Leslie BM, Ruby LK. Variations of the flexor digitorum superficialis of the small finger. J Hand Surg Am 1989;14(2 Pt1):262-7.
- Gonzalez MH, Whittum J, Kogan M, Weinzwieg N. Variations of the flexor digitorum superficialis tendon of the little finger. J Hand Surg Br 1997;22(2):277-80.
- Elias LS, Schuller-Ellis FP. Anomalous flexor superficialis indicis: two case reports and literature review. J Hand Surg Am 1985;10:296-9.
- Probst CE, Hunter JM. A digastric flexor digitorum superficialis. Bull Hosp Joint Dis 1975;36:52-7.
- Christensen S. Anomalous muscle belly of the flexor digitorum superficialis in two generations. Hand 1977;9:162-4.
- Dixit SG, Kakar S. An uncommon variation of flexor digitorum superficialis indicis, a case report: Anatomical and clinical relevance. Clinical anatomy 2010;23(8):889-90.
- Chakravarthi KK. Unusual unilateral muscular variations of the flexor compartment of forearm and hand- a case report. Int J Med Health Sci 2012;1(3):93-8.
- Anita T, Kalbande S, Asha K, Dombe D, Jayasree N. A unique variation of flexor digitorum superficialis muscle and its clinical significance. J Life Sci 2012;4(1):39-43.
- D'costa S, Jiji, Nayak SR, Sivanandan R, Abhishek. Anomalous muscle belly to the index finger. Ann Anatomy 2006;188(5): 473-5.
- Bunnell S. Surgery of the Hand. 4th ed. Montreal and Philadelphia: JB Lippincott Company; 1964:7.
- Romer AS. The vertebrate body. 3rd ed. Bombay: Vakils Feffer and Simons Pvt Ltd; 1969: 249- 87.

22. Mainland D. An uncommon abnormality of the flexor digitorum sublimis muscle. *J Anat* 1927;62:86-9.
23. Congdon ED. Anomalous fibrous cords in the hand and the phylogeny of the flexor digitorum sublimis tendon. *Anat Rec* 1920;19(3):159-63.
24. McMurrich JP. The phylogeny of the forearm flexors. *Amer J Anat* 1903; 2 (2), 177-209.
25. Entin MA. Carpal tunnel syndrome and its variants. *Surg Clin North Am* 1968; 48:1097-112.
26. Chammas M, Boretto J, Burmann LM, Ramos RM, dos Santos Neto FC, Silva JB. Carpal tunnel syndrome – Part I (anatomy, physiology, etiology and diagnosis) *Rev Bras Ortop* 2014; 49(5):429-36.
27. Kerasnoudis A. Elongated muscle belly of the flexor digitorum superficialis causing carpal tunnel syndrome. *Hand* 2012; 7:333-4.

DOI: 10.5455/2320-6012.ijrms20150220
Cite this article as: Choudhary U, Patil SS, G.M Mahesh, Singh AK. Accessory belly of flexor digitorum superficialis- case report of a rare variant. *Int J Res Med Sci* 2015;3:488-91.