

Case Report

A rare association of Kimura's disease with chronic pulmonary aspergillosis

Laxma Reddy S., Bhaskar K.*, Vara Prasad K., Paramjyothi G. K.

Department of Pulmonary Medicine, Nizam's Institute of Medical Sciences, Hyderabad, Telangana, India

Received: 13 February 2018

Accepted: 28 March 2018

***Correspondence:**

Dr. Bhaskar K.,

E-mail: bhaskarsr999@gmail.com

Copyright: © the author(s), publisher and licensee Medip Academy. This is an open-access article distributed under the terms of the Creative Commons Attribution Non-Commercial License, which permits unrestricted non-commercial use, distribution, and reproduction in any medium, provided the original work is properly cited.

ABSTRACT

Kimura's disease is a rare chronic benign inflammatory condition characterised by nodules of skin and soft tissue and lymphnodes. Eosinophilic infiltration is a prominent finding. It has been reported in association with various conditions like nephrotic syndrome, bronchial asthma, ulcerative colitis and aortitis syndrome. Hereby we present a case in medical literature to the best of our knowledge in Kimura's disease in association with chronic cavitary pulmonary aspergillosis, which has never been reported. He was treated with antifungals, after which he responded clinically, eosinophilia has subsided and he is under regular follow up. Now This case report suggest possible role of chronic aspergillosis as a cause for Kimura's disease.

Keywords: Chronic pulmonary aspergillosis, Kimura's disease

INTRODUCTION

Kimura's disease (KD) or eosinophilic hyperplastic lymphogranuloma was first described in 1948 by Kimura and coworkers.¹

It is a chronic inflammatory disease of unknown etiology. It is manifested by swelling of subcutaneous tissue accompanied by satellite lymphadenopathy in the cervical region associated with hypereosinophilia and elevated serum IgE.² It can be associated with various disorders like bronchial asthma, allergic rhinitis, atopic dermatitis, urticaria and nephritic syndrome.³

Hereby we report a case of Kimura disease in association with chronic cavitary pulmonary aspergillosis(CCPA). To the best of our knowledge, this is the first report of CCPA related to KD.

In a review of 429 Japanese cases of KD, Ishii identified associations in 14 cases of nephritic syndrome, five cases

of bronchial asthma, three cases of allergic rhinitis, two cases of atopic dermatitis and five cases of urticaria, suggesting that an allergic mechanism may have contributed to KD in these patients.⁴

CASE REPORT

A 35-year-old man admitted in our hospital with complaints of cough, shortness of breath of 3 months duration and weight loss since 2 months. Cough was associated with scanty, white, mucoid sputum. SOB was insidious onset, gradually progressed to grade 2 mMRC. Weight loss about 5-6kgs over 2 months was observed. No history of hemoptysis, fever, wheezing, chest tightness, stridor. He had past history of pulmonary tuberculosis and took anti tubercular treatment for 6 years back.

On examination patient was conscious, coherent. No pallor, cyanosis, icterus, pedal edema. A 1x 2cm firm, mobile, nontender left supraclavicular lymph node was

present. Grade 3 clubbing was present. Patient was afebrile, pulse rate was-100 per minute, blood pressure - 100/60mmHg, respiratory rate was 20 cycles per minute. Bilateral bronchial breath sounds on infraclavicular areas and bilateral basal crepitations were present. Other systems examination was normal.

His laboratory assessment showed hemoglobin of 12.2 g/dl with total leucocyte count of 20,100 cells per mm³ (N-35%, E-54%, M-9%). Renal function tests and liver function tests were normal. Viral markers were negative. P-ANCA and C-ANCA were negative. Serum immunoglobulins-IgE-340U/L (normal values: up to 150), IgG-2688mg/dL (800-1700), IgM 209mg/dL (90-320), IgA-312mg/dL (150-440). Sputum examination was negative for acid fast bacilli and fungi.

Ultrasound abdomen showed non visualization of right kidney with compensatory hypertrophy of left kidney and 2D echocardiography was normal. HRCT chest showed bilateral thick walled irregular cavities involving both upper lower lobes and lower lobes (Figure 1).

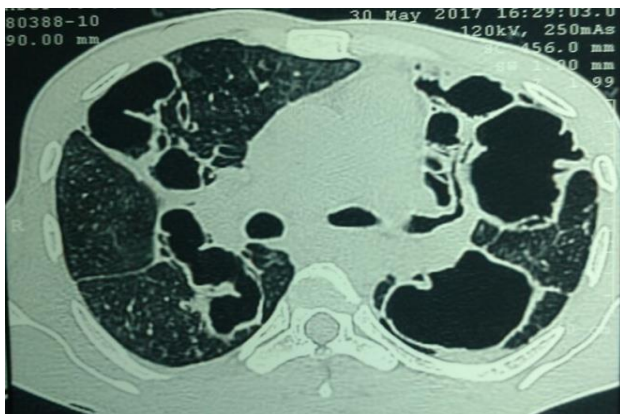


Figure 1: HRCT chest showing bilateral thick walled irregular cavities.

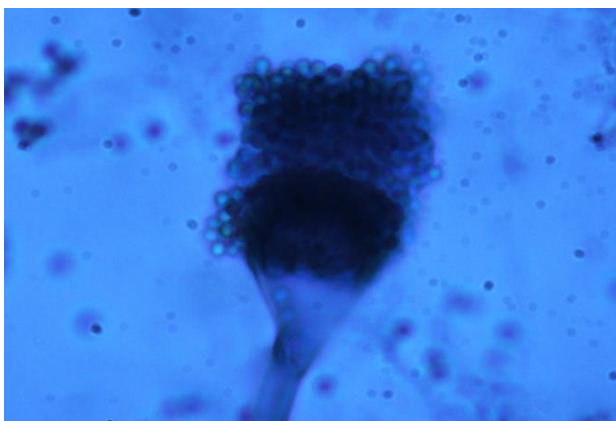


Figure 2: Lactophenol cotton blue staining showing biserialiation with compact columnar conidia. Phialides covering two thirds of the head.

Bronchoalveolar lavage (BAL) showed total count of 1500 with 90% polymorphs and 10% lymphocytes, Aspergillus galactomannan (GAM) was positive, fungal staining showed septate hyphae and fungal culture showed growth of *Aspergillus fumigatus* (Figure 2). Serum galactomannan was negative and Aspergillus specific IgG antibodies were positive. Based on above findings a diagnosis of Chronic Cavitary Pulmonary Aspergillosis (CCPA) with pulmonary tuberculosis sequelae was made and lymph node excision was done to rule out relapse of tuberculosis and fungal infections. Lymph node excision biopsy showed extensive eosinophilic infiltration of capsule, sinuses suggestive of kimura disease (Figure 3).

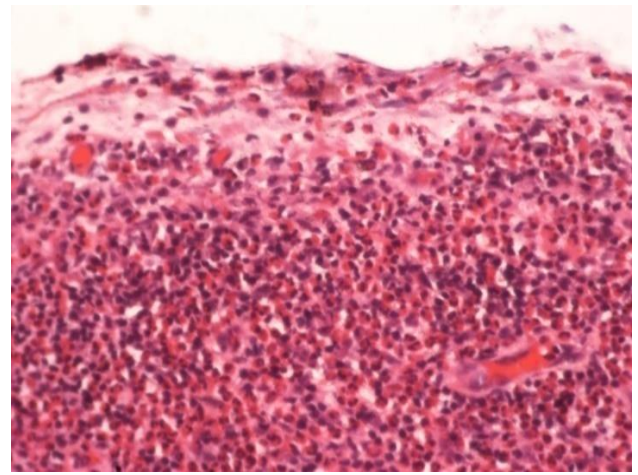


Figure 3: Lymph node biopsy showing extensive eosinophilic infiltration of capsule and sinuses.

With these features of clinical, radiographic, microbiological and histopathology, he was diagnosed to have chronic cavitary pulmonary aspergillosis with Kimura disease and, he is started on itraconazole. Patient responded clinically eosinophilia has reduced and he is on regular follow up.

DISCUSSION

Kimura disease is a rare, chronic inflammatory disorder of unknown etiology that occurs primarily in Asians and is characterized by benign slow-growing subcutaneous nodules.^{1,2} Most cases of Kimura disease have been reported in Asians, and the prevalence among persons of other races is thought to be low.⁵

Males are affected by Kimura disease more commonly than females, with a 3.5:1 to 9:1 ratio in most series reported, with the maximum of 19:1 in one case series^{6,7}. Kimura disease is usually seen in young adults during the third decade of life, with the median age being 28-32 years.⁸⁻¹⁰ Although rare, pediatric populations can develop Kimura disease, and cases have been reported in persons aged as young as 15 months.¹¹

The pathophysiology of Kimura disease remains unknown. It has been hypothesized that an infection or toxin may trigger an autoimmune phenomenon or lead to a type I (immunoglobulin E (IgE) mediated) hypersensitivity reaction. Some evidence has suggested a predominance of T_H2 cells in patients with Kimura disease.¹² Additional studies have shown elevated granulocyte-macrophage stimulating-factor (GM-CSF), tumor necrosis factor- α (TNF- α), soluble interleukin (IL)-2 receptor (sIL-2R), IL-4, IL-5, IL-10, and IL-13.^{13,14} Another study indicated that the activation of the IL-21/pERK1/2 pathway is a component of Kimura disease immunopathogenesis and pERK1/2 could be a potential prognostic indicator of the disease.¹⁵ These findings may help lay the groundwork for elucidating the underlying pathophysiology of Kimura disease.

The disease is characterized soft-tissue masses in the head and neck region with or without involvement of regional lymph nodes.¹⁶⁻¹⁸ It's a benign chronic inflammatory condition with lymphocytic proliferation associated with peripheral blood eosinophilia and elevated IgE levels as additional laboratory findings especially in Japanese patients.¹⁹ Other organs can be involved are salivary glands and skeletal muscles.

Another condition that closely resembles Kimura disease is Angiolymphoid hyperplasia with eosinophilia (ALHE). ALHE is a benign vascular proliferation condition involving dermal vessels. Literature is available where both diseases coexisting in a single patient.²⁰⁻²² Recent reports however have confirmed that the two are in fact separate entities.³ ALHE is clinically characterised by papular lesions involving head and neck with less association of eosinophilia.²³ Histologically, Kimura is characterised by follicular hyperplasia with prominent germinal centre, lymphocytic, plasma cell and eosinophilic in lymphnodes. Eosinophilic infiltration may be intense and resemble eosinophilic abscesses. Presence of epithelioid endothelial cells in the blood vessels, prominent fibrosis, and mild lymphocytic infiltration of germinal centres are present in ALHE and differentiate from Kimura.

Treatment options include surgical resection, local radiotherapy or combined modality with least possible recurrences. Photodynamic therapy has been used in individual case reports for recurrences.²⁴ Other include omalizumab.²⁵ Prognosis is good. Complications such as nephrotic syndrome, bronchial asthma, atopic dermatitis, urticaria, ulcerative colitis, aortitis syndrome have been reported.²⁶⁻³²

CONCLUSION

Kimura's disease is a rare benign chronic inflammatory condition associated with many diseases like asthma, atopic dermatitis, nephrotic syndrome, ulcerative colitis and aortitis syndrome. Our case report highlights the

association with chronic pulmonary aspergillosis and good response to medication.

Funding: No funding sources

Conflict of interest: None declared

Ethical approval: Not required

REFERENCES

1. Kimura T. On the unusual granulation combined with hyperplastic changes of lymphoid tissue. *Trans. Soc Pathol Jpn.* 1948;37:179-90.
2. Yuen HW, Goh YH, Low WK, Lim-Tan SK. Kimura's disease: a diagnostic and therapeutic challenge. *Singapore Medical J.* 2005;46(4):179.
3. Sah P, Kamath A, Aramanadka C, Radhakrishnan R. Kimura's disease-An unusual presentation involving subcutaneous tissue, parotid gland and lymph node. *JOMFP.* 2013;17(3):455.
4. Ishii M. Kimura's disease: a review of 429 cases and four new cases. *Oto-Rhino-Laryngology Tokyo.* 1982;25:407-16.
5. Kung IT, Gibson JB, Bannatyne PM. Kimura's disease: a clinico-pathological study of 21 cases and its distinction from angiolymphoid hyperplasia with eosinophilia. *Pathology.* 1984;16(1):39-44.
6. AlGhamdi FE, Al-Khatib TA, Marzouki HZ, AlGarni MA. Kimura disease: No age or ethnicity limit. *Saudi Med J.* 2016;37(3):315-9.
7. Wang DY, Mao JH, Zhang Y, Gu WZ, Zhao SA, Chen YF, et al. Kimura disease: a case report and review of the Chinese literature. *Nephron Clinical Practice.* 2009;111(1):c55-61.
8. Kung IT, Gibson JB, Bannatyne PM. Kimura's disease: a clinico-pathological study of 21 cases and its distinction from angiolymphoid hyperplasia with eosinophilia. *Pathology.* 1984;16(1):39-44.
9. Thomas J, Jayachandran NV, Chandrasekhara PK, Rajasekhar L, Narsimulu G. Kimura's disease-an unusual cause of lymphadenopathy in children. *Clin Rheumatol.* 2008;27(5):675-7.
10. Chen H, Thompson LD, Aguilera NS, Abbondanzo SL. Kimura disease: a clinicopathologic study of 21 cases. *Am J Surg Pathol.* 2004;28(4):505-13.
11. AlGhamdi FE, Al-Khatib TA, Marzouki HZ, AlGarni MA. Kimura disease: No age or ethnicity limit. *Saudi Med J.* 2016;37(3):315-9.
12. Ohta N, Fukase S, Suzuki Y, Ito T, Yoshitake H, Aoyagi M. Increase of Th2 and Tc1 cells in patients with Kimura's disease. *Auris Nasus Larynx.* 2011;38(1):77-82.
13. Katagiri K, Itami S, Hatano Y, Yamaguchi T, Takayasu S. In vivo expression of IL-4, IL-5, IL-13 and IFN-gamma mRNAs in peripheral blood mononuclear cells and effect of cyclosporin A in a patient with Kimura's disease. *Br J Dermatol.* 1997;137(6):972-7.
14. Hosoki K, Hirayama M, Kephart GM, Kita H, Nagao M, Uchizono H, et al. Elevated numbers of cells producing interleukin-5 and interleukin-10 in a

- boy with Kimura disease. *Inter Archives Allergy Immunol.* 2012;158(Suppl. 1):70-4.
15. Chen QL, Li CX, Shao B, Gong ZC, Liu H, Ling B, et al. Expression of the interleukin-21 and phosphorylated extracellular signal regulated kinase 1/2 in Kimura disease. *J Clin Pathol.* 2017.
 16. Kung ITM, Gibson JB, Bannatyne PM. Kimura's disease: a clinico-pathological study of 21 cases and its distinction from angiolymphoid hyperplasia with eosinophilia. *Pathology.* 1984;16:39-44.
 17. Reed RJ, Terazakis N. Subcutaneous angioblastic lymphoid hyperplasia with eosinophilia (Kimura's disease). *Cancer.* 1972;29:489-497.
 18. Chan JKC, Hui PK, Ng CS, Yuen NWF, Kung ITM, Gwi E. Epithelioid hemangioma (angiolymphoid hyperplasia with eosinophilia) and Kimura's disease in Chinese. *Histopathol.* 1989;15:557-74.
 19. Kawada A, Takahashi H, Anzai T. Eosinophilic lymphofolliculosis of the skin (Kimura's disease). *Jpn J Dermatol.* 1966;76:61-72.
 20. Chong WS, Thomas A, Goh CL. Kimura's disease and angiolymphoid hyperplasia with eosinophilia: two disease entities in the same patient: case report and review of the literature. *Int J Dermatol.* 2006;45(2):139-45.
 21. Liu XK, Ren J, Wang XH, Li XS, Zhang HP, Zeng K. Angiolymphoid hyperplasia with eosinophilia and Kimura's disease coexisting in the same patient: evidence for a spectrum of disease. *Australas J Dermatol.* 2012;53(3):e47-50.
 22. Ioachim HL, Medeiros LJ. Kimura lymphadenopathy. In: Ioachim's Lymph Node Pathology. 4th ed. Ioachim HL, Medeiros LJ, Eds. Lippincott Williams & Wilkins, Philadelphia, 2008:190-192.
 23. Kuo TT, Shih LY, Chan HL. Kimura's disease. Involvement of regional lymph nodes and distinction from angiolymphoid hyperplasia with eosinophilia. *Am J Surg Pathol.* 1988;12(11):843-54.
 24. Abbas S, Jerjes W, Upile T, Vincent A, Hopper C. Treatment of Kimura disease with photodynamic therapy: a case study. *Photodiagnosis Photodyn Ther.* 2012;9(1):83-6.
 25. Nonaka M, Sakitani E, Yoshihara T. Anti-IgE therapy to Kimura's disease: a pilot study. *AurisNasus Larynx.* 2014;41(4):384-8.
 26. Whelan TV, Maher JF, Kragel P, Dysart N, Dannenhoffer R, Prager L. Nephrotic syndrome associated with Kimura's disease. *Am J Kidney Diseases.* 1988;11(4):353-6.
 27. Matsumoto K, Katayama H, Hatano M. Minimal-change nephritic syndrome associated with subcutaneous eosinophilic lymphoid granuloma (Kimura's disease). *Nephron.* 1988;49:251-4.
 28. Obata Y, Furuu A, Nishino T, Ichinose H, Ohnita A, Iwasaki K, et al. Membranous nephropathy and Kimura's disease manifesting a hip mass. A case report with literature review. *Internal Medicine.* 2010;49(14):1405-9.
 29. Tsukagoshi H, Nagashima M, Horie T, Oyama T, Yoshii A, Sato T, et al. Kimura's disease associated with bronchial asthma presenting eosinophilia and hyperimmunoglobulinemia E which were attenuated by suplatast tosilate (IPD-1151T). *Internal medicine.* 1998;37(12):1064-7.
 30. Ito S, Kume H, Kimura T, Yoshida N, Mizutani H, Ito Y, Suzuki R, Yamaki K. Two cases of Kimura's disease associated with bronchial asthma. *Nihon Kokyuki Gakkai zasshi= J Japanese Respiratory Society.* 1999;37(12):1008-12.
 31. Sugaya M, Suzuki T, Asahina A, Nakamura K, Ohtsuki M, Tamaki K. Kimura's disease associated with ulcerative colitis: detection of IL-5 mRNA expression of peripheral blood mononuclear cells and colon lesion. *ACTA Dermatovenereologica-Stockholm.* 1998;78:375-7.
 32. Horie S, Ishiyama T, Sugimoto M, Okada T, Hashimoto H, Wakabayashi Y, et al. Eosinophilic lymphofolliculosis (Kimura's disease) complicated with aortitis syndrome. [Rinsho ketsueki] *Japanese J clinical hematology.* 1989;30(3):396-9.

Cite this article as: Laxma RS, Bhaskar K, Vara PK, Paramjyothi GK. A rare association of Kimura's disease with chronic pulmonary aspergillosis. *Int J Res Med Sci* 2018;6:1821-4.