

## Case Report

# A safe method for the retrieval of a dislocated trial head in total hip arthroplasty

Satish B. Janipireddy\*, Sanjay Sinha, David W. Ferguson, Henry D. Atkinson

Department of Trauma and Orthopedic Surgery, North Middlesex University Hospital, London, UK

**Received:** 06 April 2017

**Revised:** 26 April 2017

**Accepted:** 03 May 2017

### \*Correspondence:

Dr. Satish B. Janipireddy,

E-mail: [satishbabu74@yahoo.com](mailto:satishbabu74@yahoo.com)

**Copyright:** © the author(s), publisher and licensee Medip Academy. This is an open-access article distributed under the terms of the Creative Commons Attribution Non-Commercial License, which permits unrestricted non-commercial use, distribution, and reproduction in any medium, provided the original work is properly cited.

### ABSTRACT

Total hip arthroplasty is a life changing procedure providing a significant improvement in the quality of life for those receiving treatment. An 81-year-old male with severe right sided hip osteoarthritis underwent uncemented total hip arthroplasty. Intraoperatively the 32mm trial head dislodged from the trial stem over the anterior rim of the acetabulum relocating to within the pelvic cavity. Time efficient retrieval was performed during primary surgery through a mini-incision at the iliac crest.

**Keywords:** Femoral head trial, Intraoperative complication, Retrieval, Trial head dislocation, Uncemented total hip replacement

## INTRODUCTION

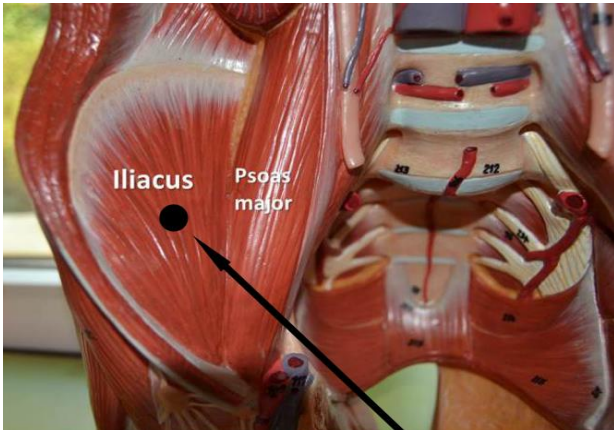
Total hip arthroplasty is a life changing procedure providing a significant improvement in the quality of life for those receiving treatment.<sup>1</sup> To achieve these results there are important intra-operative and post-operative complications that patients and surgeons must both accept and work together to minimise. Important post-operative complications are venous thromboembolic disease, joint instability, leg length discrepancy and periprosthetic fractures and can be managed through the combined efforts of the orthopaedic multidisciplinary team approach.<sup>2</sup> Reduction of trial prosthesis is an important intraoperative step relying heavily on surgical skill and must be performed correctly to minimise post-operative instability and leg length discrepancies. The process of reduction is one of the most critical intraoperative steps with the propensity to test even the most experienced surgeon. We report the rare occurrence of femoral head dislocation during trialling and offer our novel technique of trial head retrieval.

## CASE REPORT

An 81-year-old male with severe osteoarthritis of the right hip joint underwent uncemented total hip arthroplasty. Five years previously he had successful laparoscopic right-sided resection for colon carcinoma and was in remission. He was otherwise fit and well. The DePuy CORAIL hip system was used. Once the patient was under general anaesthetic the hip was accessed through a lateral approach as described by Hardinge.<sup>3</sup>

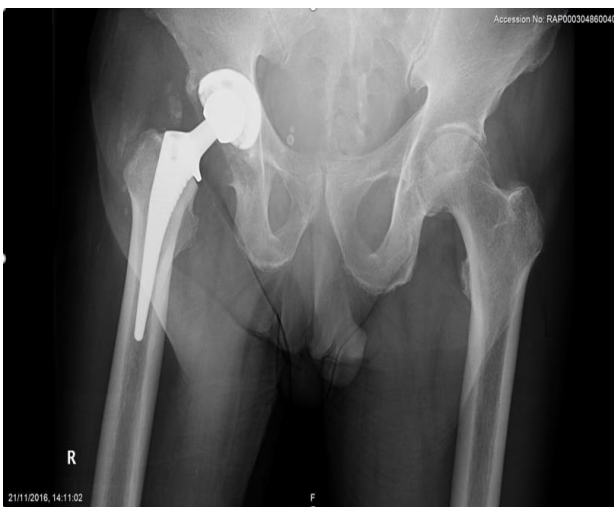Osteophytes were noted at the anterior and inferior acetabular rim and were excised using an osteotome and diathermy. A 52-32mm polyethylene liner was inserted into a PINNACLE acetabular shell. The trial was prepared with 12mm femoral rasp with standard neck and 32mm +5mm head. During attempted reduction, the trial head dislocated from the neck and fell anteriorly to the acetabular wall down into the pelvis resting as depicted in Figure 1. The trial head was initially easily palpable but after repeated attempts at removal it migrated further into

the pelvis. It could be identified with an extended finger against iliacus but concerted efforts to remove it with Lahey forceps and a scoop were unsuccessful.



**Figure 1: Resting position of trial head.<sup>4</sup>**

A separate incision of 60-70mm was made 50mm proximal to the anterior superior iliac spine. Utilizing a similar approach to that for iliac crest grafting or the medial part of the 1st window of an ilioinguinal approach the fascia was elevated over the inner table of the iliac crest ensuring no perforation into the peritoneum. At this point the lateral part of the iliacus was well visualised. After palpating the trial head against the inner table of the ilium it was easily extracted with a blunt haemostat. The whole exploration with incision to retrieval took less than 10 minutes. The wound was thoroughly washed and closed in layers of fascia, subcutaneous tissue and skin. The THA was subsequently completed with a 12mm collared standard neck on CORAIL femoral stem. Atrial 32mm +5 mm head was used again and reduced with the utmost caution. Stability checks were satisfactory and the remainder of the procedure was completed uneventfully. Figure 2 shows the radiograph of the total hip arthroplasty in situ.



**Figure 2: Post-operative radiographs.**

The patient made good post-operative recovery on the ward and was informed of the intra operative complications at the earliest opportunity. The both incisions healed well with no complications and the patient was followed up in clinic with excellent recovery.

## DISCUSSION

Total hip arthroplasty (THA) is routinely performed surgery with good success and outcomes and a steep learning curve since its evolution.<sup>5,6</sup> Around 80 000 primary THAs are performed in England and Wales each year with numbers rising.<sup>7</sup> Various complications have been described with a few case reports of a dislocated trial head into the pelvis while performing a contemporary hip replacement described in the literature.<sup>8-15</sup>

There are also case reports of dual mobility bearing surface dislocations.<sup>16,17</sup> This complication can cause concerns for patient safety with increased risk of infection whilst also being deeply frustrating for the operating surgeon.<sup>14</sup> Methods of retrieval through a same or separate incision and during a separate procedure have also been described.<sup>9,10,14,18,19</sup> The trial head can be left in the pelvis if not causing any obstructive symptoms.<sup>12</sup> However, retrieval may be necessary due to the risk of later complications and infection.<sup>13,14</sup> We describe a case similar to the ones in the literature, but with a novel safe and easy way of removal of the dislocated head at the time of primary surgery utilising an approach a general orthopaedic surgeon and resident would be familiar with.

Iliacus muscle originates in the iliac fossa on the inside of the pelvis with insertion at the lesser trochanter along with the tendon of psoas as shown in Figure 1. The safest approach for harvesting an iliac crest graft is by an incision parallel to the superior cluneal nerves and perpendicular to the posterior iliac crest.<sup>20</sup> We used a similar incision to safely remove the head in a timely manner and to minimise the potentially serious sequelae from this complication.

## CONCLUSION

Trial head dislocation is a rare complication in total hip arthroplasty. Conservative management by leaving the head within the cavity has been described previously but has associated risks of infection, discomfort and obstruction. Head retrieval at a second separate operation has also been described with the associated risks of repeat surgery. The novel approach we describe serves as a safe, practical and swift method of retrieval at the time of primary surgery through an approach familiar to the majority of orthopaedic surgeons.

*Funding: No funding sources*

*Conflict of interest: None declared*

*Ethical approval: Not required*

## REFERENCES

1. Mariconda M, Galasso O, Costa GG, Recano P, Cerbasi S. Quality of life and functionality after total hip arthroplasty: a long-term follow-up study. *BMC Musculoskeletal Disorders.* 2011;12(1):222.
2. Schwarzkopf, R. Modern techniques in total hip arthroplasty: from primary to complex. Jaypee Brothers Medical P, 2014.
3. Petis S, Howard JL, Lanting BL, Vasarhelyi EM. Surgical approach in primary total hip arthroplasty: anatomy, technique and clinical outcomes. *Can J Surg.* 2015;58:128-39.
4. Yucel K, Gergin S. Iliacus and psoas major. Yeditepe anatomy lab (2017). Available at: <https://yeditepeanatomy.wordpress.com/2014/04/25/abdominal-muscles-lumbosacral-plexus-gluteal-region/>. (Accessed: 4th April 2017)
5. Hip and Knee Replacement Surgery FAQs- Available from: [https://www.hss.edu/conditions\\_advancements-hip-knee-replacement-surgery.asp](https://www.hss.edu/conditions_advancements-hip-knee-replacement-surgery.asp)
6. Learmonth ID, Young C, Rorabeck C. The operation of the century: total hip replacement. *Lancet.* 2007;370:1508-19.
7. 13th Annual Report National Joint Registry for England, Wales, Northern Ireland and the Isle of Man. 2016.
8. Ziv Y, Backstein D, Safir O, Kosashvili Y. Intraoperative dislocation of a trial femoral head into the pelvis during total hip arthroplasty. *Can J Surg.* 2008;51:E73-4.
9. Rachbauer F, Nogler M, Krismer M, Moritz M. Intraoperative migration of the trial femoral head into the pelvis during total hip arthroplasty: prevention and retrieval. *J Bone Joint Surg Am.* 2002;84-A,881-2; author reply 882 (2002).
10. Princep, A. Intraoperative migration of the trial femoral head into the pelvis during total hip arthroplasty: prevention and retrieval. *J Bone Joint Surg Am.* 2002;84-A,880-1; author reply 881.
11. Langlois J, El Hage S, Hamadouche M. Intraprosthetic dislocation: a potentially serious complication of dual mobility acetabular cups. *Skeletal Radiol.* 2014;43:1013-6.
12. Ikeuchi K, Hasegawa Y, Warashina H, Seki T. Intraoperative migration of the trial femoral head into the pelvis during total hip arthroplasty- report of two cases. *Nagoya J Med Sci.* 2014;76:203-10.
13. Callaghan JJ, McAndrew C, Boese CK, Forest E. Intrapelvic migration of the trial femoral head during total hip arthroplasty: is retrieval necessary? A report of four cases. *Iowa Orthop J.* 2006;26:60-2.
14. Bicanic G, Crnogaca K, Simunovic M, Delimar D. Dislocated trial femoral head during total hip arthroplasty: review of the literature and the new algorithm for treatment. *BMJ Case Rep.* 2015;2015:bcr2014208693.
15. Batouk O, Gilbert M, Jain R. Intraoperative Dislocation of the Trial Femoral Head into the Pelvis During Total Hip Arthroplasty: A Case Report. *J Bone Jt Surg Am.* 2001;83:1549-51.
16. Banka TR, Ast MP, Parks ML. Early Intraprosthetic Dislocation in a Revision Dual-mobility Hip Prosthesis. *Orthopedics.* 2014;37:e395-7.
17. Fehring KA, Berry DJ. Dissociation and Intrapelvic Entrapment of a Dual-mobility Polyethylene Component. *Clin Orthop Relat Res.* 2016;474:1072-6.
18. Alfonso D, Idjadi J, Lamont JG. Retrieval of a Trial Femoral Head That Displaces into the Periacetabular Soft Tissue During Mini-Incision Total Hip Arthroplasty: A Case Report. *J Bone Jt Surg.* 2006;88:866-8.
19. Madsen WY, Mitchell BS, Kates SL. Successful intraoperative retrieval of dislocated femoral trial head during total hip arthroplasty. *J Arthroplasty.* 2012;27:820.e9-11.
20. Colterjohn NR, Bednar DA. Procurement of bone graft from the iliac crest. An operative approach with decreased morbidity. *J Bone Joint Surg Am.* 1997;79:756-9.

**Cite this article as:** Janipireddy SB, Sinha S, Ferguson DW, Atkinson HD. A safe method for the retrieval of a dislocated trial head in total hip arthroplasty. *Int J Res Med Sci* 2017;5:2824-6.