

Original Research Article

Multi detector computed tomography imaging in penetrating injuries

Namrita Sachdev*, Yashvant Singh, Sana, Dipshi Mehta

Department of Radiodiagnosis, Atal Bihari Vajpayee Institute of Medical Sciences and Dr. Ram Manohar Lohia Hospital, New Delhi, India

Received: 14 April 2020

Accepted: 05 May 2020

***Correspondence:**

Dr. Namrita Sachdev,

E-mail: namritasach@rediffmail.com

Copyright: © the author(s), publisher and licensee Medip Academy. This is an open-access article distributed under the terms of the Creative Commons Attribution Non-Commercial License, which permits unrestricted non-commercial use, distribution, and reproduction in any medium, provided the original work is properly cited.

ABSTRACT

Background: Penetrating injuries forms an important component of surgical emergencies. Penetrating trauma typically involves the violation of the body by a gunshot wound (GSW) or stab wound. Emergency laparotomy is the accepted management in patients with a penetrating injury who are not hemodynamically stable. However, selective non-operative management has been shown to decrease the rate of unnecessary surgery. Plain radiographs and FAST are useful for initial assessment of these patients. Multi detector CT is an indispensable tool in the evaluation of patients who are stable and are candidates for conservative treatment.

Methods: A cross sectional observational study was carried out on 40 patients admitted with penetrating injury to the trauma centre of PGIMER and Dr RML hospital. Of the 40 patients, 14 were taken for emergency laparotomy. In 26 cases, MDCT was done to evaluate for solid organ, hollow organ and vascular injuries.

Results: The mean age of patients was 38 years, with male to female ratio of 5:1. Stab injury was the commonest type of injury, followed by gunshot wounds. Liver was the commonest solid organ involved, followed by kidneys and spleen. Other organs involved were diaphragm, small bowel and colon.

Conclusions: Penetrating injuries can be life-threatening, making prompt diagnosis essential. Recognizing key abnormalities on MDCT ensures patients are triaged appropriately. Multi-detector CT is thus widely used to evaluate penetrating injuries in stable patients.

Keywords: Gunshot wounds, Multi detector computed tomography, Penetrating injury, Stab injury

INTRODUCTION

Penetrating injuries form an important component of surgical emergencies. Penetrating trauma typically involves the violation of the body by a gunshot wound (GSW) or stab wound. Emergency laparotomy is the accepted management in patients with a penetrating injury who are not hemodynamically stable and have a clinical indication for exploratory laparotomy. However, selective non-operative management of both stab wounds and gunshot injuries is considered safe and has been shown to decrease the rate of unnecessary laparotomy with its complications, length of hospital stays, and management costs.¹

Plain radiographs and ultrasound are useful for initial assessment of these patients with focused assessment with sonography in trauma (FAST) examination becoming a standard part of the diagnostic algorithm of all trauma cases. MDCT is an indispensable tool in the evaluation of patients who are hemodynamically stable with no clinical indication for exploratory laparotomy and are, therefore, considered candidates for conservative treatment.² In the present study we discuss the types and pathophysiology of penetrating traumatic injuries and review important considerations when interpreting MDCT findings so as to improve detection of such injuries.

METHODS

A cross sectional observational study was carried out on 40 patients admitted with penetrating injury to the trauma centre of PGIMER and Dr RML hospital from November 2016 to April 2018. Of the 40 patients, 14 were taken for emergency laparotomy. In 26 cases who were hemodynamically stable, MDCT was done to triage and evaluate for type of injury.

Inclusion criteria

- Hemodynamically stable patients of penetrating injury kept for conservative management of all age groups and either sex.

Exclusion criteria

- Patients of penetrating injury taken for emergency laparotomy in the following conditions: shock, evisceration, peritonitis, GI bleeding.

CT evaluation

Patients were evaluated on 128 slice Seimens Somatom scanner. Triple phase CT was done using nonionic contrast medium. Oral contrast was not given however rectal contrast was used to assess patient of suspected rectal injury.

Statistical analysis

All the data collected was entered compiled and analyzed using version 22.0 of the statistical package for social sciences software package (SPSS).

RESULTS

Of the 40 patients of penetrating injury, 14 patients (35%) were taken for emergency laparotomy. The total number of patients evaluated by MDCT was 26, with 22 male and 4 female patients (Male: Female ratio 5:1). The youngest patient was 5 years and the oldest 63 years, with mean age of 38 years. Stab injury was the commonest type of injury, seen in 19 patients (73%), followed by gunshot wounds seen in 5 patients (20%). There was 1 patient each of road traffic accident and bull gore injury (4%). Liver was the commonest solid organ involved, seen in 9 patients (34%). There were 4 patients each with grade III injury and grade IV injury and one case of active bleeding from right hepatic artery. There was contiguous lung contusion in 1 patient of hepatic laceration, with indirect evidence of diaphragmatic injury. Spleen was involved in 6 patients (23%) with evidence of laceration and hematoma. There was 1 patient with evidence of active bleeding from splenic artery. Kidney was involved in 5 patients (20%). Small bowel and colon were involved in 3 and 2 patients respectively. There was 1 case of isolated pancreatic injury with evidence of transection of pancreas. Amongst the vascular injuries, 2

cases of active bleeding were seen involving right hepatic and splenic artery each. There was 1 case of retroperitoneal hematoma and 1 case of traumatic pseudoaneurysm involving left peroneal artery following stab injury to leg.

DISCUSSION

Classification and pathophysiology of Penetrating trauma: Stab wounds versus gunshot wounds

Stab wounds were the commonest mode of penetrating injury. Knives are not the sole instruments used in stabbing. Ice picks, pens, coat hangers and broken bottles are also used in this type of injuries. Peritoneal disruption is less common than gunshot injuries but is still seen in 50-75% of cases. The injuries are more predictable as they follow a track. Stab wounds are considered low-energy injuries as compared to GSW.

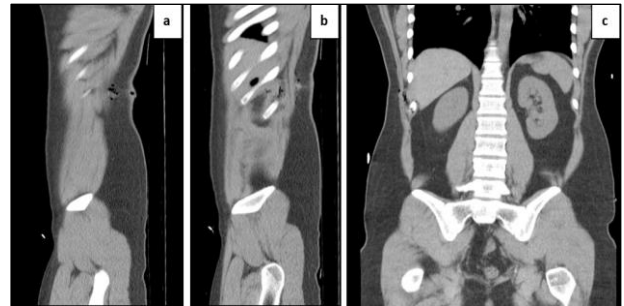

Figure 1: (a, b, c) Stab wound right flank with no peritoneal disruption: CT sagittal and coronal of knife wound track with discontinuous foci of gas used to identify a knife track.

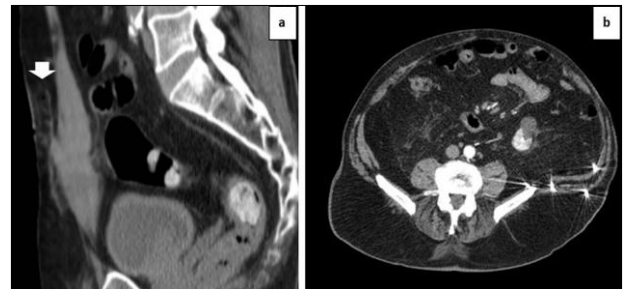

Figure 2: Stab injury lower abdominal wall. a) Pelvic CT Sagittal with indurated track and wall haematoma. b) Axial CT of multiple bullet injury with pellets impacted in left flank.

Gushot wounds are more unpredictable injuries as there is no definite track and are often multiple in number. Peritoneal involvement is commonly seen in nearly 90% of cases. It is important to understand the mechanism by which these injuries cause damage which is the result of a complex interaction of multiple factors, including type of firearm with mass, velocity and path of bullet as well as the type of organ injured.³

Types of firearms can be rifles which have the highest velocity followed by handguns with medium to low velocity and shotguns which have a cartridge of pellets. As a bullet penetrates tissue and moves through the body it creates a permanent cavity which is the zone of laceration and contusion lining the bullet track. The density of tissues in the path of the bullet affects the injury pattern with more damage in tissues with a higher density. Thus, skin and lung tissue, which have low density, undergo less damage than the liver, spleen, and muscle, which have higher density.⁴

Goal of management and role of imaging

The goal of management is to identify patients requiring immediate surgical intervention with laparotomy indicated for patients with shock, evisceration, peritonitis and GI bleeding.⁴ The decision between mandatory laparotomy and selective non operative management depends on not just the hemodynamic status of the patient but also the mechanism and location of injury as well as associated injuries. Imaging evaluation starts with a plain X-ray and ultrasound exam. Common findings seen in a plain radiograph include free abdominal air (pneumoperitoneum), pneumothorax, and hemothorax. In the case of gunshot wounds, X-rays identify the location and number of retained projectiles. FAST assesses for the presence of free fluid in the abdomen. However, its utility in penetrating injuries is limited with low sensitivity.

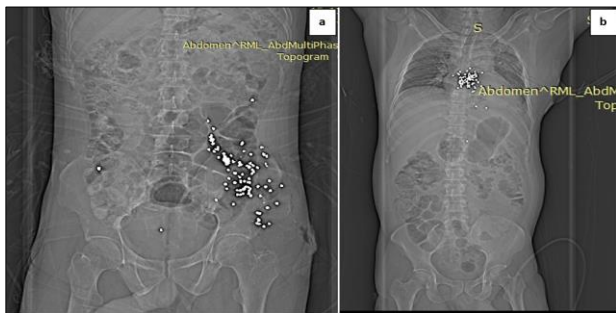

Figure 3: a) and b) Abdominal and thoracoabdominal bullet injury in two different patients: plain radiograph localises number and position of projectiles.

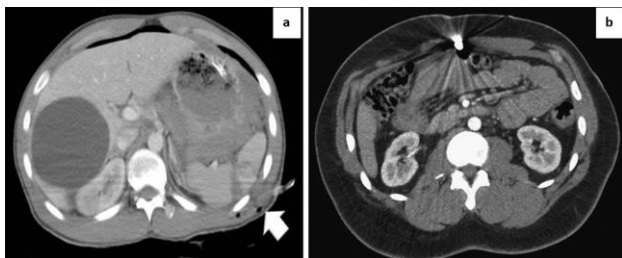


Figure 4: a) Left flank stab injury: axial CT demonstrates wound path analysis with splenic laceration and hemoperitoneum. b) Bullet injury anterior abdomen: axial CT line of possible injuries.

Radiological evaluation by CT is an indispensable tool in the triage of hemodynamically stable patients. Multiple studies have reported that contrast enhanced CT adequately depicts penetrating torso trauma with sensitivity and specificity greater than 95%.^{5,6} The location of injury maybe thoracoabdominal, back, flank and pelvis which determines the indication for CT. The specific indications for CT imaging are tangential or superficial wounds to exclude peritoneal penetration, thoracoabdominal or anterior abdominal wounds to assess for solid organ injury, major vascular injury and diaphragmatic injury. Trans-pelvic gunshot wounds for rectal and bladder injury to assess for intraperitoneal versus extraperitoneal rupture. Back and flank injuries for involvement of retroperitoneal structures like kidney, ureter, colon and vascular injuries. In MDCT use of 3D reconstructions and multiplanar reformats is essential to improve diagnostic yield.

Wound path analysis or CT trajectography is another method that aids in diagnosis by analyzing the path of wound to search for injured organs and structures on CT. CT trajectography involves placing a cross-cursor on the point of entry and swiveling the cut planes obliquely in orthogonal planes to obtain a “double oblique” orientation in which the wound track is visualized in profile.⁷

Lesional spectrum on MDCT

Solid organ injuries

The three most common types of parenchymal solid-organ injuries seen at CT are lacerations, hematomas, and active extravasation. Lacerations are seen as an area of linear hypoattenuation. Acute hematomas appear as an area of hypoattenuation relative to the uninjured, enhancing parenchyma. Subcapsular hematomas are seen as a crescent-shaped low-attenuation fluid accumulation outlining the convexity or flattening the contours of a solid organ. The liver is the most frequently injured intraperitoneal solid organ in patients with penetrating trauma to the torso.⁸ This study corroborated the same.

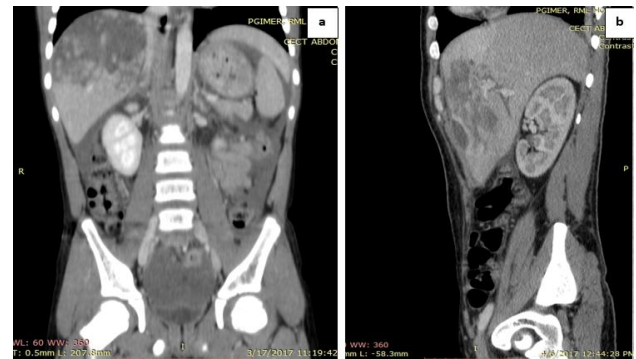

Figure 5: a) and b) Coronal and sagittal reformatted CT of extensive hepatic laceration with hemoperitoneum.

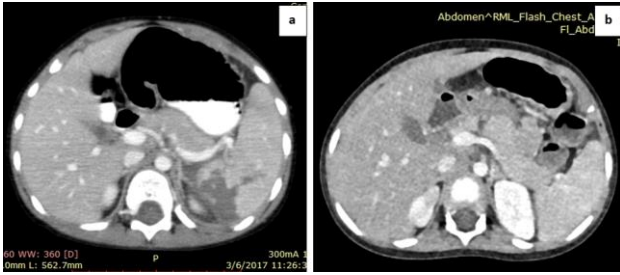


Figure 6: a) Axial CT of splenic laceration. b) Another patient with traumatic transection of pancreas.

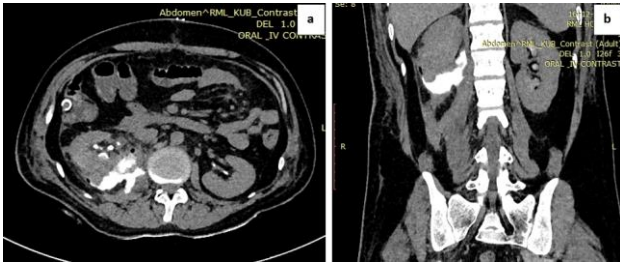


Figure 7: a) and b) Stab injury right flank: Axial and coronal reformatted CT in delayed phase diffusion of extravasated material into retroperitoneum.

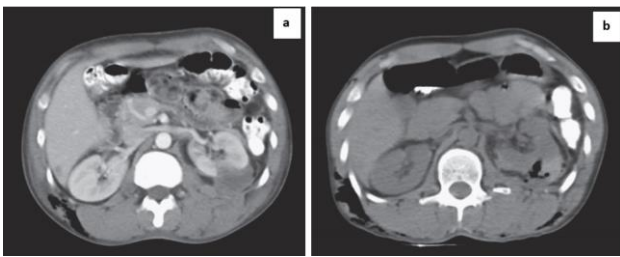


Figure 8: a) and b) Stab injury left flank: axial plain and contrast CT demonstrates renal laceration with perinephric haematoma and air in subcutaneous tissues.

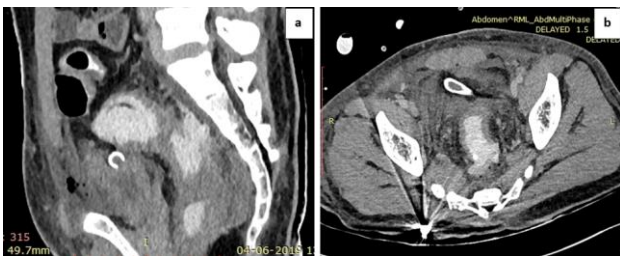


Figure 9: a) and b) Gunshot injury lower back with impacted bullet shows rectal injury: axial and sagittal reformatted CT of rectal wall discontinuity posteriorly with leakage of rectal contrast into the POD.

Pancreatic injury is seen as localized collection of bile or pancreatic fluid in lesser sac or subhepatic space. Transection of pancreas is best seen in late arterial/early portal venous phase. Amongst solid organs isolated renal

injury may occur. These appear as laceration, subcapsular hemorrhage and perinephric hematoma. High grade renal trauma can be associated with urinary extravasation and formation of a urinoma.

Pneumoperitoneum indicates peritoneal violation but presence of extra-luminal air remote from injury trajectory should raise suspicion in small bowel and colonic injury. Direct signs of bowel injury on CT are bowel discontinuity, wound track extending to bowel, oral or rectal contrast extravasation and mesenteric haematoma.⁹

Diaphragmatic injury

Establishing a diagnosis of a penetrating diaphragmatic injury is difficult because most injuries are small and subtle.¹⁰ Injuries to the diaphragm do not produce overt symptoms therefore, diaphragmatic injury should be suspected when injuries to adjacent organs are encountered. One of the most accurate signs of a penetrating diaphragmatic injury is focal disruption along the wound tract or a wound trajectory that crosses the diaphragm. Another important sign is the “collar” sign, in which focal constriction of part of a bowel or mesenteric fat partially herniates into the thorax.¹¹ The “contiguous injury” sign, defined as evidence of injury-either focal or diffuse-along both sides of the diaphragm, is sensitive for diaphragmatic injury.

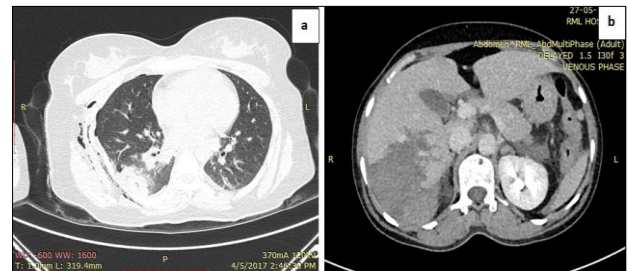


Figure 10: a) and b) Injury to right thoracoabdominal region with surgical emphysema, lung contusion with large liver laceration contiguous injury sign suggestive of diaphragmatic injury.

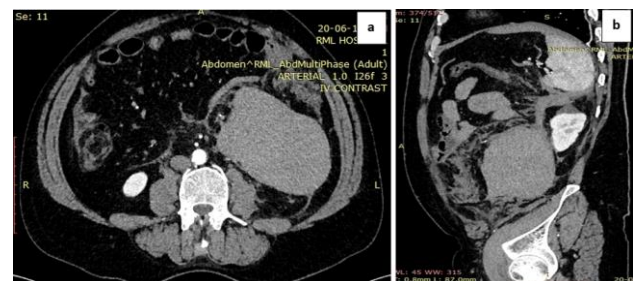


Figure 11: a) and b) Patient with stab injury right flank: axial and sagittal CT of a large retroperitoneal haematoma in right pararenal space displacing descending colon.

Vascular injuries

Direct signs of vascular injury are considered diagnostic and include active bleeding, pseudoaneurysm, and post-traumatic arteriovenous fistula. Active bleeding requires urgent surgical or endovascular intervention. Pseudoaneurysms are formed when arterial wall is disrupted and blood leaks into surrounding tissues. These may undergo spontaneous thrombosis or rupture and can compress surrounding structures. Post traumatic arteriovenous fistula is an abnormal communication between artery and adjacent vein which appears as early opacification of vein on CT. Hematomas can be seen in penetrating injuries.¹² Retroperitoneal hematomas can result from small retroperitoneal branch or tributary haemorrhage, paraspinous or body wall musculofascial bleeding or solid organ laceration which do not require surgery.

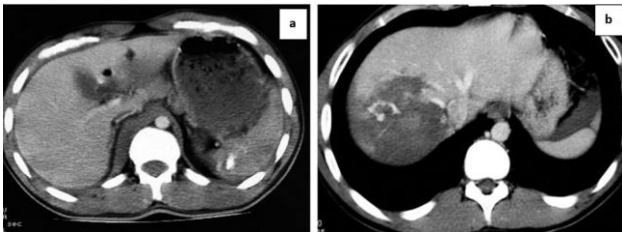


Figure 12: a) and b) Traumatic vascular injury: Splenic artery and hepatic artery in two different patients with active bleeding visible as a bright white “blush” or amorphous collection of contrast on arterial phase.

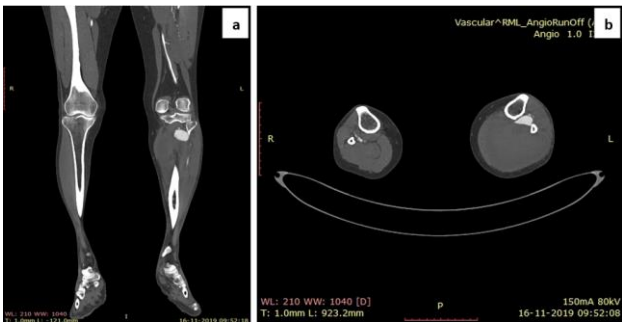


Figure 13: a) and b) Stab injury left leg: CT angiography of a pseudoaneurysm of peroneal artery with a large haematoma posteriorly.

MDCT plays an indispensable role in penetrating injuries by recommending stable patients for non-operative management. CT has 94% sensitivity 95% specificity 95% accuracy in predicting need for laparotomy.¹³ CT Trajectory evaluation has led to a focused time saving approach to diagnose organ specific injuries especially to small bowel, rectum and diaphragm.¹³ CT findings that require surgical or endovascular management are solid organ injury with active arterial extravasation, diaphragmatic injury, bowel and mesenteric injuries,

major vascular injuries and intraperitoneal bladder rupture.¹⁴

Funding: No funding sources

Conflict of interest: None declared

Ethical approval: The study was approved by the Institutional Ethics Committee

REFERENCES

1. Inaba K, Demetriades D. The nonoperative management of penetrating abdominal trauma. *Adv Surg.* 2007;41:51-62.
2. Demetriades D, Velmahos GC. Indications for and techniques of laparotomy. In: Feliciano DV, Mattox KL, Moore EE, eds. *Trauma*, 6th ed. New York, NY: McGraw-Hill; 2008:607-622.
3. Jenkins D, Dougherty P. The effects of bullets. In: Mahoney PF, Ryan JM, Brooks AJ, Schwab CW, eds. *Ballistic trauma*. London, England: Springer; 2005:40-44.
4. Stapley SA, Cannon LB. An overview of the pathophysiology of gunshot and blast injury with resuscitation guidelines. *Curr Orthop.* 2006;20(5):322-32.
5. Conrad MF, Patton JH, Parikshak M, Kralovich KA. Selective management of penetrating truncal injuries: is emergency department discharge a reasonable goal? *Am Surg.* 2003;69(3):266-72.
6. Mitra B, Goentzas R, O'Reilly G, Cameron PA, Atkin C. Management of haemodynamically stable patients with abdominal stab wounds. *Emerg Med Australas.* 2007;19(3):269-75.
7. Folio LR, Fischer TV, Shogan PJ, Frew MI, Kang PS, Bunger R, et al. CT based ballistic wound path identification and trajectory analysis in anatomic ballistic phantoms. *Radiol.* 2011;258(3):923-9.
8. Demetriades D, Hadjizacharia P, Constantinou C, Brown C, Inaba K, Rhee P, et al. Selective nonoperative management of penetrating abdominal solid organ injuries. *Ann Surg.* 2006;244(4):620-8.
9. Bondia JM, Anderson SW, Rhea JT, Soto JA. Imaging colorectal trauma using 64-MDCT technology. *Emerg Radiol.* 2009;16(6):433-40.
10. Murray JA, Demetriades D, Asensio JA, Cornwell III EE, Velmahos GC, Belzberg H, et al. Occult injuries to the diaphragm: prospective evaluation of laparoscopy in penetrating injuries to the left lower chest. *J Am Coll Surg.* 1998;187(6):626-30.
11. Murray JA, Demetriades D, Cornwell EE, Asensio JA, Velmahos G, Belzberg H, et al. Penetrating left thoracoabdominal trauma: the incidence and clinical presentation of diaphragm injuries. *J Trauma.* 1997;43(4):624-6.
12. Shanmuganthan K, Scalea TM. Imaging of penetrating trauma of the torso and chest. In: Mirvis SE, Shanmuganathan K, eds. *Imaging in trauma and critical care*. 2nd ed. Philadelphia, Pa: Saunders; 2003:633-696.

13. Goodman CS, Hur JY, Adajar MA, Coulam CH. How well does CT predict the need for laparotomy in hemodynamically stable patients with penetrating abdominal injury? A review and meta-analysis. *Am J Roentgenol.* 2009;193(2):432-7.
14. Lozano JD, Munera F, Anderson SW, Soto JA, Menias CO, Caban KM. Penetrating wounds to the torso: evaluation with triple contrast multidetector CT. *Radio Graphics.* 2013;33(2):341-59.

Cite this article as: Sachdev N, Singh Y, Sana, Mehta D. Multi detector computed tomography imaging in penetrating injuries. *Int J Res Med Sci* 2020;8:2259-64.