

Case Report

A case report of microscopic polyangiitis presenting as diffuse pulmonary symptoms with no renal involvement

Shreyans D. Singhvi*, Preksha Singh, Rafe Khan, Monila Patel, Pavan Acharya

Department of Internal Medicine, Sardar Vallabhbhai Patel Institute of Medical Sciences and Research, Ahmedabad, Gujarat, India

Received: 12 February 2020

Revised: 17 February 2020

Accepted: 04 March 2020

*Correspondence:

Dr. Shreyans D. Singhvi,

E-mail: shreyanssinghvi4@gmail.com

Copyright: © the author(s), publisher and licensee Medip Academy. This is an open-access article distributed under the terms of the Creative Commons Attribution Non-Commercial License, which permits unrestricted non-commercial use, distribution, and reproduction in any medium, provided the original work is properly cited.

ABSTRACT

Microscopic polyangiitis (MPA) is a small blood vascular disorder, but with presence of no granulomas. This is a pauci-immune disorder vessels which lead to vascular inflammation and then later, it can lead to organ microscopic polyangiitis. This disorder affects multiple organs as it is a systemic disease, but usually presents with renal dysfunction - rapidly progressive glomerulonephritis. There is a possible association of p- ANCA (antineutrophil cytoplasmic antibodies) and can help with the diagnosis of the disorder. This case report is of a 70-year-old female, who presented with symptoms of diffuse pulmonary hemorrhage. After routine blood examination, radiological examination- X ray (chest) and HRCT- thorax, routine urine examination, ANA and ANCA test, the final diagnosis of microscopic polyangiitis with no renal involvement was made. The case was given immunosuppressant therapy and the patient reported of mitigation of symptoms. This case report is unique as MPA usually presents with renal dysfunction, but in this case, the patient had particularly pulmonary involvement with completely normal renal function. This case report will help future physicians for quick diagnosis of similar cases and treatment for the same.

Keywords: Case report, Microscopic, Polyangiitis, Pulmonary

INTRODUCTION

Microscopic Polyangiitis (MPA) is a systemic pauci-immune necrotizing vasculitis of small blood vessels characterized by the absence of granulomas.¹ MPA is an autoimmune disease but its etiology remains unknown, which demands extensive research about the disorder. MPA is associated with presence of antineutrophil cytoplasmic autoantibodies (ANCA) but not all patients with MPA have ANCA, yet ANCA'S are considered as pathognomonic feature of MPA.¹ Although, there is imminent evidence that not all ANCA are pathogenetic, there are several epitopes of ANCA, which might determine their pathogenicity individually.¹ Since, it is known that MPA is a systemic disorder, multiple organs could be affected that could lead to

differentiating features between each case of MPA with different signs and symptoms. The kidneys are most commonly affected in MPA, it has a poor prognosis if not treated but the use of aggressive immunosuppressive treatment has improved the prognosis and the patient's survival.¹ Since the disorder is most commonly associated with kidney organ dysfunction, Interestingly, kidney transplantation is safe and effective and it has a good prognosis in MPA patients.¹ The main clinical presentation in MPA is rapidly progressive glomerulonephritis (RPGN) characterized by rapid decrease of glomerular filtration rate (GFR), microscopic hematuria, erythrocyte cast, presence of proteinuria (usually less than 3g) and hypertension.¹ Males are commonly found to be affected by the disorder than females. The incidence of MPA is 2,7 to 94 per 1 million

with a slight male predominance.² An increased incidence has been reported especially in southern Europe as well.³

CASE HISTORY

A 70-year-old woman presented to a tertiary care hospital in Ahmedabad, Gujarat, India with chief complaints of cough with mucopurulent sputum since the past 15 days, hemoptysis since the past 8 days and shortness of breath since 1 day. She was admitted to the hospital on the same day.

The general physical examination was performed. She was well alert and oriented to time, place and person. Her vitals were taken which recorded a pulse rate of 76/min in the right radial artery. She was afebrile and her Blood Pressure recorded was 116/74 mmHg. Her respiratory examination revealed abnormal respiratory sounds - extensive crackles in bilateral lungs. Her past history described hypothyroidism since the past 10 years, but she was not on any medication for it since the past 4 months.

Her laboratory investigations are as follows-

- Hemoglobin (hb): 7.88mg/dl (normal range: 12.0-15.5 mg/dl),
- No eosinophilia seen,
- Total leucocyte count: 15,400/mm³ (normal range- 3600-11,200/mm³),
- Erythrocyte sedimentation rate (ESR): 120mm/hr. (normal: <20 mm/hr),
- Platelets count- 6.19 lakh/cumm, (normal range : 1.7 lakh/cumm- 3.0 lakh/cumm),
- blood sodium level sodium: 136mEq/L (normal range: 135-145 mEq/L),
- blood urea nitrogen (BUN)- 36mg/dl, (normal range for age : 14-23mg/dl),
- blood potassium - 4.5 mmol/L (normal range: 3.6 - 5.2 mmol/L),
- serum creatinine- 0.55 mg/dl,
- C-reactive protein- 139.19mg/L (normal range- <3.0 mg/l),
- Thyroid stimulating hormone- 57.62 microIU/ml (normal range - 0.4- 40microIU/ml),
- Anti- thyroid peroxidase antibody- 62.96 IU/ml (normal range - <35 IU/ml),
- prothrombin time (PT)- 14.7 seconds,
- International normalized ratio (INR)- 1.24 seconds.

Arterial blood gas analysis (ABGA) was performed- the following are the results - partial pressure of oxygen (paO₂)- 49.1mmHg, partial pressure of carbon dioxide (paCO₂)- 28.6 mmHg, pH- 7.48 and oxygen saturation level - 81.01%. The patient was then administered oxygen at 4ml/ hour. Later her arterial blood gas analysis (ABGA) was performed again, which was as follows- partial pressure of oxygen (paO₂)- 130.1 mmHg, partial pressure of carbon dioxide (paCO₂)- 30.6mmHg, pH- 7.40, oxygen saturation level- 98.9%.

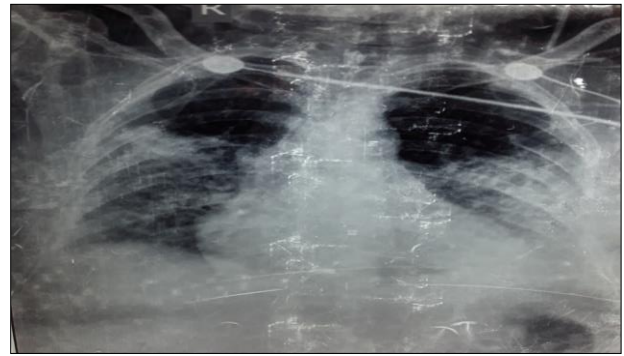


Figure 1: Radiological examination- Chest X ray- Postero-anterior view.

Furthermore, Radiological examination of the lung was performed- Chest X ray- Postero-anterior view which gave the following results- right middle zone consolidation and left lower zone consolidation (Figure 1). This helped further in the path of diagnosis and indicated a differential diagnosis of tuberculosis, pneumonia or an autoimmune pathology

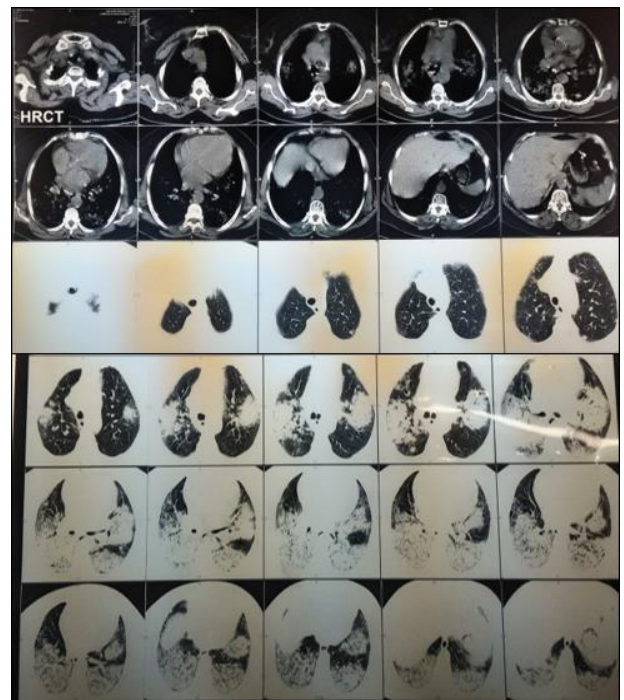


Figure 2: Radiological investigation - High resolution computed tomography (HRCT) - thorax.

For further diagnosis, 2 sputum samples were taken, the sample came back negative for acid fast bacilli (AFB) and the sputum culture had no growth of bacteria. This removed the differential diagnosis of tuberculosis from the spectrum.

Further, high resolution computed tomography (HRCT)- thorax was performed for diagnoses - it revealed high alveolar damage with pulmonary hemorrhage (Figure 2).

After the HRCT, Further additions to differential diagnosis were made after HRCT. These were- Granulomatosis with polyangiitis (GPA), microscopic polyangiitis (MPA), good pasture's syndrome (GPS) and systemic lupus erythematosus (SLE).

Since these systemic disorders usually present with renal organ involvement, routine urine examination was performed which was all within normal limits. Urinary examination of antinuclear antibodies (ANA) was performed which came back negative. Furthermore, test for detecting anti-neutrophil cytoplasmic antibody- (ANCA) was performed- which came back positive for p-ANCA or perinuclear anti-neutrophil cytoplasmic antibodies.

This test was performed in 1:10 dilution, Myeloperoxidase (MPO) specificity was confirmed by quantitative ELISA (enzyme linked immunosorbent assay). This helped to frame the diagnosis of microscopic polyangiitis.

The patient was given the following treatment- she was given combined immunosuppressive treatment for remission of the disorder. For Induction therapy the patient was given- Methylprednisolone 1mg/kg/day (tapered weekly) with cyclophosphamide 1g/15 days for 2 days. For maintenance therapy the patient was prescribed methylprednisolone 10mg/day for 12 months. At the end of 1 month of treatment, pulmonary symptoms improved markedly

DISCUSSION

Microscopic polyangiitis (MPA) is a small blood vascular disorder, but with presence of no granulomas. This is a pauci- immune disorder vessels which lead to vascular inflammation. MPA is a systemic multiple organ dysfunction, commonly affecting older adults. There are several risk factors associated with MPA, these include- Older age, female gender, serum creatinine level, kidney lesions and crescents as well response to treatment.

Microscopic polyangiitis (MPA) is a disorder that causes blood vessel inflammation (vasculitis), which can lead to organ Microscopic Polyangiitis.⁴ The term vasculitides refers to a group of inflammatory disorders involving any size or type of vessel. Microscopic Polyangiitis (MPA) is a systemic pauci-immune vasculitis of glomerular capillaries leading to necrotizing glomerulonephritis.⁵ Anti-neutrophil cytoplasmic antibodies (ANCA) are directed against enzymes in the granules of polymorphonuclear leukocytes and the major ANCA antigens are the myeloid enzymes myeloperoxidase (MPO) and proteinase 3.^{6,7} ANCA plays a role in both neutrophil activation and direct tissue injury in vitro, suggesting that ANCA is involved in the pathogenesis of systemic vascular disorders. The diagnosis is usually based on the present clinical symptoms as well as ANCAs detection but tissue biopsy- usually renal is considered the gold standard.

Since, MPA is a systemic disorder; it can affect multiple vessels and lead to difference signs and symptoms. The symptoms present according to the organ of the body which is affected. The most observed symptoms are- kidney inflammation, skin lesions like rashes, fevers, weight loss, nerve damage, lung dysfunction symptoms like- cough, hemoptysis, dyspnea, brain dysfunction symptoms like- pain, tingling, loss of sensory function and seizures.

Renal involvement occurs in the majority of the cases and it is manifested by microscopic hematuria, mild proteinuria, casts and deterioration of renal function due to rapidly progressive glomerulonephritis.⁸ Gastrointestinal manifestations consist of abdominal pain and bleeding. Peripheral neuropathy (mononeuritis-symmetrical polyneuropathy) is the predominant manifestation while involvement of the central nervous system has also been reported.⁸ Ear nose and throat manifestations are less frequent in MPA patients.⁸ Neurological involvement is common.⁹

Pulmonary lesions often accompany microscopic polyangiitis (MPA) and manifest in patients with MPO-ANCA. Pulmonary fibrosis was present in 36% of patients with MPA at the time of diagnosis.¹² A previous report demonstrated that chronic interstitial lesions are common histological features in patients with MPO-ANCA based on the pathologic reviews.^{11,12} Thus, pulmonary fibrosis is now a recognized manifestation of MPA.

Nada et al, reported three patients initially diagnosed with idiopathic pulmonary fibrosis (IPF) that developed pulmonary-renal vasculitis.¹³ MPA is a dreadful disease as it has poor prognosis but, it can be treated with aggressive immunosuppressive treatment. The choice treatment is based on the severity of the disease. Treatment strategies include induction therapy and maintenance therapy; this includes immunosuppressant therapies; cyclophosphamide with corticosteroids like methylprednisolone and for maintenance therapy only the corticosteroid like methylprednisolone or Azathioprine.

Rituximab is another drug that can be considered for the treatment of MPA, but as profound research is not done about long term safety use of the drug, it's safety is not confirmed, but in future it could be used as a potential line of treatment, if supplemented by future studies and clinical trials. In the patients with aggressive renal involvement and the pharmacological treatment is inconclusive, kidney transplant can also be considered for the treatment.

CONCLUSION

Microscopic polyangiitis usually presents with renal involvement, rarely it presents only with pulmonary involvement. Therefore, this case report is unique and demands further research about the disease and its organ involvement, so that it can help future physicians with quick diagnosis and the patients of the disease can be treated well within time.

ACKNOWLEDGEMENTS

Authors would like to thank the Department of Internal medicine, Sardar Vallabhbhai Patel Institute of Medical Science and research for guiding and helping us in the quick diagnosis and treatment of the patient.

Funding: No funding sources

Conflict of interest: None declared

Ethical approval: Not required

REFERENCES

1. Dousdampanis P, Assimakopoulos SF, Trigka K. Microscopic Polyangiitis: from Pathogenesis to Treatment. Urol Nephrol Open Access J. 2017;5(2):00167.
2. Koldingsnes W, Nossent H Epidemiology of Wegener's granulomatosis in northern Norway. Arthritis Rheum. 2000;43(11):2481-7.
3. Mahr A, Guillevin L, Poissonnet M, Aymé S. Prevalences of polyarteritis nodosa, microscopic polyangiitis, Wegener's granulomatosis, and Churg-Strauss syndrome in a French urban multiethnic population in 2000: a capture-recapture estimate. Arthr Care Res. 2004 Feb 15;51(1):92-9.
4. Cleveland Clinic Web site. Available at http://my.clevelandclinic.org/health/diseases_conditions/hic_Microscopic_Polyangitis. Accessed 11 feb 2020.
5. Chung SA, Seo P. Microscopic polyangiitis. Rheum Dis Clin North Am. 2010;36(3):545-58.
6. Jennette JC, Wilkman AS, Falk RJ. Anti-neutrophil cytoplasmic autoantibody-associated glomerulonephritis and vasculitis. Am J Pathol. 1989 Nov;135(5):921.
7. Van der Woude FJ, Lobatto S, Permin H, Van der Giessen M, Rasmussen N, Wiik A, et al. Autoantibodies against neutrophils and monocytes: tool for diagnosis and marker of disease activity in Wegener's granulomatosis. Lancet. 1985 ;325(8426):425-9.
8. Villiger PM, Guillevin L. Microscopic polyangiitis: Clinical presentation. Autoimmun Rev. 2010;9(12): 812-9.
9. Lyons PA, Rayner TF, Trivedi S, Holle JU, Watts RA, Jayne DR, et al. Genetically distinct subsets within ANCA-associated vasculitis. N Engl J Med. 2012 Jul 19;367(3):214-23.
10. Tzelepis GE, Kokosi M, Tzioufas A, Toya SP, Boki KA, Zormpala A, et al. Prevalence and outcome of pulmonary fibrosis in microscopic polyangiitis. Europ Respir J. 2010;36(1):116-21.
11. Gal AA, Velasquez A. Antineutrophil cytoplasmic autoantibody in the absence of Wegener's granulomatosis or microscopic polyangiitis: implications for the surgical pathologist. Modern Pathol. 2002;15(3):197-204.
12. Gaudin PB, Askin FB, Falk RJ, Jennette JC. The pathologic spectrum of pulmonary lesions in patients with anti-neutrophil cytoplasmic autoantibodies specific for anti-proteinase 3 and anti-myeloperoxidase. Am J Clin Pathol. 1995 ;104(1):7-16.
13. Nada AK, Torres VE, Ryu JH, Lie JT, Holley KE. Pulmonary fibrosis as an unusual clinical manifestation of a pulmonary-renal vasculitis in elderly patients. Mayo Clinic Proceedings, Elsevier 1990;65(6):847-56.

Cite this article as: Singhvi SD, Singh P, Khan R, Patel M, Acharya P. A case report of microscopic polyangitis presenting as diffuse pulmonary symptoms with no renal involvement. Int J Res Med Sci 2020;8:1578-81.