

Original Research Article

Systemic thrombolysis with tenecteplase in stent thrombosis patients as a life saving measure in odd situations: an observational study from tertiary care hospital

Awadhesh Kumar Sharma^{1*}, Neeraj Prakash², M. M. Razi¹, Sameer Sarraf³, Santosh Sinha¹, Umeshwar Pandey¹, Ramesh Thakur¹

¹Department of Cardiology, ²Department of Cardiothoracic Surgery, LPS Institute of Cardiology, Kanpur, Uttar Pradesh, India

³Department of Cardiology, Uttar Pradesh University of Medical Science, Saifai, Etawah, Uttar Pradesh, India

Received: 23 March 2020

Accepted: 03 April 2020

*Correspondence:

Dr. Awadhesh Kumar Sharma,
E-mail: awakush@gmail.com

Copyright: © the author(s), publisher and licensee Medip Academy. This is an open-access article distributed under the terms of the Creative Commons Attribution Non-Commercial License, which permits unrestricted non-commercial use, distribution, and reproduction in any medium, provided the original work is properly cited.

ABSTRACT

Background: Coronary artery stent thrombosis specifically acute stent thrombosis is always a nightmare for interventionist. Stent thrombosis is one of a severe and catastrophic complication of percutaneous coronary intervention (PCI). Repeat PCI is commonly considered the preferred strategy to manage patients with stent thrombosis. Thrombolytic therapy is considered only partially effective.

Methods: This was a single centre largest ever observational study on this topic comprising of total 110 patients with history of previous stent implantation and now presented with an acute ST segment elevation myocardial infarction due to a probable stent thrombosis successfully treated with systemic thrombolysis with tenecteplase were studied over the period of 2 years (April 2017 to March 2019).

Results: On analyzing data clinical success was reported in 92 (83.6%) patients, electrocardiographic success is seen in 102 (92.7%) patients while angiographic success was reported in 80(72.7%) patients. Cerebrovascular accident were reported in 2 (1.8%) patients which died later on.

Conclusions: This study which is the first ever largest observational study on this topic demonstrates that, in patients with probable stent thrombosis and a short time to reperfusion in some specific extraordinary situations where timely percutaneous coronary intervention is not possible, systemic thrombolysis by fibrin specific Tenecteplase can be done as a life saving procedure which is associated with good immediate results.

Keywords: Catheterization lab, Coronary angiography, Stent thrombosis, Systemic thrombolysis, ST segment elevation myocardial infarction, Tenecteplase

INTRODUCTION

Coronary artery stent thrombosis specifically acute stent thrombosis is always a nightmare for interventionist. In intervention cardiology one of the most catastrophic and severe complication following PCI is stent thrombosis.¹ Overall incidence of stent thrombosis reported in different studies is around 0.6-2%. Despite of low

incidence of stent thrombosis in modern era due to availability of potent antiplatelet drugs and imaging techniques, it has a major clinical impact because of high risk of new myocardial infarction and death. As high as approximately 45-50% patients died post stent thrombosis.² To study and to maintain uniformity stent thrombosis definition is given by Academic Research Consortium (ARC) which is applicable all over the world.³ The ARC is composed of clinical investigators,

industry representatives and regulators including the Food and Drug Administration, and the definition categories stent thrombosis according to the level of documentation and timing

- Definite or confirmed event (symptoms suggestive of an acute coronary syndrome and angiographic or pathologic confirmation of stent thrombosis)
- Probable event (unexplained death within 30 days or target vessel myocardial infarction without angiographic confirmation of stent thrombosis)
- Possible event (any unexplained death after 30 days post stent implantation)

Based on the elapsed time since stent implantation stent thrombosis can be classified as

- Early (0-30 days post stent implantation)
- Late (>30 days)
- Very late (>12 months)

Often, early stent thrombosis is further subdivided into acute (<24 hours) and sub-acute (1-30 days) events. Because the number of stents implanted per year is increasing and the introduction of drug-eluting stents seems to be associated with a slight increase in the incidence of thrombosis, the absolute number of patients suffering from this complication is not negligible. Repeat PCI is commonly considered the preferred strategy to manage patients with stent thrombosis, whereas thrombolytic therapy is considered only partially effective. However, 24 h catheterization laboratories are not present in all hospitals and patient transport to hospitals with these facilities may be time consuming. Sometimes at the time of acute stent thrombosis catheterization laboratories are occupied in some procedures of long duration or not functioning sometime. At this time except thrombolysis no option left as lifesaving procedure.

Authors studied the cases of 110 patients with a previous stent implantation who were admitted to the hospital for an acute myocardial infarction with ST segment elevation myocardial infarction (STEMI) due to a probable stent thrombosis successfully treated with systemic thrombolysis with tenecteplase and later on followed by check angiography and if needed angioplasty.

METHODS

This study was a single center observational study conducted at the department of Cardiology of LPS Institute of Cardiology, Kanpur, UP, India. A total of 110 patients were studied over the period of 2 years (April 2017 to March 2019).

Inclusion criteria

Post PCI patients who presented with acute ST segment elevation MI in same arterial territory as of stented vessel

and got thrombolysis by weight based iv bolus injection of tenecteplase either at remote Centre or at our Centre in odd situations as a life saving measure and those post PCI patients who were not willing for repeat percutaneous cardiac procedure.

Patients having contraindications for thrombolysis, not willing for thrombolysis, having STEMI in different arterial territory and those presented in stage of cardiogenic shock were excluded from the study. Odd situations were defined as nonfunctioning catheterization laboratories, occupied catheterization laboratory, patient unwilling for repeat percutaneous procedure, night hours when Catheterization labs are not working at our Centre due to limited resources and when patients clinical condition is not suitable for transportation to catheterization lab as per treating physician instruction. The main aims and objectives of the study was to study effect of thrombolysis with tenecteplase in stent thrombosis patients presenting as acute ST segment elevation MI as a life saving measure in odd situations with primary endpoints in the form of Clinical success rate, Electrocardiographic success rate, Angiographic success rate and secondary end points in the form of overall death rate and major adverse cardiovascular events in the form of arrhythmia, cardiac arrest, cerebrovascular accidents.

Stent thrombosis is defined as per Academic Research Consortium (ARC) definition. Clinical success is defined as regression of chest pain. Electrocardiographic success is defined as more than 50% reduction in ST segment elevation. While angiographic success is defined as patency of the infarct-related artery (Thrombolysis In Myocardial Infarction [TIMI] grade 3 flow) without evidence of any angiographic alteration either in the implanted stent or at other location in same artery.

RESULTS

In this study 110 patients who presented with acute STEMI in same arterial territory as of stented vessel and were suitable for thrombolysis are thrombolysed with weight based regimen of IV bolus of tenecteplase (TNK). All patients were treated with systemic thrombolysis using Tenecteplase, Unfractionated heparin (UFH) and dual anti platelets (DAPT) drugs in loading doses (aspirin and clopidogrel /prasugrel /ticagrelor).

Out of these 92(83.6%) patients were thrombolysed in our centre in odd situations as a life-saving procedure and 18(16.3%) patients are thrombolysed in remote non PCI capable centres and then transferred to this centre.

Out of 110 patients 80(72.7%) were male and 30(27.2%) were female. Mean age group of patients in both sex were 60±12 years. Out of 110 patients 92(83.6%) patients were of acute stent thrombosis, 12(10.9%) patients of sub-acute stent thrombosis and 6(5.4%) patients were of late stent thrombosis (Table 1).

Table 1: Type of stent thrombosis in this study.

Type of stent thrombosis	Number of patients	Percentage
Acute stent thrombosis	92	83.6%
Sub-acute stent thrombosis	12	10.9%
Late stent thrombosis	6	5.4%

Of these 110 patients, 85(77.2%) patients were taken for coronary angiography to know the coronary anatomy within next 24 hours, 23(20.9%) patients not willing for any repeat percutaneous catheterization procedure while 2(1.8%) patients were expired before planned angiography. On analyzing data clinical success rate was reported in 92(83.6%) patients, electrocardiographic success rate is seen in 102(92.7%) patients while angiographic success was reported in 80 (72.7%) patients (Figure 1).

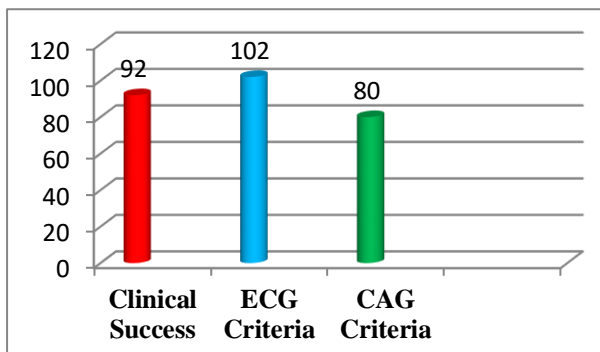


Figure 1: Primary end points (n=number of patients on top of bar).

Table 2: Secondary end points.

Secondary endpoints	Number of patients	Percentage
IVRT	12	10.9%
VT	4	3.6%
VF	2	1.8%
Cardiac arrest	2	1.8%
CVA	2	1.8%
Death	2	1.8%

Secondary end points like arrhythmia in the form of idioventricular tachycardia (IVRT) reported in 12(10.9%) patients and reverted spontaneously to normal rhythm, in 4(3.6%) patients ventricular tachycardia with hemodynamic instability reported which responded to DC cardioversion while 2(1.8%) patients had terminal rhythm in the form of ventricular fibrillation followed by cardiac arrest. Cerebrovascular accident were suspected in 2(1.8%) patients, in one patient it was confirmed by NCCT head showing intracranial hemorrhage and while other patient died before performing NCCT head (Table 2). In stable patients ie 108(98.2%), there were no in-

hospital complications and the patients were discharged within five days.

DISCUSSION

In spite of modern advances, stent thrombosis is a severe complication arising after the implantation of a stent. It may be due to different factors divided into three categories

- Patient related factors- like history of diabetes mellitus (DM), Acute Coronary Syndromes (especially STEMI), left ventricular dysfunction, renal failure, advanced age, high platelet reactivity.
- Lesion characteristics like small vessel diameter, long lesion, bifurcation lesions, calcified lesion, tortuous lesions.
- Procedure related factors like use of multiple stents, geographic miss, stent malapposition, under-expansion of the stent, stent design (strut thickness and polymer type), no flow, slow flow or dissection during procedure.
- Related to Anti-platelet therapy- like inadequate intensity of therapy (i.e. non-dual platelet inhibition or insufficient dose), non-compliance, premature cessation of anti-platelet therapy.^{4,5}

Early stent thrombosis is usually correlated to procedural factors and drug resistance to antiplatelets while late and very late stent thrombosis are because of patient and lesion related factors. And, non-compliance to antiplatelet therapy. With development of third generation drug eluting stents and potent P2Y12 inhibitors like Ticagrelor, the rate of stent thrombosis are very less (<1%) in modern era. However, due to the increasing number of stents implanted, the total number of patients who experience stent thrombosis is not negligible. In our study majority of the patient are due to acute and sub-acute stent thrombosis. The mechanisms underlying the stent thrombosis in our patients remain unknown as it was not entitled to study this point. This can be a study material for further studies in same field. However, in 40(36.3%) of the patients, a premature discontinuation of the antiplatelet therapy was documented and this may play a significant role in the pathogenesis of stent thrombosis, as shown in previous studies.⁵

Presently, no clear definition exists for the best management strategy of stent thrombosis. Some reports have shown the efficacy of repeated interventional procedures, and a multicenter study is being performed for the ongoing evaluation of the outcome of patients treated with a repeat PCI.⁶ However, many hospitals do not have 24 h catheterization laboratory facilities and patient transport to another hospital may be time consuming or in some odd situations even in centres having on-site PCI facility it is not possible to do catheterization procedures round the clock due to limited resources. In our study too, due to unavailability of 24 h

catheterization laboratory facility (especially in night hours) for urgent coronary revascularization because of limited resources and even during working hours in odd situations as described above, patients who were admitted to our centre (during the night or during odd situations) for an acute myocardial infarction with ST segment elevation MI post PCI were treated with systemic thrombolysis by weight adjusted iv Tenecteplase along with heparin and DAPT.

Out of these 110 patients, 85 (77.2%) patients were taken for coronary angiography to know the coronary anatomy within next 24 hours, 23 (20.9%) patients were not willing for any repeat catheterization procedure while 2 (1.8%) patients were expired before planned angiography. In a case series by Alessandro et al all four patients were taken for coronary angiography post thrombolysis within 24 hours.⁷ Since our study is large one and few patients especially of rural background deny any repeat catheterization procedure in spite of explaining them the related benefit. The main reason for not giving consent to coronary angiography (CAG) was rapid relief in chest pain post thrombolysis, subconscious fear from catheterization procedure due to unfortunate initial experience in the form of procedure related complication, rural background and lack of knowledge. On further analyzing data clinical success rate was reported in 92 (83.6%) patients, electrocardiographic success rate is seen in 102 (92.7%) patients while angiographic success was reported in 80(72.7%) patients. In a case series by Alessandro et al overall success rate was seen in all patients without any mortality. In contrary to this, in our study secondary end points like arrhythmia in the form of idioventricular tachycardia (IVRT) reported in 12(10.9%) patients which reverted spontaneously to normal rhythm, in 4(3.6%) patients ventricular tachycardia with hemodynamic instability reported which responded to DC cardio version while 2(1.8%) patients had terminal rhythm in the form of ventricular fibrillation followed by cardiac arrest. In Alessandro case series no case of cerebrovascular accident was seen.⁷ Similarly in a case report by SE Bowater et al he successfully treated a case of sub acute stent thrombosis in Left anterior descending artery to left main(LAD/LM) by systemic thrombolysis by Tenecteplase and intravenous infusion of GpIIb/IIIa inhibitor abciximab without any cerebrovascular complication.⁸ In this study cerebrovascular accident were suspected in 2 (1.8%) patients and both of them died, in one patient CVA was confirmed by non-contrast computed tomogram (NCCT) head showing intracranial hemorrhage while the other patient died before performing NCCT head. Since our study is largest ever study on this topic and due to availability of more potent antiplatelet agents occurrence of cerebrovascular accident especially intracranial hemorrhage was reported. In this these 2 patients who had intracranial hemorrhage, in one patient aspirin + clopidogrel was used while in other aspirin + Ticagrelor was used. Authors used Gp IIb/IIIb inhibitors in one of these patients due to high thrombotic score. Intracranial hemorrhage represents the most

serious complication of fibrinolytic therapy and may be fatal in half to two-third of patients.⁹ In different studies it was seen that the incidence of intracranial hemorrhage is highest in the first 24 h and patients should be very closely observed for any signs and symptoms of intracranial hemorrhage post thrombolysis specially with non fibrin specific agents.¹⁰ The risk of intracranial hemorrhage with the newer drugs, particularly Tenecteplase, is less than 1%.¹¹ The predictors of intracranial hemorrhage after thrombolytic are old age, lower bodyweight (weight less than 65 kg for women or 80 kg for men), female gender, prior cerebrovascular disease, uncontrolled hypertension and history of diabetes mellitus. Safety of this approach in wake of newer potent antiplatelet agents need further studies in view of safety.

In stable patients ie 108(98.1%), there were no in-hospital complications and the patients were discharged within five days. In this case collection, the good results obtained with systemic thrombolysis may be explained by the very short symptom-to-treatment time. Indeed, many studies showed that the efficacy of thrombolysis is inversely correlated with the time to treatment from symptom onset. Moreover, a previous study by Bonnefoy et al showed a similar degree of efficacy of thrombolysis compared with percutaneous angioplasty in the treatment of ST elevation myocardial infarction when the time from symptom onset to reperfusion was less than 2h.¹² Our results may also be explained through the thrombolytic agent used. Previous studies showed the reduced efficacy of urokinase (a nonfibrin-specific thrombolytic agent) in the treatment of acute stent thrombosis but a subsequent case report described the good results obtained with the use of tenecteplase.¹³ Tenecteplase differs significantly from urokinase because it is a highly fibrin-specific single-bolus thrombolytic agent with a simplified route of administration that facilitates rapid time to treatment. Tenecteplase (TNK-tPA) is the easiest fibrinolytic to use (it can be given as a single bolus), and in ASSENT-2 trial it was associated with a significantly lower rate of non-cerebral bleeding complications and the need for transfusions compared to reteplase. Because of this Tenecteplase is the fibrinolytic agent of choice in many hospitals.¹⁴

A limitation of the present study is that the patients were taken for thrombolysis directly and the angiographic documentation of stent thrombosis was lacking. However, according to the definitions of the 2006 Academic Research Consortium, stent thrombosis is classified as probable when a myocardial infarction, occurring at any time after the index procedure, is documented in the target vessel territory without angiographic confirmation.

CONCLUSION

This study which is the first ever largest observational study on this topic demonstrates that, in patients with probable stent thrombosis and a short time to reperfusion

in some specific conditions where timely percutaneous intervention is not possible, systemic thrombolysis by fibrin specific Tenecteplase as a life saving procedure may be associated with good immediate results.

ACKNOWLEDGEMENTS

Authors would like to thank Dr. Vinay Krishna, Director, LPS Institute of Cardiology, GSVM Medical College, Kanpur and Dr C. M. Verma, Department Cardiology for their special support during the course of this study.

Funding: No funding sources

Conflict of interest: None declared

Ethical approval: Not required

REFERENCES

1. Burzotta F, Romagnoli E, Manzoli A, Pristipino C, Belloni F, Sardella G, et al. The outcome of PCI for stent-thrombosis multicentre study (OPTIMIST): Rationale and design of a multicentre registry. *Am Heart J.* 2007;153:377(3);e1-7.
2. Iakovou I, Schmidt T, Bonizzoni E, Ge L, Sangiorgi GM, Stankovic G, et al. Incidence, predictors, and outcome of thrombosis after successful implantation of drug-eluting stents. *JAMA.* 2005;293(17):2126-30.
3. Tyczyński P, Karcz MA, Kalińczuk Ł, Fronczak A, Witkowski A. Early stent thrombosis. Aetiology, treatment, and prognosis. *Postepy Kardiologii Interwencyjnej.* 2014;10(4):221-5.
4. Luscher TF, Steffel J, Eberli FR, Joner M, Nakazawa G, Tanner FC, et al. Drug-eluting stent and coronary thrombosis: biological mechanisms and clinical implications. *Circulation.* 2007;115(8):1051-8.
5. Gurbel PA, Bliden KP, Guyer K, Cho PW, Zaman KA, Kreutz RP, et al. Platelet reactivity in patients and recurrent events post-stenting: results of the PREPARE POST-STENTING Study. *J Am Coll Cardiol.* 2005;46(10):1820-6.
6. Holmes DR, Kereiakes DJ, Laskey WK, Colombo A, Ellis SG, Henry TD, et al. Thrombosis and drug-eluting stents. *J Am Coll Cardiol.* 2007 Jul 10;50(2):109-18.
7. Sciahbasi A, Patrizi R, Madonna M, Summaria F, Scioli R, Carlino G, et al, *MD Can J Cardiol.* 2009 Jun; 25(6):e213-4.
8. Bowater SE, Doshi SN, Buller NP. Subacute stent thrombosis successfully treated with thrombolysis and glycoprotein IIb/IIIa inhibition. *Heart.* 2005;91(4):488.
9. Gurwitz JH, Gore JM, Goldberg RJ, Barron HV, Breen T, Rundle AC, et al. Risk for intracranial hemorrhage after tissue plasminogen activator treatment for acute myocardial infarction. Participants in the National Registry of Myocardial Infarction 2. *Ann Intern Med.* 1998 Oct 15;129(8):597-604.
10. The Assessment of the Safety and Efficacy of a New Thrombolytic Regimen (ASSENT)-3 Investigators Efficacy and safety of tenecteplase in combination with enoxaparin, abciximab, or unfractionated heparin: the ASSENT-3 randomised trial in acute myocardial infarction Original Research Article. *Lancet* 2001 Aug 25;358(9282):605-13.
11. Assessment of the safety and efficacy of a New Thrombolytic Investigators Single bolus tenecteplase compared with front loaded alteplase in acute myocardial infarction: the ASSENT- 2 double blind randomized trial. *Lancet* 1999 Aug 28;354(9180):716-22.
12. Bonnefoy E, Lapostolle F, Leizorovicz A, Steg G, McFadden EP, Dubien PY, et al. Comparison of Angioplasty and Prehospital Thrombolysis in Acute Myocardial Infarction Study Group. Primary angioplasty versus prehospital fibrinolysis in acute myocardial infarction: a randomised study. *Lancet.* 2002 Sep 14;360(9336):825-9.
13. Mamtimin H, Rupprecht HJ, Nowak B, Voigtlander T, Darius H, Meyer J. Comparison of reoPro (abciximab) versus intracoronary thrombolysis for early coronary stent thrombosis. *Int J Cardiovasc Intervent.* 2000;3(3):173-9.
14. Kunadian V, Gibson CM. Thrombolytics and myocardial infarction. *Cardiovascular therapeutics.* 2012 Apr;30(2):e81-8.

Cite this article as: Sharma AK, Prakash N, Razi MM, Sarraf S, Sinha S, Pandey U, et al. Systemic thrombolysis with tenecteplase in stent thrombosis patients as a life saving measure in odd situations: an observational study from tertiary care hospital. *Int J Res Med Sci* 2020;8:1649-53.