

Research Article

Comparative study of surgically induced astigmatism in superior versus temporal incision in small incision cataract surgery cases

Kuruva Nandyala Sree Kavitha^{1*}, Arikeri Krishna Kishore¹, Ganta Sudhakar Reddy¹,
Khaiser Jehan²

¹Department of Ophthalmology, Sarojini Devi Eye Hospital and Regional Institute of Ophthalmology, Hyderabad, India

²Sarojini Devi Eye Hospital and Regional Institute of Ophthalmology, Hyderabad, India

Received: 19 September 2015

Revised: 03 October 2015

Accepted: 15 October 2015

*Correspondence:

Dr. Kuruva Nandyala Sree Kavitha,
E-mail: kavithaanand2012@gmail.com

Copyright: © the author(s), publisher and licensee Medip Academy. This is an open-access article distributed under the terms of the Creative Commons Attribution Non-Commercial License, which permits unrestricted non-commercial use, distribution, and reproduction in any medium, provided the original work is properly cited.

ABSTRACT

Background: Location of incision has a significant impact on surgical outcome. It has been reported that temporal incisions induce less astigmatism than superior incisions indicating the importance of incision location. The objective of the present study was to study the effect of surgically induced astigmatism in superior versus temporal incision in small incision cataract surgery cases.

Methods: 100 patients of cataract attending to Sarojini Devi eye hospital with the rule and against the rule astigmatism were included in the study. The astigmatic profile and the effect of surgical incision on astigmatism were studied. A prospective study was done in which patients were divided into two groups. MSICS was performed with superiorly located incision in group I and temporally located incision in group II.

Results: Out of the total 100 patients undergoing MSICS, 59 patients had ATR, 36 patients had WTR and 5 patients had no astigmatism. Thus the pre-operative astigmatic profile shows that ATR is more common type of astigmatism in this group. Among 50 patients in superior incision group, 18 had pre-operative WTR, 29 had ATR and 3 did not have astigmatism. Postoperatively the no. of patients with WTR decreased to 10, the no. of patients with ATR increased to 35 showing that superior incision flattens vertical meridian and steepens the horizontal meridian causing ATR shift. Among 50 patients in temporal incision group, 18 had pre-operative WTR, 30 had ATR and 2 did not have astigmatism. Post operatively the no of patients with WTR increased to 25, the no of patients with ATR decreased to 20.

Conclusions: Placement of incision on steep axis reduces pre-existing astigmatism. Thus in ATR astigmatism it is placed temporally and in WTR astigmatism it is placed superiorly. Thus a simple modification in incision placement can minimize surgically induced astigmatism and reduce pre-existing astigmatism

Keywords: With the rule astigmatism, Against the rule astigmatism, Superior incision, Temporal incision

INTRODUCTION

Cataract surgery in the present era is evolving as a refractive surgery. Recent progress in the cataract surgery has heightened the patient's expectations about visual outcome. Good postoperative vision without spectacles is

considered the norm. Thus control of postoperative astigmatism is key in meeting these expectations.

The purpose of modern cataract surgery is not only cataract extraction followed by IOL implantation but also to achieve best uncorrected visual acuity by reducing the

pre-existing astigmatism and minimizing the SIA. Manual small incision cataract surgery (MSICS) through a sclerocorneal tunnel has become a standard procedure with advantages of sutureless wound closure, less astigmatism and less cost.

Several variables exist in the creation of wound of cataract surgery such as location, direction, width, depth and shape. Location of incision has a significant impact on surgical outcome. It has been reported that temporal incisions induce less astigmatism than superior incisions indicating the importance of incision location.

Thus our study was conducted with the objective to study the effect of location of incision on pre-existing astigmatism and surgically induced astigmatism.

The aim and objectives of the study was:

1. To study the pre-operative astigmatic profile.
2. To study the effect of location of incision.
 - On preoperative astigmatism.
 - On surgically induced astigmatism.

METHODS

This was a prospective study of 100 patients undergoing manual small incision cataract surgery at Sarojini Devi Eye Hospital, Hyderabad.

Inclusion criteria

1. Regular astigmatism (with the rule astigmatism (WTR)).
2. Against the rule astigmatism (ATR).

Exclusion criteria

1. Irregular astigmatism.
2. Traumatic cataract.
3. Corneal dystrophies and degenerations.

A thorough preoperative evaluation of the cases including pre-operative keratometry, slit lamp examination of anterior segment, fundus examination with 90D and A scan were done. The incision was placed on the steep axis where the astigmatism was $>1D$. In cases where the astigmatism was $<1D$, the incision was placed either superiorly or temporally MSICS was performed with superiorly located incision in group I and temporally located incision in group II.

Procedure

After preparing the eye for surgery, fornix based conjunctival flap was taken at superior or temporal limbus and gentle cautery was done. A frown shaped scleral incision of about 6-6.5mm was placed 2mm behind the limbus superiorly or temporally. Dissection of sclerocorneal tunnel was done with crescent up to 1.5mm

inside the cornea. A side port was made at 10', 7' or 1' o clock position. Viscoelastic was injected into anterior chamber and a continuous curvilinear capsulorrhexis approximately 5 mm was done with cystitome through side port. Then the sclerocorneal tunnel was completed using 3.2mm keratome and extended to 6-6.5mm. The internal corneal opening was made 1-2mm larger than external opening. Thorough hydro dissection was done and nucleus was prolapsed into the anterior chamber and viscoelastic was injected in front and behind the lens nucleus. Lens nucleus was delivered out using sandwich technique using vectis and Sinsky Hook. Remaining cortical matter was removed with Simcoe cannula and 6mm optic (overall 12.5 mm) PMMA single piece posterior chamber lens was inserted in the capsular bag. The remaining viscoelastic was aspirated and the anterior chamber was reformed with BSS through the sideport. The main wound was checked for any leakage and then conjunctiva was closed using cautery.

Post-operative treatment included topical steroid & antibiotic combination for a week followed by only topical steroid in a tapering dose for 5 wks. Patients were examined on 1st POD (postoperative day), 1 week, 6 weeks and 3 months for keratometry readings.

For simplification of analysis all astigmatic changes were studied only in the vertical & horizontal meridian. Oblique astigmatism was not studied. The results of two groups were compared with regard to post-operative astigmatism. Analysis of astigmatism was performed by subtraction method.

Paired and unpaired t test was applied to find out the significant difference between the superior and temporal incisions.

RESULTS

The preoperative astigmatic profile of patients shown in Table 1 shows that the no. of patients with WTR is 36, ATR is 59 and without any astigmatism is 5 (Table 1).

The preoperative astigmatic profile in WTR in superior incision is 18 and postoperative is 1 the preoperative astigmatic profile in WTR in temporal incision is 18 and postoperative is 25. The preoperative astigmatic profile in ATR in superior incision is 29 and postoperative is 35. The preoperative astigmatic profile in ATR in temporal incision is 30 and postoperative is 20 (Table 2).

Table 1: Pre-operative astigmatic profile of cataract patients.

Type of astigmatism	No. of patients
WTR	36
ATR	59
No astigmatism	5

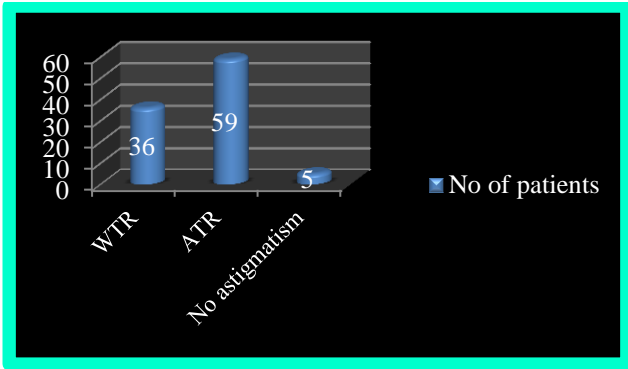


Figure 1: Pre-operative astigmatic profile of cataract patients.

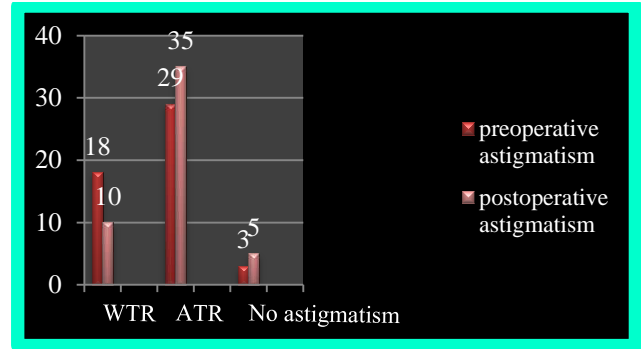


Figure 2A: Pre and post-operative astigmatic profile in superior incision group.

Table 2: Pre and post-operative astigmatic profile in superior and temporal incision groups.

Type of astigmatism	Superior incision		Temporal incision	
	Pre-operative	Post-operative	Pre-operative	Post-operative
WTR	18	10	18	25
ATR	29	35	30	20
No astigmatism	3	5	2	5

The mean preoperative astigmatism in superior incision is 0.85 and postoperative astigmatism is 1.55. The mean preoperative astigmatism in temporal incision is 0.65 and postoperative astigmatism is 0.50 (Table 3).

Table 3: Pre, post and surgically induced astigmatism in superior and temporal incision groups.

	Superior incision	Temporal incision	P-Value
Mean preoperative astigmatism (D)	0.85+/-0.75	0.65+/-0.35	P = 0.907
Mean post-operative astigmatism (D) (6 wks.)	1.55+/-1.15	0.50+/-0.35	P<0.0001
Mean SIA (D)	0.95+/-0.5	0.60+/-0.5	P<0.0001

The change in astigmatism in ATR and WTR group is shown in table 4 and 5 respectively. The mean astigmatism increased from 0.81+/-0.65 to 1.50+/-0.5 post operatively and in the temporal incision group the mean astigmatism decreased from 1.45+/-0.5 to 1.05+/-0.2 post operatively.

DISCUSSION

While phacoemulsification remains the more advanced and technically superior method of cataract surgery, it is

not always appropriate either from a cost perspective or the density of the cataracts involved. MSICS is the first choice alternative to phacoemulsification- retains most of the advantages of “phacoemulsification” giving visual results equivalent to phacoemulsification at a lower cost and it is the surgery for the masses and appropriate for a developing country. The surgery is cheap, fast, safe and easy to learn and needs fewer resources. However, the larger incision used induces greater astigmatism than phacoemulsification. High astigmatism is an important cause of poor uncorrected visual acuity after cataract surgery. In view of these findings, this study was done with the aim to study the effect of location of incision on pre-existing and surgically induced astigmatism.

In our study out of the total 100 patients undergoing MSICS, 59 patients had ATR, 36 patients had WTR and 5 patients had no astigmatism. Thus the pre-operative astigmatic profile shows that ATR is more common type of astigmatism in this group of patients undergoing cataract surgery group.^{1,8} This is because in normal healthy eyes stiff upper tarsal plate causes pressure on cornea resulting in with the rule astigmatism but with increasing age this pressure gradually decreases resulting in against the rule astigmatism.

In our study, based on the pre-operative keratometric values, the incision was placed on the steep axis where the astigmatism was >1D. In cases where the astigmatism was <1D, the incision was placed either superiorly or temporally.

As we know from the review of literature on relation between location of incision and astigmatism, placing the

incision on flat axis increases the astigmatism and if it is placed on the steep axis it decreases the astigmatism. Therefore in cases where the astigmatism was > 1D, incision was placed on the steep axis to avoid further increase in the amount of astigmatism.

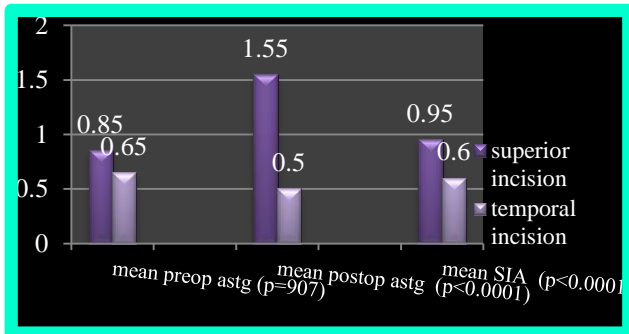


Figure 3: Pre, post and surgically induced astigmatism in superior and temporal incision groups.

Table 4: Change in astigmatism in ATR cases.

	Mean pre-operative astigmatism	Mean post-operative Astigmatism
Superior incision	0.81+/-0.65	1.50+/-0.5
Temporal incision	1.45+/-0.5	1.05+/-0.2

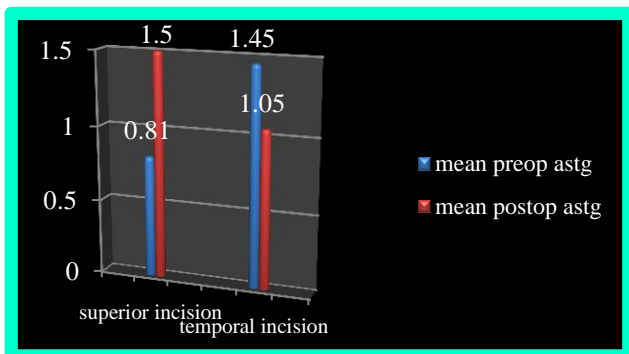


Figure 4: Change in astigmatism in ATR cases.

Table 5: Change in astigmatism in WTR cases.

	Mean pre-operative astigmatism	Mean post-operative Astigmatism
Superior incision	1.15+/-0.6	0.70+/-0.5
Temporal incision	0.65+/-0.5	0.75+/-0.5

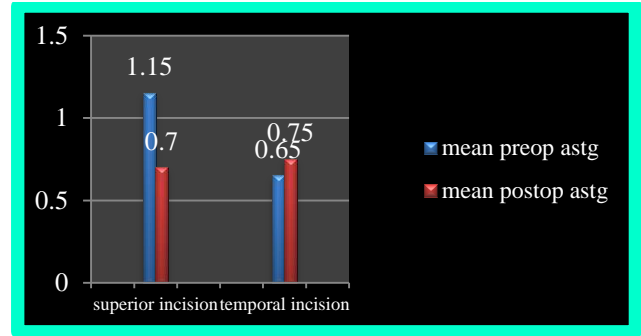


Figure 5: Change in astigmatism in WTR cases.

Among 50 patients in superior incision group, 18 had pre-operative WTR, 29 had ATR and 3 did not have astigmatism. Post operatively the no of patients with WTR decreased to 10, the no of patients with ATR increased to 35 showing that superior incision flattens vertical meridian and steepens the horizontal meridian causing ATR shift.²

Among 50 patients in temporal incision group, 18 had pre-operative WTR, 30 had ATR and 2 did not have astigmatism. Post operatively the no of patients with WTR increased to 25, the no of patients with ATR decreased to 20.^{3,9} This shows that temporal incision flattens horizontal meridian and steepens the vertical meridian causing WTR shift.

This is explained by the fact that flattening of the cornea occurs at direction right angles to direction of cataract incisions. During healing process of sclera-corneal incision proliferating fibrous tissue begins to form, running at right angles to the clear cut scleral edges and when the fibrous tissue contracts, flattening occurs at direction right angles to the direction of cataract incisions with consequent steepening of the opposite meridian. Therefore, superior incision flattens vertical meridian and steepens horizontal meridian. Temporal incision flattens horizontal meridian and steepens vertical meridian. This effect is more marked in the superior incision than temporal incision as the superior incision is closer to the visual axis than temporal incision.

In our study the mean pre-operative astigmatism in superior incision group was 0.85+/-0.75 which increased to 1.5+/-1.15 post operatively. The mean post-operative astigmatism in temporal incision group was 0.65+/-0.35 which decreased to 0.50+/-0.35 post operatively. Thus the post-operative astigmatism is more in superior incision group than temporal incision group. Our study shows that there is no statistically significant difference in the mean pre-operative astigmatism in superior (0.85+/-0.75) and temporal incision (0.65+/-0.35) groups (p=0.907).^{4,10} There is a statistically significant difference between the superior and temporal incision in post-operative astigmatism (p<0.0001) with the superior incision showing more astigmatism than the temporal group 1. The mean SIA was more in superior incision group than

temporal incision ($p < 0.0001$). This is because farther the incision from the visual axis less is the flattening effect on corneal curvature. Temporal incision is farther from the visual axis than the superior incision because the corneal diameter is greater in horizontal meridian than vertical meridian.

In our study the sub-analysis of change in astigmatism in cases with ATR shows that in superior incision group the mean astigmatism increased from 0.81 ± 0.65 to 1.50 ± 0.5 post operatively and in the temporal incision group the mean astigmatism decreased from 1.45 ± 0.5 to 1.05 ± 0.2 post operatively.⁵ Thus in cases with ATR the superior incision showed an increase in post-operative astigmatism while a temporal incision showed decrease in astigmatism.²

In our study the sub-analysis of change in astigmatism in cases with WTR shows that in superior incision group the mean astigmatism decreased from 1.15 ± 0.6 to 0.70 ± 0.5 post operatively and in the temporal incision group the mean astigmatism increased from 0.65 ± 0.5 to 0.75 ± 0.5 post operatively.³ Thus in cases with WTR the superior incision showed an decreased in post-operative astigmatism while a temporal incision showed a minimal increase in astigmatism.^{6,7}

This shows that placing the incision on flat axis increases the astigmatism and if it is placed on the steep axis it decreases the astigmatism. Thus simple change in the location of incision can be used as a factor to minimize the pre-existing astigmatism and reduce the SIA.

CONCLUSIONS

1. Pre-operative astigmatic profile shows that ATR is more common type of astigmatism than WTR and astigmatically neutral cases in older age group
2. Superior incision causes ATR shift and temporal incision causes WTR shift.
3. Temporal approach MSICS produces less post-operative astigmatism compared to superior incision.
4. Placement of incision on steep axis reduces preexisting astigmatism. Thus in ATR astigmatism it is placed temporally and in WTR astigmatism it is placed superiorly.
5. Thus a simple modification in incision placement can minimize surgically induced astigmatism and reduce preexisting astigmatism
6. Hence all cataract surgeons should familiarize with temporal incision in cataract surgery.

Funding: No funding sources

Conflict of interest: None declared

Ethical approval: The study was approved by the Institutional Ethics Committee

REFERENCES

1. Gokhale NS, Sawhney S. Reduction in astigmatism in manual small incision cataract surgery through change of incision site. *Indian J Ophthalmol.* 2005;53:201-3.
2. Magdum RM, Gahlot A, Maheshgauri RD, Khevna P. A comparative study of surgically induced astigmatism in superior and temporal scleral incision in manual small incision cataract surgery. *National Journal of Medical Research.* 2012;2(4):497.
3. Alam J, Bhattacharjya H, Roy A, Das R, Gupta S, Bhattacharya U, et al. A Comparative Study of Post-Operative Astigmatism in Superior versus Temporal Approach of Manual Small Incision Cataract Surgery". *Journal of Evolution of Medical and Dental Sciences.* 2014;3(26):7087-90.
4. Mallik VK, Kumar S, Kamboj R, Jain C, Jain K, Kumar S. Comparison of astigmatism following manual small incision cataract surgery: superior versus temporal approach. *Nepal J Ophthalmol.* 2012;4(2):343.
5. Radwan AA. Comparing Surgical-Induced Astigmatism through Change of Incision Site in Manual Small Incision Cataract Surgery (SICS). *J Clinic Experiment Ophthalmol.* 2011;2:161.
6. Pawar VS, Sindal DK. A comparative study on the superior, supero-temporal and the temporal incisions in small incision cataract surgeries for post-operative astigmatism. *Journal of Clinical and Diagnostic Research.* 2012;6:1229-32.
7. Oshika T, Samejima T, Miyata N. Calculation of surgically induced astigmatism. *Nihon Ganka Gakkai Zasshi.* 1995;99(8):901-9.
8. Yadav H, Rai V. A Study of Comparison Astigmatism Following Manual Small Incision Cataract Surgery: Superior versus Temporal Approach. *Journal of Evolution of Medical and Dental Sciences.* 2014;3(23):6430-4.
9. Koch PS: Structural analysis of cataract incision construction. *J Cataract Refractive Surgery.* 1991;17(Suppl):677-88.
10. Ernest PH, Lavery KT, Kiessling LA. Relative strength of scleral tunnel incisions with internal corneal lips constructed in cadaver eyes. *J Cataract Refract Surg.* 1993;19:457-61.

Cite this article as: Kavitha KNS, Kishore AK, Reddy GS, Jehan K. Comparative study of surgically induced astigmatism in superior versus temporal incision in small incision cataract surgery cases. *Int J Res Med Sci* 2015;3:3027-31.