

Case Report

Rhabdomyolysis with acute kidney injury after single episode of generalized seizure in a known case of epilepsy: a case report

Sudhakar Pandey^{1*}, Nomal C. Borah¹, Manjari Dwivedi², Rup J. Das¹

¹Department of Neurology, GNRC Hospital, Dispur, Guwahati, Assam, India

²Department of Endocrinology, Guwahati Medical College, Guwahati, Assam, India

Received: 02 September 2020

Accepted: 18 September 2020

*Correspondence:

Dr. Sudhakar Pandey,

E-mail: drsudhakarpandey2781@gmail.com

Copyright: © the author(s), publisher and licensee Medip Academy. This is an open-access article distributed under the terms of the Creative Commons Attribution Non-Commercial License, which permits unrestricted non-commercial use, distribution, and reproduction in any medium, provided the original work is properly cited.

ABSTRACT

Rhabdomyolysis is defined as breakdown of skeletal muscle fibers with subsequent release of its cellular components into the circulation. It is associated with variety of causes and status epilepticus is one of it. The excessive muscular activity associated with seizure is possible explanation for it. It is clinically evident by the new onset severe generalized bodyache, weakness and myalgia associated with dark coloured urine. Acute kidney injury is one of the most serious complications associated with rhabdomyolysis. Single episode of generalized seizure is not a frequent cause for rhabdomyolysis. Acute kidney injury due to rhabdomyolysis, following a single episode of seizure is a rare entity. Here we report a case of rhabdomyolysis with acute kidney injury following a single episode of generalized seizure. High index of suspicion is required to timely diagnose and treat such patients. Timely intervention with hemodialysis along with other supportive care can completely revert this potentially serious complication to normal.

Keywords: Rhabdomyolysis, Acute kidney injury, Seizure, Myoglobinuria, Creatine phosphokinase

INTRODUCTION

Rhabdomyolysis refers to disintegration of striated muscle fibers due to various reasons with release of its cell wall contents in the extracellular spaces and circulation namely myoglobin, creatine phosphokinase (CPK) and lactate dehydrogenase (LDH).¹ Multiple causes are enlisted for rhabdomyolysis and status epilepticus is one of them, mostly seen in poorly compliant epilepsy patients.^{2,3} It can cause significant muscle fibers damage due to repeated seizure episodes.

Post status rhabdomyolysis is most often seen after few hours of the last seizure episode. It is clinically evident by the new onset severe generalized bodyache, weakness and myalgia associated with dark cola coloured urine.⁴ It can occasionally be confused with post-ictus bodyache, hence there should be low threshold of suspicion for post-

status rhabdomyolysis in patients having prolonged severe bodyache with dark coloured urine.

Multiple episodes of seizure leading to rhabdomyolysis is very well explained by associated excessive muscle exhaustion and subsequent injury and is well supported by literature also. Acute renal dysfunction is well known phenomenon in rhabdomyolysis due to tubulo-interstitial injury associated with excessive free myoglobin level in the circulation.⁵ Rhabdomyolysis with acute kidney injury after single episode of generalized tonic clonic seizure (GTCS) is very rare phenomenon and to the best of our knowledge it has not been reported in literature, hence we wish to report this case.

CASE REPORT

A 27 year old male, banker from Assam, presented to us with history of single episode of GTCS two days back

followed by multiple episodes of vomiting. Patient also had generalized bodyache and decreased appetite. From the day of admission he had history of seizure disorder since 2016 and was on regular medication. Patient was on tapering dose of antiepileptic medication from last 6 months. Patient also had history of hearing problem since 3 years and was using hearing aid. There was no history of head injury, illicit drug use or fever.

On examination, patient had blood pressure of 130/80 mm of Hg, pulse rate of 108/minute and was afebrile. Cardiac, respiratory and abdominal examination was within normal limit. On neurological examination; his Glasgow Coma Scale (GCS) was 15/15 (E4V4M6), pupils were bilateral normal size and reacting. There was no suggestibility of neck stiffness and motor and sensory examination was within normal limit and he was moving all four limbs spontaneously.

He was started on antiepileptics and other supportive treatment. All relevant investigations including routine blood investigation, magnetic resonance imaging (MRI) brain and electroencephalogram (EEG) were planned. Blood investigation showed significantly deranged renal parameters (blood urea, 109 mg/dl, serum creatinine, 8.1 mg/dl) and mildly deranged hepatic parameters; aspartate aminotransferase (AST), 93 IU/l and alanine aminotransferase (ALT), 81 IU/l. The blood investigation also showed hyperuricemia; serum uric acid, 11.5 mg/dl, hypocalcemia; serum calcium, 7.7 mg/dl, hypermagnesemia; serum magnesium, 2.8 mg/dl and hyperphosphatemia; serum phosphate, 6.1 mg/dl, (Table 1). MRI brain was within normal limit and his interictal EEG showed borderline changes with sharp and slow wave activity (Figure 1 and 2).

Table 1: Laboratory parameter of the patient.

Time after admission	Day 1	Day 3	Day 5	Day 7	Day 8	Day 12	After 1month	Normal range
Blood UA, mg/dl	11.5							3.5-7.7
Blood urea, mg/dl	109	126	94	130	99	88	16	15-40
Serum creatinine, mg/dl	8.1	8.3	5.2	5.0	2.7	1.7	0.9	0.8-1.3
Serum sodium, mmol/l	134	135	136		144	137	133	136-148
Serum potassium, mmol/l	4.6	4.3	4.4		2.6	4.6	3.8	3.6-5.2
Serum magnesium, mg/dl	2.8							1.8-2.6
CK, IU/l	27521		2730		284			39-308
Plasma glucose, mg/dl	114							60-140
Serum calcium, mg/dl	7.7							8.8-10.5
Serum phosphate, mg/dl	6.1							2.5-4.5
Plasma myoglobin, ng/ml	3000							0-110
Urine myoglobin test	positive							absent
Serum AST, IU/l	350		93			25		15-37
Serum ALT, IU/l	98		81			41		16-63

UA= uric acid, AST= Aspartate aminotransferase, ALT=Alanine aminotransferase, CPK= creatine phosphokinase

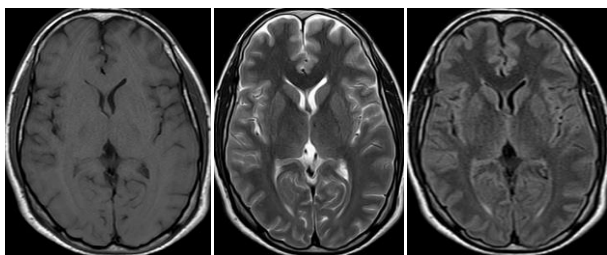


Figure 1: MRI brain (T1w, T2w and flair sequences) shows normal imaging.

From the night of hospitalization, patient started having increased generalized bodyache and decrease in urine output. The finding of decrease in urine output associated with generalized bodyache raised our suspicion regarding the possibility of rhabdomyolysis in our patient. Serum creatine phosphokinase (CPK), USG Abdomen and

serum as well as urine myoglobin was sent for testing. Report showed, CPK level to be very high (27521 IU/l), serum myoglobin was 3000 ng/ml and urine myoglobin was also high. The ultrasound abdomen showed bilateral swollen kidneys with increased cortical echogenicity (Figure 3).

The above findings established the diagnosis of rhabdomyolysis and as there was no history of physical trauma, fever or any other obvious reason for rhabdomyolysis, the diagnosis of post-seizure rhabdomyolysis was kept in our patient. Patient was managed with proper hydration and correction of metabolic parameters but patient had rising trends of renal parameters along with fresh episodes of vomiting. Nephrology consultation was taken and in the view of deteriorating renal parameters, two settings of hemodialysis was done. After hemodialysis, the renal parameters started showing improvement (blood urea; 88,

serum creatinine, 1.7) and same was noted for his CPK level (serum CPK, 284 U/l).

The simultaneous rising and declining trend of CPK level and renal parameters explained the rhabdomyolysis to be the possible cause of renal injury. Hepatitis A, hepatitis E and dengue serology was negative in our patient. Autoimmune parameters like antinuclear antibody (ANA), antineutrophil cytoplasmic antibodies (c-ANCA and p-ANCA) were also normal. He continued to show improvement in his clinical condition and it was associated with improvement in laboratory parameters as well.

Patient was discharged on 12th day of admission with proper advice for compliance of antiepileptic drugs (AEDs). On the day of discharge, patient was conscious and oriented, afebrile, with stable vital parameters. Patient is on regular follow up and compliant to treatment.

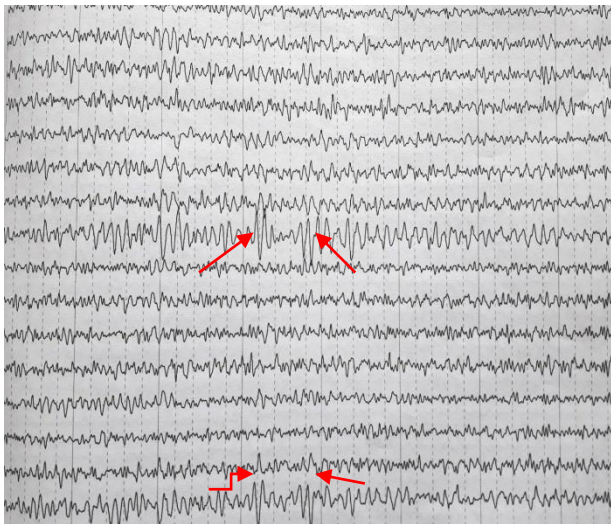


Figure 2: Interictal EEG shows borderline record with intermittent sharp and slow wave activities.

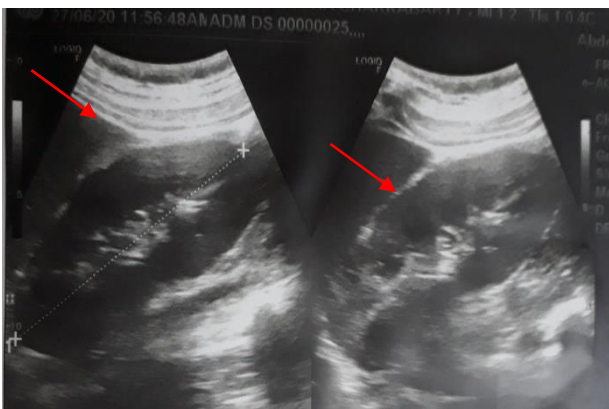


Figure 3: USG Abdomen showing bilateral swollen kidneys with increased cortical echogenicity (right kidney; 12 cm, left kidney; 11 cm).

DISCUSSION

Rhabdomyolysis is a life threatening syndrome characterized by breakdown of skeletal muscle components with subsequent release of these products in the blood and urine. The rhabdomyolysis is associated with a variety of diseases, drugs, toxins and injuries.¹ The diagnosis of rhabdomyolysis is usually made by increased level of serum CPK and increase in urine myoglobin level. The CPK level of more than five times of the normal serum value is required to confirm the diagnosis. Elevated serum myoglobin and myoglobinuria are also reliable parameters for the diagnosis of rhabdomyolysis. The acute renal dysfunction associated with rhabdomyolysis is well known entity. It is seen in up to 33% of the rhabdomyolysis patients and is one of the most serious complications. The free myoglobin in blood causes kidney injury due to renal tubular obstruction and damage as well as due to direct nephrotoxicity. Proper hydration and correction of metabolic acidosis is the mainstay of treatment in these cases.^{5,6} The renal replacement therapy is required, if the conservative treatment fails, and it gives good result if done judiciously.

The rapid and sharp rise in serum creatinine and blood urea level associated with dark coloured urine after single episode of seizure (GTCS), as in our patient suggests that the rhabdomyolysis is possibly due to the seizure associated exertional breakdown of muscle fibers and subsequent release of free myoglobin in blood and urine.⁷ The free myoglobin in blood can cause renal dysfunction due to multiple factors, as suggested by the literature. As there was no history of renal dysfunction in the past and there was rapid rise in blood level of urea and creatinine associated with the evidence of rhabdomyolysis, it strongly suggests that rhabdomyolysis is the causal factor for acute kidney injury.^{7,8}

Other causes of acute kidney injury in our patient were ruled out by negative hepatitis A, E, dengue serology and malaria testing. There was no history of trauma, high grade fever or prolonged bed rest. He also did not have any history of endocrine disease or genetic disorder in the past. The exact pathophysiology of kidney injury associated with rhabdomyolysis is not very clear but the factors associated with acute kidney injury include; associated hypovolemia, presence of metabolic acidosis, and direct nephrotoxic effects of myoglobin. It is also thought as a part of spectrum of the systemic injury associated with rhabdomyolysis as the increase in myoglobin can cause multiple organ dysfunctions as well, including liver dysfunction. Good recovery with symptomatic and supportive treatment is often seen inspite of very high level of blood urea and serum creatinine, something unique to such cases.^{9,10}

These cases need to be recognized early to avoid unnecessary testing as well as for prompt treatment on time. Early diagnosis in such cases has prognostic

implications as these patients have good recovery inspite of significantly deranged renal parameters. Treatment is mostly conservative with regular monitoring of metabolic parameters. If conservative treatment fails, renal replacement therapy is required, as in our case. Although rhabdomyolysis with acute kidney injury, after single episode of generalized seizure is rare entity but it should be kept in mind for timely intervention and better outcome.^{2,4}

CONCLUSION

Rhabdomyolysis is potentially a serious phenomenon and can lead to multiple complications. Acute kidney injury is one of the most serious complications associated with it. Rhabdomyolysis is usually seen after multiple seizure episodes (status epilepticus) due to excessive muscle exhaustion and subsequent muscle injury. It is uncommon to see rhabdomyolysis with acute kidney injury associated with single episode of seizure. High index of suspicion is required to diagnose and treat this entity. Proper treatment can completely revert this potentially life threatening complication.

Funding: No funding sources

Conflict of interest: None declared

Ethical approval: Not required

REFERENCES

1. Khan FY. Rhabdomyolysis: a review of the literature. Netherlands J Med. 2009;67:272-83.
2. Gupta P, Singh VP, Chatterjee S, Agrawal AK. Acute renal failure resulting from rhabdomyolysis following a seizure. Singapore Med J. 2010;51:e79-80.
3. Taly AB, Nair KP, Arunodaya GR, Das S, Christopher R, Mohan C, et al. Non-traumatic acute rhabdomyolysis. Neurol India. 1999;47:51-4.
4. Wang L, Hong S, Huang H, Yang M. Rhabdomyolysis following status epilepticus with hyperuricemia. Medicine (Baltimore). 2018;97:e11281.
5. Bosch X, Poch E, Grau JM. Rhabdomyolysis and acute kidney injury. N Engl J Med. 2009;361:62-72.
6. Hojs R, Ekart R, Sinkovic A, Hojs-Fabjan T. Rhabdomyolysis and acute renal failure in intensive care unit. Ren Fail. 1999;21:675-84.
7. Holt S, Moore K. Pathogenesis of renal failure in rhabdomyolysis: the role of myoglobin. Exp Nephrol. 2000;8:72-6.
8. Al-Ismaili Z, Piccioni M, Zappitelli M. Rhabdomyolysis: pathogenesis of renal injury and management. Pediatr Nephrol. 2011;26:1781-8.
9. Torres PA, Helmstetter JA, Kaye AM, Kaye AD. Rhabdomyolysis: pathogenesis, diagnosis, and treatment. Ochsner J. 2015;15:58-69
10. Gabow PA, Kaehny WD, Kelleher SP. The spectrum of rhabdomyolysis. Medicine. 1982;61:141-52.
11. Luck RP, Verbin S. Rhabdomyolysis review of clinical presentation, etiology, diagnosis and management. Pediatr Emerg Care. 2008;24:262-8.
12. Singhal PC, Chugh KS, Gulati DR. Myoglobinuria and renal failure after status epilepticus. Neurology. 1978;28(2):200-1.

Cite this article as: Pandey S, Borah NC, Dwivedi M, Das RJ. Rhabdomyolysis with acute kidney injury after single episode of generalized seizure in a known case of epilepsy: a case report. Int J Res Med Sci 2020;8:3757-60.