

Original Research Article

Two stage flexor tendon reconstruction in hand: our experience

Tawheed Ahmad¹, Mir Mohsin^{1*}, Mohammad Inam Zaroo¹, Sheikh Adil Bashir¹, Adil Hafeez Wani¹, Haroon Rashid Zargar¹, Altaf Rasool¹, Peerzada Umar Farooq Baba¹, Akram Hussain Bijli¹, Summaira Jan², Saima Rashid³, Shabir Ahmad Langoo², Mushtaq Ahmed Bhat¹

¹Department of Plastic and Reconstructive Surgery, SKIMS, Srinagar, Jammu and Kashmir, India

²Department of Anaesthesiology, SKIMS, Srinagar, Jammu and Kashmir, India

³Department of Anatomy, GMC, Jammu, Jammu and Kashmir, India

Received: 20 September 2016

Accepted: 24 September 2016

*Correspondence:

Dr. Mir Mohsin,

E-mail: m_mohsin@rediffmail.com

Copyright: © the author(s), publisher and licensee Medip Academy. This is an open-access article distributed under the terms of the Creative Commons Attribution Non-Commercial License, which permits unrestricted non-commercial use, distribution, and reproduction in any medium, provided the original work is properly cited.

ABSTRACT

Background: Flexor tendon injuries in the digital flexor sheath area (zone II) are the most difficult to treat and remain a focus of both clinical attention and basic investigations. This prospective study was designed to evaluate the results of staged zone II flexor tendon repair.

Methods: Seventy digits in thirty five patients were treated by Two Stage flexor tendon reconstruction and followed for an average of one and a half year. The procedure included placing a silicone catheter (cut to desire size) as an active implant and reconstruction of A2, A4 or both pulleys if damaged in first stage. During the second stage (performed three to eight months later), tendon graft replaced the silicone catheter in the pseudo sheath formed around the catheter. The proximal end of the transplanted tendon was fixed with flexor digitorum profundus tendon of respective finger using the Pulvertaft method, and the distal end of the graft was fixed with the distal stump of respective flexor digitorum profundus tendon. Early controlled motion protocol was instituted in all cases.

Results: As per Buck Gramcko scale total active motion obtained was Excellent in 70%, Good in 20%, Fair in 7.1%, and Poor in 2.9% of patients.

Conclusions: Flexor tendon reconstruction using two stage tendon reconstructions is an effective way to restore digital tendon function in delayed zone II flexor tendon injuries.

Keywords: Flexor tendon injury, Tendon graft, Staged tendon reconstruction

INTRODUCTION

Reconstruction of scarred flexor tendon system in zone II of hand remains a challenge for a hand surgeon because the healing tendon tends to adhere to its fibro-osseous tunnel. It was termed “no man’s land” by Bunnell because of the poor outcome in range of motion (ROM) following tendon repair in this zone.¹ The outcome is worse in old injuries.

Two-stage flexor tendon reconstruction using a silicone rod in the first stage and a free tendon graft through the

pseudo sheath formed around the silicone rod in the second stage, as described in 1971 by Hunter and Salisbury, is the most widely accepted treatment for poor prognosis patients (Boyes grade 2-5).²⁻¹¹ This article presents our results of two stage zone II flexor tendon reconstruction.

METHODS

This is a prospective study conducted from August 2011 to October 2013 in the department of Plastic and Reconstructive Surgery, SKIMS, Srinagar on 35 patients

with delayed presentation of flexor tendon injury in zone II of digits who underwent 2-stage reconstruction. These included 21 men and 14 women, with an average age of 23 years (ranging from 14 to 50 years). A total of 70 digits (12 index fingers, 22 middle fingers, 22 ring fingers, 12 little fingers and 2 thumbs) were studied. The mechanism of injury included Tin cut in 22 patients, knife cut injury in 8 patients and glass cut injury in 5 patients. Average time elapsed since injury to stage I operation was five and a half months (ranging from 2 to 24 months). All patients followed the same surgical and postoperative procedure.

Operative procedure

It was a two stage tendon reconstruction. All surgeries were performed under General anaesthesia and tourniquet control. Patients underwent aggressive physiotherapy program before and after the first stage to overcome stiffness and achieve maximum passive motion.

Stage I

Brunner's palmer zigzag incisions were made to provide wide exposure of the flexor tendon from the midpalm to the digital tip.¹² The injured tendons and scar tissues were removed. About one centimeter of distal flexor digitorum profundus stump was preserved. Silicone catheter was inserted into the rudimental sheaths. The injured pulleys (A2 and A4) were reconstructed over the implant using excised flexor digitorum superficialis tendon. The distal end of the implant was sutured to the distal stump of flexor digitorum profundus, and the proximal end of the implant was fixed to the proximal stumps of respective flexor digitorum profundus tendon in the palm.

Passive motion exercises were started after one week of surgery. The goal was to achieve full passive flexion at Metacarpophalangeal and interphalangeal joints.

Stage II

Stage II surgery was performed two to six months (average four months) after stage I surgery. A lateral incision at the distal phalanx was used to retrieve the distal stump of the flexor digitorum profundus and the distal end of the silicone rod, and the connecting sutures were divided. An incision at mid of the palm was made to retrieve the proximal junction of the implant and flexor digitorum profundus.

Palmaris longus tendon or plantaris tendon of proper length was procured using a tendon retriever or through multiple small incisions. One end of tendon graft was sutured temporarily to the distal end of the silicone catheter and pulled proximally through the pseudosheath formed around the implant. The distal end of the tendon graft was sutured to the distal stump of flexor digitorum profundus using modified Kessler tendon suturing technique. The proximal end of the graft was sutured with

respective proximal stump of the flexor digitorum profundus tendon using pulvertaft weave suturing method. The tension was adjusted so that the finger was rested in a position slightly more flexed than under normal circumstances. In general, the posture of the grafted digit should be approximately the same as the adjacent ulnar digit, and in the fifth finger, a position of flexion somewhat greater than that of the fifth finger on the opposite hand. At the end of surgery it was ensured that proximal tendon juncture should glide freely on extension of respective digit.

Postoperative care

In the immediate postoperative period, Kleinert's splint was applied with wrist in 30° flexion, metacarpophalangeal joint in 40° flexion and interphalangeal joints kept in neutral position. After 24 hours Kleinert's early active motion protocol was started, with patient doing active extension and passive flexion using rubber band traction, ten times every hour. At bed time, interphalangeal joints were splinted in extension to prevent development of flexion contractures. Four weeks postoperatively, active flexion was started without resistance and dorsal blocking splint was discontinued during day time but continued for night time splintage. Six weeks postoperatively, the splint was discontinued during night as well, and active flexion with progressive resistance exercises was started.

RESULTS

Patients were followed on an average for one and a half year (ranging from 6 to 24 months). The results were measured six months after the stage II surgery. No patient with <6 months of follow-up was included in the study. Assessment of our cases was made based on the total active motion system of evaluation.¹³

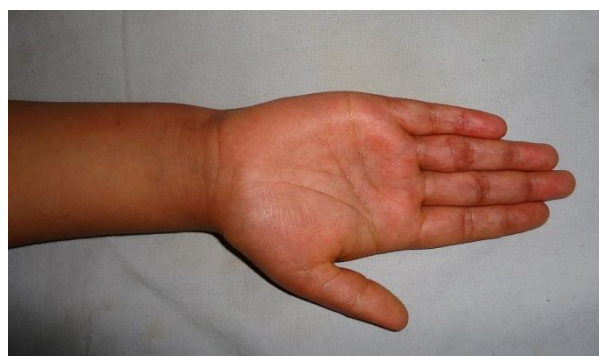

Figure 1: Post tin cut injury scars over volar aspect of PIP joint and proximal phalanges of right middle and ring fingers.

Of the 70 digits operated, Excellent results were seen in 70 percent (49 digits), Good in 20 percent (14 digits), Fair in 7.1 percent (5 digits) and Poor in 2.9 percent (2 digits) (Table 1).

Table 1: Range of motion achieved after 6 months of stage II tendon reconstruction.

Range of motion	Number of digits	Percentage
85-100° (Excellent)	49	70
70-84° (Good)	14	20
50-69° (Fair)	5	7.1
0-49° (Poor)	2	2.9
Total	70	100

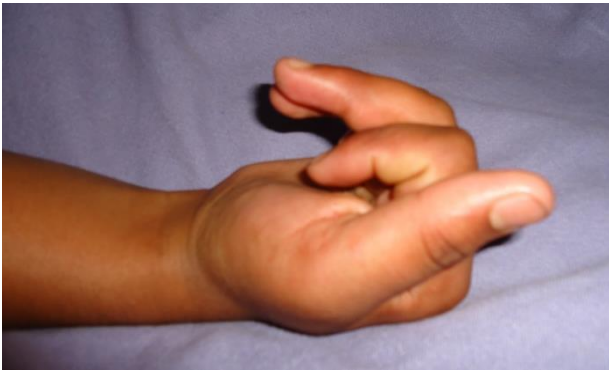

Figure 2: Middle and Ring fingers out of flexion cascade.

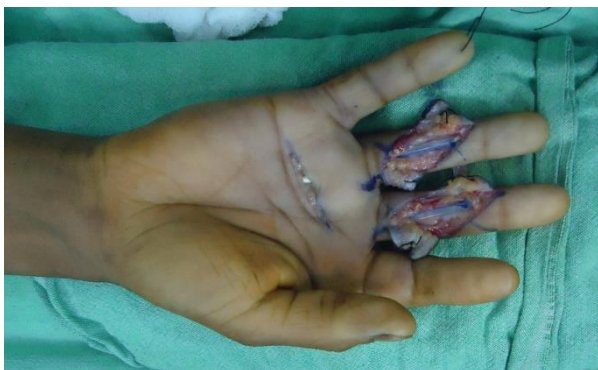

Figure 3: Stage I tendon reconstruction in progress with silicone tubes in situ.

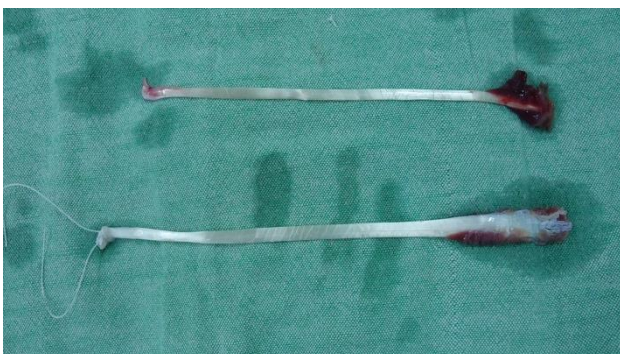

Figure 4: Palmaris longus tendon grafts harvested during second stage tendon reconstruction.

Infection was observed in two patients after stage I surgery. In one patient *Staphylococcus aureus* was

cultured and in other patient pseudomonas was cultured. In first patient the silicone rod was removed and in the other patient, the infection responded well to conservative treatment. Silicone rod got exposed in 2 patients. In one patient, exposed rod was salvaged by a cross finger flap. In another patient, exposed rod had to be removed. None of our patients had any skin necrosis, rod buckling, silicone synovitis, proximal or distal graft tenorrhaphy rupture.

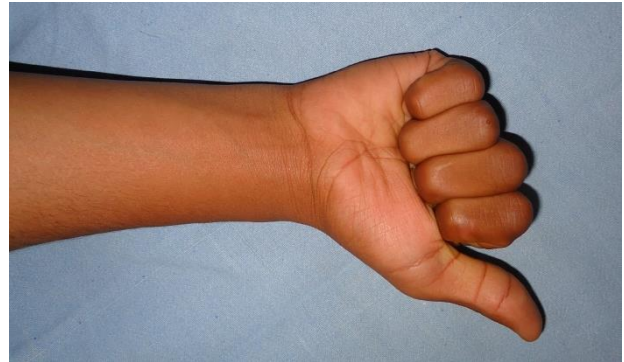


Figure 5: Follow up after 6 months of stage II; flexion cascade restored.

DISCUSSION

Old flexor tendon injuries, especially in zone II, are usually associated with complications such as retraction of proximal and distal ends of tendon, adhesion formation and collapse of the osseo-fibrous canal. Therefore, tendon grafting is usually needed to restore the flexion function of digits.

In the 1950s, Bassett and Carroll began using flexible silicone rubber rods to build a pseudo-sheath in badly scarred fingers and the method was later refined to a staged reconstruction of the digital flexor tendons by Hunter and Salisbury.^{2,14} This procedure was used for patients who had their flexor digitorum profundus, flexor digitorum superficialis, and tendon sheath all severely injured, especially in zone II, and it effectively decreased adhesion formation. Hunter's technique is worthwhile for delayed flexor tendon injury in zone II to prevent adhesion formation.²⁻¹¹

The main complications of staged flexor tendon reconstruction include adhesion formation, infection, skin necrosis, rod buckling, silicone synovitis, tenorrhaphy rupture and silicone rod exposure. In our series, the infection rate was 2.85%.

Adhesion formation after stage II can be minimized by strictly following early active motion protocol.^{15,16} After tendon repair, two mechanisms for healing are involved: extrinsic and intrinsic. The extrinsic mechanism is predominantly mediated by an influx of synovial fibroblasts and inflammatory cells from outer sheath, while intrinsic healing occurs via fibroblasts and

inflammatory cells from the epitenon. Extrinsic mechanism of healing is mainly responsible for adhesion formation. Early active controlled exercise protocols promote tendon healing through intrinsic mechanism and thus prevent adhesion formation.

The pseudo-sheath formed after stage I around the silicone rod implant provide a smooth tunnel for tendon graft to glide, so chances of adhesion formation within this tunnel are minimal. In our series, all 35 patients (70 digits) received early controlled exercise protocol and hence good results were achieved.

To retain good digital function, pulley reconstruction is important. The pulley system, especially A2 and A4 pulleys, are responsible for preserving digital motion and finger strength. Loss of the integrity of these pulleys results in bowstringing.¹⁷ In our study we reconstructed A₂ and A₄ pulleys using remnants of flexor digitorum superficialis tendon in first stage of tendon reconstruction.

CONCLUSION

Two-stage flexor tendon reconstruction technique is an effective method of reconstruction of a scarred flexor tendon system in zone II of hand, yielding a high rate of excellent and good results with fewer complications.

ACKNOWLEDGEMENTS

Authors would like to acknowledge the support provided by the Ex Head of our Department Prof MA Darzi in conducting this study.

Funding: No funding sources

Conflict of interest: None declared

Ethical approval: The study was approved by the Institutional Ethics Committee

REFERENCES

1. David G, Robert S. Flexor tendon injuries and reconstruction. In: Stephen J Mathes and Vincent R Hentz. Text book of plastic surgery, second edition. Saunder Elsevier; 2006:352.
2. Hunter JM, Salisbury RE. Flexor-tendon reconstruction in severely damaged hands. A two-stage procedure using a Silicone-dacron reinforced gliding prosthesis prior to tendon grafting. J Bone Joint Surg Am. 1971;53:829-58.
3. Courvoisier A, Pradel P, Dautel G. Surgical outcome of one-stage and two-stage flexor tendon grafting in children. J Pediatr Orthop. 2009;29(7):792-6.
4. Unglaub F, Bultmann C, Reiter A, Hahn P. Two-staged reconstruction of the flexor pollicis longus tendon. J Hand Surg Br. 2006;31:432-5.
5. Smith P, Jones M, Grobbelaar A. Two-stage grafting of flexor tendons: results after mobilisation by controlled early active movement. Scand J PlastReconstrSurg Hand Surg. 2004;38:220-7.
6. Beris AE, Darlis NA, Korompilias AV, Vekris MD, Mitsionis GI, Soucacos PN. Two-stage flexor tendon reconstruction in zone II using a silicone rod and a pedicled intrasynovial graft. J Hand Surg Am. 2003;28:652-60.
7. Soucacos PN. Secondary flexor tendon reconstruction. In: Duparc S, ed. Textbook on Techniques in Orthopaedic Surgery and Traumatology. Paris, France: Elsevier SAS; 2000:55-340.
8. Strickland JW. Development of flexor tendon surgery: twenty-five years of progress. J Hand Surg Am. 2000;25:214-35.
9. Viegas SF. A new modification of two-stage flexor tendon reconstruction. Tech Hand Up Extrem Surg. 2006;10:177-80.
10. Darlis NA, Beris AE, Koromphilias AV, Vekris MD, Mitsionis GI, Soucacos PN. Two-stage flexor tendon reconstruction in zone 2 of the hand in children. J Pediatr Orthop. 2005;25:382-6.
11. Valenti P, Gilbert A. Two-stage flexor tendon grafting in children. Hand Clin. 2000;16:573-8.
12. Bruner JM. The zig-zag volar-digital incision for flexor-tendon surgery. Plast Reconstr Surg. 1967;40(6):571-4.
13. American Society for Surgery of the Hand (ASSH). Clinical Assessment Committee Report. Rosemont, IL: Churchill Livingstone; 1976.
14. Bassett CAL, Carroll RE. Formation of tendon sheaths by silicone rod implants. Proceedings of American Society for Surgery of the Hand. J Bone Joint Surg Am. 1963;(45):884.
15. Khanna A, Friel M, Gougoulias N, Longo UG, Maffulli N. Prevention of adhesions in surgery of the flexor tendons of the hand: what is the evidence.Br Med Bull. 2009;(90):85-109.
16. Khanna A, Gougoulias N, Maffulli N. Modalities in prevention of flexor tendon adhesion in the hand: what have we achieved so far? Acta Orthop Belg. 2009;75(4):433-44.
17. Rispler D, Greenwald D, Shumway S, Allan C, Mass D. Efficiency of the flexor tendon pulley system in human cadaver hands. J Hand Surg Am. 1996;21(3):444-50.

Cite this article as: Ahmad T, Mohsin M, Zaroo MI, Bashir SA, Wani AH, Zargar HR, et al. Two stage flexor tendon reconstruction in hand: our experience. Int J Res Med Sci 2016;4:4697-700.