

Case Report

Oncocytic carcinoma of minor salivary gland: a case report

Sagarika Samantaray, Sasmita Panda, Sashibhusan Dash*, Niranjana Rout

Department of Pathology, A. H. Regional Cancer Centre, Cuttack, Orissa, India

Received: 17 October 2016

Revised: 21 October 2016

Accepted: 11 November 2016

***Correspondence:**

Dr. Sashibhusan Dash,

E-mail: sashibiotech@gmail.com

Copyright: © the author(s), publisher and licensee Medip Academy. This is an open-access article distributed under the terms of the Creative Commons Attribution Non-Commercial License, which permits unrestricted non-commercial use, distribution, and reproduction in any medium, provided the original work is properly cited.

ABSTRACT

Oncocytic carcinoma is an extremely rare malignancy of minor salivary gland. The biological behaviour, management and prognosis are not well established due to its rarity and paucity of published literature. We report a case of 32 year old man presented an ulcerated growth measuring 1cm in size in right buccal mucosa along with enlarged left submandibular lymphadenopathy. The diagnosis was suggestive of oncocytic carcinoma of minor salivary gland by cytology and subsequently confirmed by excisional biopsy.

Keywords: Buccal mucosa, Oncocytic carcinoma, Salivary gland

INTRODUCTION

Oncocytic carcinoma is an extremely rare malignancy in salivary glands, accounting only for 11% of all oncocytic salivary gland neoplasms, 0.5% of all epithelial salivary gland malignancies and 0.18% of all epithelial salivary gland tumors. This neoplasm is characterized by epithelial cells with abundant eosinophilic and granular cytoplasm, filled with numerous mitochondria.¹ Most cases are originate from the major salivary glands, while the minor salivary glands are rarely involved.²

The biological behavior, management and prognosis of oncocytic carcinomas are not well established due to their low incidence and paucity of published literature. Here we report a rarest case of oncocytic carcinoma arising from right site buccal mucosa diagnosis by cytology and subsequently confirmed by excisional biopsy.

CASE REPORT

A 32 year old man presented a painless growth in right buccal mucosa along with enlarged left submandibular lymphadenopathy of two months duration. Physical examination revealed an ulcerative fixed hard 1 × 1 cm

mass in right buccal mucosa with submandibular lymphadenopathy (Figure 1a).

Hemogram and biochemical parameters were within normal limit. Cytosmear from the lesion showed presence of round to oval cells arranged in sheets and acini. (Figure 1b H & E stain 100X) Cells are pleomorphic having abundant amount of eosinophilic cytoplasm and prominent nucleoli (Figure 1.c H & E stain 400X). There was no lymphocyte or any cellular debris in the background. Lymph node aspirates revealed features of reactive hyperplasia. Thus the cytological diagnosis was suggested of oncocytic carcinoma of minor salivary gland without nodal or distant metastasis. Ultrasonography and computed tomography reports were unremarkable.

Subsequently right cheek commedo operation was done. Gross examination revealed a well-circumscribed, firm; grey white tumor measuring (1.5x1.8cm) in diameter. Hematoxylin & Eosin (H&E) stained on resected micro section showed stratified squamous epithelium and underlying tumor tissue arranged in solid sheets, nests, acini and cords. Infiltration of overlying epithelium, bone and connective tissue stroma seen. The tumor cells were large, round to polyhedral with central to peripherally

located nuclei and prominent nucleoli. Cytoplasm was abundant, eosinophilic and granular. Mild degree of nuclear pleomorphism noted. All the nodes showed reactive hyperplasia (Figure 1d 100 X). With this the diagnosis of oncocytic carcinoma of minor salivary gland was confirmed. Post operatively there was no complication and no sign of recurrence up to 1 year follow up.

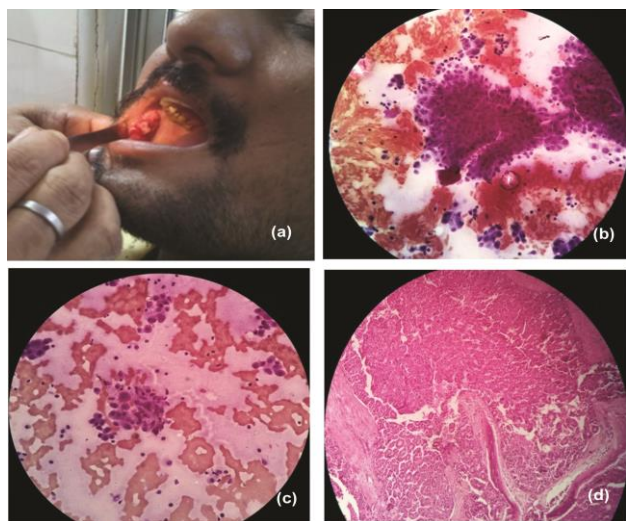


Figure 1: (a) An ulcerated growth measuring 1cm in size in right buccal mucosa; (b) Cytology H & E stain: 100 X ; presence of round to oval cells arranged in sheets and acini; (c) Cytology H & E stain: 400 X; Cells are pleomorphic having abundant amount of eosinophilic cytoplasm and prominent nucleoli; (d) HP section; 100 X: tumour cells are arranged in solid sheets, nests, acini and cords. Infiltration of overlying epithelium, bone and connective tissue stroma by the tumor tissue.

DISCUSSION

Oncocytic carcinoma is a malignant epithelial salivary gland tumor characterized by oncocytes. The term “oncocyte” was first used by Hamperl in 1931 to describe cells with abundant, finely granular, eosinophilic cytoplasm.

Oncocytes are most abundant in the parotid gland; they are also found in other major and minor salivary glands as well as in the larynx, trachea, bronchi, oesophagus, nasal mucous membranes, thyroid, parathyroid, pancreas, liver, and stomach. Although focal oncocytic features are seen in a wide variety of salivary neoplasms, pure oncocytic carcinoma of salivary gland origin is rare and rarest when it arises in minor salivary gland.² Bauer and Bauer reported the first case in 1953.³ The malignant nature of the neoplasm can be recognized by its morphologic features and infiltrative growth. Morphologic criteria for the diagnosis of a malignant nature are cellular pleomorphism, necrosis and frequent mitoses. Infiltrative growth of the neoplasm is

represented by perineural, vascular or lymphatic invasion, destruction of adjacent structures and local lymph node metastasis.¹ This tumor is predominantly composed of round or polyhedral cells arranged in small clusters and occasional solid sheets. The average age of the patients has been estimated to be about 60years with a male predominance.⁴

Though, few symptoms and signs may suggest malignancy, most malignant salivary gland lesions cannot be differentiated from their benign counterparts on clinical criteria alone. The management of almost all neoplastic salivary gland lesions is surgical excision, a pre-operative diagnosis of benign or malignant assists the clinician in planning the extent of surgery.⁵

Fine needle aspiration cytology (FNAC) is a popular method for diagnostic evaluation of salivary gland masses due to their superficial nature and easy accessibility. But it is less sensitive for oncocytic neoplasm, perhaps due to the rarity of these tumors and diagnostic pitfall previously associated with FNAC (for example, sampling error and over interpretation of paucicellular specimen).^{4,5}

In present case diagnosis was suggestive of oncocytic carcinoma of minor salivary gland without nodal or distant metastasis as cytosmear showed, presence of round to oval cells arranged in sheets and acini. Cells are pleomorphic having abundant amount of eosinophilic cytoplasm and prominent nucleoli and subsequently confirmed in H&E stain tissue section as it showed cellular pleomorphism, mitosis, necrosis and invasion of bone and surrounding stroma. Thus the diagnosis was confirmed as primary oncocytic carcinoma of minor salivary gland without nodal or distant metastasis.

Surgical excision is the widely accepted method of treatment. The prognosis of oncocytic carcinoma in salivary gland is not well known, because of its rarity. Goode and Corio emphasized that aggressive surgical intervention at initial presentation seems to offer a more favorable prognosis. Presence of distant rather than local lymph node metastasis and tumors smaller than 2 cm in diameter appeared to have a better prognosis than those that were larger.⁶ In our case the tumor was 1.8cm size and nodal or distant metastasis was not seen, for which a good prognosis expected here.

CONCLUSION

FNAC/scrape cytology is safe, rapid and cost effective preoperative diagnostic method of benign or malignant salivary lesion to assist the clinician in planning the extent of surgery by which the better prognosis can be expected.

Funding: No funding sources

Conflict of interest: None declared

Ethical approval: Not required

REFERENCES

1. Giordano G, Gabrielli M, Gnetti L, Ferri T. Oncocytic carcinoma of parotid gland: a case report with clinical, immunohistochemical and ultrastructural features. *Wor J Surg Onco.* 2006;4:54.
2. Chhabra S, Singh S, Sethi D, Mahapatra QS. Oncocytic carcinoma of lip: A rare neoplasm of minor salivary gland. *J Cytol.* 2012;29:69-71.
3. Bauer WH, Bauer JD. Classification of glandular tumours of the salivary glands. Study of 143 cases. *Arch Pathol Lab Med.* 1953;55:328-46.
4. Gallego L, García-Consuegra L, Fuente E, Calvo N, Junquera L. Oncocytic carcinoma of the parotid gland with late cervical lymph node metastases: a case report. *Journal of Medical Case Reports.* 2011;5:11.
5. Jain R, Gupta R, Kudesia M, Singh S. Fine needle aspiration cytology in diagnosis of salivary gland lesions: A study with histologic comparison. *Cytojournal.* 2013;10:5.
6. Goode RK, Corio RL. Oncocytic adenocarcinoma of salivary glands. *Oral Surg Oral Med Oral Pathol.* 1988;65:61-6.

Cite this article as: Samantaray S, Panda S, Dash S, Rout N. Oncocytic carcinoma of minor salivary gland: a case report. *Int J Res Med Sci* 2016;4: 5501-3.