

Case Report

Actinomycotic lid abscess: a rare presentation

Sumita Karandikar¹, Sangram Karandikar², Tanveer Parvez Shaikh^{2,*}, Sharique Ansari²

¹Department of Ophthalmology, ²Department of Surgery, DY Patil College of Medicine, Nerul, Navi Mumbai, India

Received: 04 April 2015

Revised: 24 April 2015

Accepted: 06 May 2015

***Correspondence:**

Dr. Sangram Karandikar,

E-mail: sangkaran@hotmail.com

Copyright: © the author(s), publisher and licensee Medip Academy. This is an open-access article distributed under the terms of the Creative Commons Attribution Non-Commercial License, which permits unrestricted non-commercial use, distribution, and reproduction in any medium, provided the original work is properly cited.

ABSTRACT

Actinomycosis is a gram positive filamentous branching anaerobic bacilli that is difficult to isolate and identify. We present this case of a 15 year old patient who developed repeated infection over a contused lacerated wound (CLW) on forehead. Cytology revealed Actinomycosis. He subsequently developed upper eyelid actinomycotic inflammatory swelling. Modified Welsh treatment was started and five months of therapy resulted in complete resolution of the infection. Hence any wound with repeated infection should be examined for Actinomycosis. When identified at the right time, such infections show dramatic response to Modified Welsh Therapy.

Keywords: Actinomycosis, Upper lid swelling, Modified Welsh Therapy, infected CLW

INTRODUCTION

Actinomyces species is a gram-positive, non-acid-fast, non-spore-forming anaerobic bacillus that is difficult to isolate and identify.¹ Its filamentous growth and mycelia like colonies have a striking resemblance to fungi, usually arranged in hyphae, but can fragment into short bacilli and it is very rare organisms found in ophthalmic practice. They are oral commensals, giving rise to opportunistic infection on disruption of normal mucosal barrier. The organisms are trapped in concretions adherent to the tissue elements. These concretions are also known as "sulfur granules".² We are reporting this case as few cases of actinomycotic canaliculitis, keratitis have been reported, but actinomycotic lid abscess is extremely rare.

CASE REPORT

A 15 year old male patient came with complaints of redness and swelling of right upper eyelid since 8 days which was not associated with pain or other ocular complaints. He had history of contused lacerated wound over right side of forehead two years back, followed by abscess formation at the site of the wound, thrice, leading

to discharging sinus. Routine culture and sensitivity showed no growth and Cytology reports revealed colonies of actinomyces. CT scan at the time showed signs suggestive of acute osteomyelitis. The patient was allergic to injectable Penicillin and therefore was put on tablet Amoxicillin with clavulanic acid since two months by a private practitioner but showed no improvement. There was no history of fever, associated ear, nose, throat or dental complaints or any other systemic infections. On examination, vision in both eyes was 20/20. There was localized swelling in right upper eyelid, approximately 3 x 2 x 1.5 cm in size, soft in consistency, associated with erythema and local rise of temperature (Figure 1). There was no pus point or discharging sinus over it. Ocular examination was within normal limits. An open infected wound was seen on right side of forehead, approximately 3 cm above eyebrow. FNAC from the lid abscess was sent for culture, sensitivity, Gram and AFB staining and cytology. Cytology examination revealed A. eriksoni organism. The MRI of orbit revealed a right side abnormal well defined lobulated lesion measuring approximately 3 x 1.5 x 1.5 cm in the preseptal space, compressing the scleral margin of the globe, but no extension into the right globe, intra or extraconal or the intracranial cavity along with infective osteomyelitis in the frontal calvarium (Figure 2). FNAC did confirm A.

eriksoni, but based on clinical grounds, we considered this lid abscess to be actinomycotic and Modified Welsh's Regime was started as patient was allergic to Penicillin. This regime consisted of injection Amikacin IV 500 mg (morning) and 250 mg (evening), Tab Co-trimoxazole twice daily, and Tab Rifampicin 600mg once daily before breakfast for twenty one days. The lesion regressed dramatically on subsequent follow ups (Figure 3). An audiometry was done at the end of twenty one days to rule out ototoxicity. Two weeks wash out period was given for Amikacin, after which another cycle of twenty one days was given. Maintenance therapy consisted of Oral Co-trimoxazole and Rifampicin for three months. At five month follow up, the forehead and eyelid lesions had completely healed with no recurrence (Figure 4).

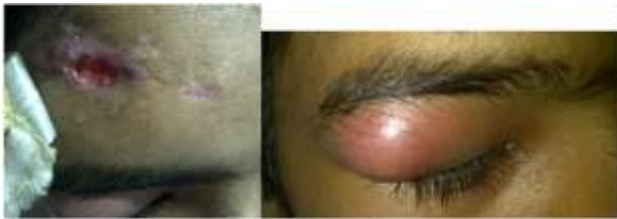

Figure 1: Open infected wound on right side of forehead (above) & Localized swelling of right upper lid.

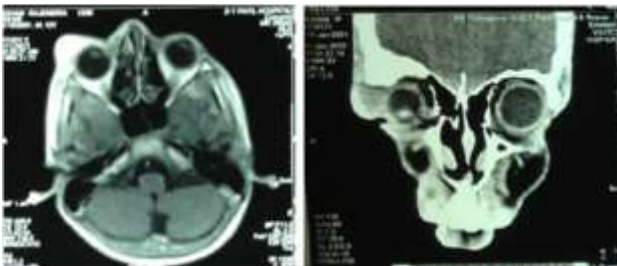


Figure 2: An MRI of Orbit showing right sided lobulated lesion in preseptal space. There is no extension into right globe, intro or extra conal space (Above).

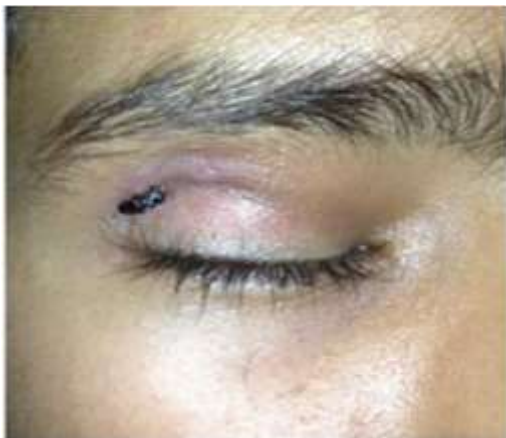

Figure 3: Dramatic regression of lesion on subsequent follow up.

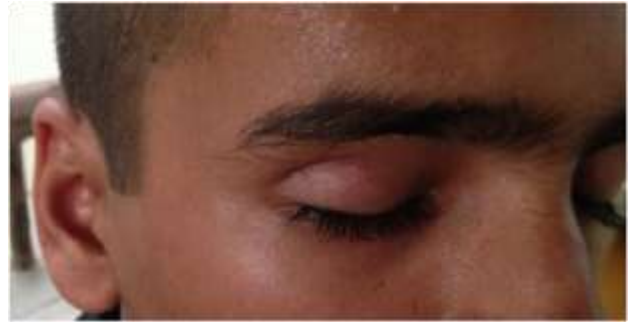

Figure 4: Lesions have completely healed at 5 month follow up.

DISCUSSION

Human Actinomycosis, caused by Actinomyces group of organisms, is a very rare occurrence.^{1,3,5} Out of the reported cases, *A. israelii* is the commonest organism^{1,5} others being *A. eriksoni*,⁵ *A. naeslundii*, *A. meyeri*, *A. viscosus*, *A. odontolyticus* and *A. pyogenes*.^{5,6} Actinomyces are present in the human oropharynx, particularly around teeth, alimentary and genital tract as commensals and give rise to an opportunistic infection when the mucosal barriers are broken in surgery, trauma or infection. Being strict anaerobes, they penetrate deeper and thrive in tissues where an anaerobic environment exists. Cervicofacial (most often lower jaw), thoracic, abdominal (ileocaecal region), pelvic (associated with application of Intrauterine devices) are the various presentations of the disease.⁵ The lesions are usually indurated painless swellings with multiple discharging sinuses and surrounded by thick fibrous tissue. Pus contains yellow sulphur granules of actinomyces colonies.⁵ The most common site involving the eye is the lacrimal system, frequently involving lower canaliculus. It may be primary or secondary to jaw infection. Epiphora, followed by nodular swelling, ulcer, discharging fistula containing yellow or greenish pus are the various presentations. Less frequently, Actinomycosis may cause conjunctivitis, keratitis, corneal ulcer, iritis, endophthalmitis and proptosis due to orbital involvement.^{6,7} Orbital Actinomycosis may occur due to direct spread from infections of oral cavity, infra temporal fossa, paranasal sinuses or ocular adnexa.^{1,3} It usually presents as painless proptosis with restricted extra ocular movements.¹

Differential diagnosis in this case would have been preseptal cellulitis. Due to presence of documented evidence of Actinomycotic osteomyelitis of right side frontal bone, roof of orbit and the lesion being painless, well defined lobulated abscess, Actinomycotic lid abscess was thought to be the most probable diagnosis, presumably secondary to actinomycotic osteomyelitis. High dose Penicillin is the mainstay of treatment. Clindamycin or Chloramphenicol is given for patients with allergy to Penicillin.¹ More recently, various antimicrobial combinations that have been found useful include Co-trimoxazole -Streptomycin, Co-trimoxazole -

Amikacin, Co-trimoxazole-Penicillin, Dapsone - Amikacin, etc.^{8,9} “Ramam M et al proposed a two- step regime: Intensive Phase of 5-7 weeks consisting of four injections of Penicillin and two injections of Gentamycin daily. Maintenance phase consisted of Amoxicillin/ Doxycycline and Co-trimoxazole for 2 to 5 months after complete healing.^{9,10} “Welsh Regime consists of simultaneous administration of IV Amikacin (15 mg/ Kg/ day) in two divided doses for three weeks along with Oral Co-trimoxazole for five weeks with intervening two week wash out period for Amikacin.^{8,11} In Modified Welsh regime daily oral Rifampicin (10 mg/ Kg/day) is added to Welsh Regime, with a maintenance phase of Co-trimoxazole for three months. Rifampicin induces earlier remission.¹² In our case as the patient is allergic to penicillin, modified Welsh regime, as mentioned earlier, was used with great success and no recurrence till date.

CONCLUSION

Any wound with repeated infection and discharging sinuses must be investigated for Actinomycosis. Early diagnosis helps in appropriate treatment, reducing the morbidity due to this rare organism.

Funding: No funding sources

Conflict of interest: None declared

Ethical approval: Not required

REFERENCES

1. Sullivan TJ, Aylward GW, Wright JE. Actinomycosis of the orbit. Br J Ophthalmol 1992; 76:505-6.
2. Shah JK (1971) Actinomycosis: a ten year review. East Afr Med J 1971; 48: 496-501.
3. Karcioğlu ZA. Actinomyces infection in porous polyethylene orbital implant. Graefes Arch Clin Exp Ophthalmol 1997; 235: 448-51.
4. Hegde V, Puthran N, Mahesha S, Anupama B. A rare and an unusually delayed presentation of orbital actinomycosis following avulsion injury of the scalp. Indian J Ophthalmol 2010;58:238-40.
5. Chakraborty P. A Textbook of Microbiology 2^{Ed}. New Central book Agency. 2006.
6. Vrabec MP, Florakis GJ. Actinomyces organisms in ocular disease. in Duane's Ophthalmology on CD - ROM. Philadelphia: Lippincott Williams and Wilkins; 2000.
7. Pine L, Hardin H. Turner L, Robert S. Actinomycotic lacrimal canaliculitis. Am J Ophthalmology 1960; 49:1278.
8. Praveen Kumar S et al. An unusual presentation of primary cutaneous nocardiosis at a rare site: successful treatment with a modified Welsh regimen. Dermatol Online J. 2011; 17 (12): 1.
9. Chavez G, Estrada R, Bonifaz A. Perianal actinomycetomas experience of 20 cases. Intl J Dermatology, 2002; 41:491 -3.
10. Shanbag NU Karandikar S, Deshmukh PA. Disseminated orbital Actinomycetoma: A Case Report. Indian J Ophthalmol: 2010;58: 60-63.
11. Kaliswaran A.V., Senthamilselvi G., Janaki C., Janaki V.R Therapeutic response in mycetoma - A study of different regimes Indian J Dermatol . 2003; 48(3), 154-59.
12. Mahajan P.M., Pradhan S.N Belgaumker V.A., Gosavi A.P. et al Modified Welsh regimen: A promising therapy for actinomycetoma. Journal of drugs in dermatology. Sept 2008; 7(9):853-6.

DOI: 10.18203/2320-6012.ijrms20150187

Cite this article as: Karandikar S, Karandikar S, Shaikh TP, Ansari S. Actinomycotic lid abscess: a rare presentation. Int J Res Med Sci 2015;3:1545-7.