

## Case Report

# Lavage through malpositioned nasogastric tube: a cause of concern

Rajendra Prasad Takhar<sup>1\*</sup>, Motilal Bunkar<sup>1</sup>, Savita Arya<sup>2</sup>, Rama Kishan Saran<sup>3</sup>

<sup>1</sup>Department of Respiratory Medicine, Government Medical College, Kota, Rajasthan, India

<sup>2</sup>Department of Dermatology, Government Medical College, Kota, Rajasthan, India

<sup>3</sup>Department of Surgery, Dr. S N Medical College, Jodhpur, Rajasthan, India

**Received:** 21 October 2015

**Revised:** 02 November 2015

**Accepted:** 20 November 2015

### \*Correspondence:

Dr. Rajendra Prasad Takhar,

E-mail: [drrajtakhar@gmail.com](mailto:drrajtakhar@gmail.com)

**Copyright:** © the author(s), publisher and licensee Medip Academy. This is an open-access article distributed under the terms of the Creative Commons Attribution Non-Commercial License, which permits unrestricted non-commercial use, distribution, and reproduction in any medium, provided the original work is properly cited.

### ABSTRACT

Nasogastric tube (NGT) placement is a frequently used procedure in intensive care units either for enteral feeding or in cases of poisoning, where it is an important and emergent tool for gastric irrigation. Although, insertion of NGT has been pronounced as being easy and without risks, the increasing prevalence of the use of enteral feeding tubes during critical illness leads to the increased potential for malpositioning of a nasogastric tube. It is more hazardous if any therapeutic procedure has been performed through these malpositioned nasogastric tubes. Here, we are describing a unique case of malpositioning of nasogastric tube into left main bronchus in a case of unknown drug poisoning. The consequences of malposition of NGT, lavage through this NGT leading to grave respiratory complications and significance of a check x-ray chest following tube placement are discussed here.

**Keywords:** Nasogastric tube, Malposition, Respiratory complication

### INTRODUCTION

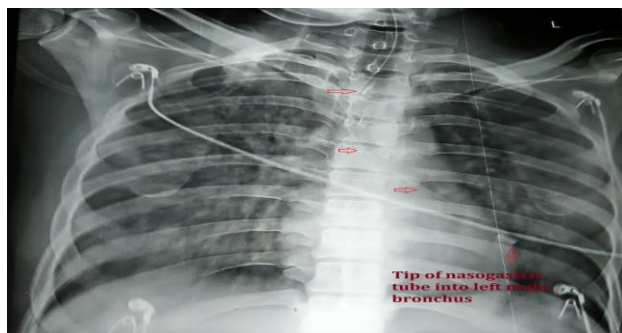
Enteral feeding is increasing for nutritional support in various groups of patients, including critically ill, long term ventilator support and burn patients. Also, NGT is used for medication and for gastric lavage in cases of poisoning. The NGT insertion is a frequently performed procedure in the emergency department as it is easy to perform, requiring little training/ experience and usually uneventful when implemented precociously. The exact incidence of malposition of NGT is unknown, but it ranges from 2 to 2.5%.<sup>1</sup> There are few complications occurs either due to NGT itself /malposition or during their insertion and removal. These include nasal bleed or sinusitis to fetal complication as perforation of oesophagus or tracheobronchial tree, laryngeal edema with asphyxia ("NGT-syndrom"), pulmonary aspiration and pneumothorax.<sup>2</sup> Apart from complications associated

with malpositioning, insertion or withdrawal, certain more perilous complication can occur if any therapeutic procedure performed through these misplaced NGTs. Here, we are discussing a exceptional case of malpositioning of NGT in the left main bronchus. Further, the consequences of malposition and development of solemn respiratory complications in the form of acute respiratory distress syndrome are discussed here.

### CASE HISTORY

A 25 years old male patient brought to the emergency department with history of unknown poison ingestion. His consciousness level was severely impaired. All vitals were stable and chest auscultation was normal. A soft nasogastric tube of size 16 French gauge without guide wire was inserted nasally very smoothly for gastric

lavage. The NGT was introduced up to the 50 cm mark without any gratuitous resistance. The patient didn't produce cough during the whole procedure, therefore no suspicion of malposition was aroused. Further, the proper positioning of the NGT in the stomach was confirmed by insufflations of air and epigastric auscultation, which suggested a correct position. Assuming NGT in stomach, a gastric lavage was performed through the NGT with five hundred milliliter of normal saline but to fail and no return of fluid was attained. Suddenly, patient's condition deteriorated with vigorous coughing and saturation drop. Examination revealed diffuses crepitations mainly over the left side of hemi thorax. At this time malposition of NGT was suspected, but repeat epigastric auscultation was normal. Then urgent chest x-ray advised which showed the incorrect placement of nasogastric tube into left main stem bronchus with bilateral diffuse pulmonary infiltrates suggestive of acute respiratory distress syndrome (Figure 1). The nasogastric tube was removed immediately and re-introduced correctly which was confirmed by repeat chest x-ray. The patient was managed conservatively with right placement of NGT, mechanical ventilator support along with symptomatic and supportive treatment. He weaned off from ventilator after four days and discharged successfully.



**Figure 1: Chest X-ray PA view showing path of nasogastric tube (horizontal arrows) with its tip in the left lower lobe bronchus (Vertical arrow). Diffuse, bilateral alveolar infiltrates consistent with ARDS are also seen.**

## DISCUSSION

Insertion of NGT either for feeding or gastric lavage is a common practice in many clinical conditions like critically ill patients, unknown poisoning cases, comatose, burn persons and patients with head and neck malignancy as they have upper aero-digestive tract obstruction. Comatose patients had impaired cough and gag reflexes so the risk of misplacement increases. The anatomy of the upper respiratory and digestive tracts assists broncho-pulmonary complications of NGT placements. The close proximity of the larynx and the upper esophageal sphincter may lead to malposition of the NGT especially in patients with reduced consciousness and protective reflexes. Furthermore, the close proximity of the esophagus and very thin

membranous part of the trachea may predispose to perforations.<sup>3</sup>

Complications secondary to misplaced NGT are seen mainly in elderly, mentally unsound, neurologically impaired and comatose patients. Pulmonary complication includes serious injuries to the tracheobronchial pleural tract, such as pneumothorax, subcutaneous and mediastinal emphysema, lung abscess, pleural effusion, pneumonia and even death.<sup>4</sup> ARDS is very rarely known complication of NGT as seen in our case that also due to lavage and not a complication of NGT itself.

There are various radiographic and non-radiographic methods to confirm the position of NGT. The non-radiographic method includes aspiration of gastric fluid, measurement of fluid PH, air insufflations and epigastric auscultation. However, these are not confirmatory tests as they may give false interpretation. Aspiration of fluid from NGT may come from the pleural space, bronchial secretions or even stomach. The air insufflation and epigastric auscultation are also not acceptable confirmation test because this sound may originate from 1) small bore tubes due to insufficient air transfer 2) vigorous peristalsis movement of intestine may be mistaken as insufflated air 3) air bubbling in the pleura, lung, pharynx or oesophagus may be transmitted below the diaphragm as seen in our case. Luo RB et al,<sup>5</sup> mentioned that neither auscultation of bubbling sounds from the epigastrium after insufflation of air, nor aspiration of 'gastric content' is thought to be reliable, they propose the measuring the level of carbon dioxide in the feeding tube as a simple way to confirm NGT malposition.

Among radiographic methods chest x-ray is the most accurate, although not a watertight method to authenticate proper nasogastric feeding tube placement. There are four radiological signs that indicate the right position of NGT; 1) NGT path follows the oesophagus, 2) the tube bisects the carina, 3) tube crosses the diaphragm in the middle and 4) tip of the tube lies below the left hemi diaphragm.<sup>6</sup>

Few more methods are available to control the correct position of the tube: measurement of bilirubin in the aspirate and endoscopy, however in day to day practice these methods did not find broad acceptance and still the chest x-ray after the NGT placement remains the gold standard.

Learning points from this case are:

- 1) Insertion of the NGT is an unavoidable procedure in emergency department for rapid relief in cases of abdominal distension and unknown poisoning.
- 2) Failure to identify a malpositioned NGT in the trachea or any of the main bronchus may lead to fatal pulmonary complications. Hence, it is advisable to

confirm radiographically before starting enteral feeding, gastric lavage or medications.

- 3) This case accentuates the significance of making clinicians aware about the potential morbidity and mortality associated with a simple procedure.

*Funding: No funding sources*

*Conflict of interest: None declared*

*Ethical approval: Not required*

## REFERENCES

1. Sorokin R, Gottlieb JE. Enhancing patient safety during feeding-tube insertion. A review of more than 2000 insertions. J Parenter Enteral Nutr. 2006; 30:440-5.
2. Pillai JB, Vegas A, Brister S. Thoracic complications of nasogastric tube: Review of safe practice. Interact Cardio Vasc Thorac Surg. 2005; 4:429-33.
3. Schreiber J, Hachenberg T, Follner S, Riedel S. Bronchopulmonary complication of nasogastric tube placement. Global Journal of Respiratory Care. 2014;1:13-6
4. Sweta, Srivastava U, Agarwal A. Inadvertent insertion of nasogastric tube into the trachea of a conscious patient. IJCCM. 2012;2:116-7
5. Luo RB, Zhang M, Gan JX. Tracheobronchial malposition of fine bore feeding tube in patients with mechanical ventilation. Critical Care. 2011; 15:454.
6. Giantsou E, Gunning KJ. Blindly inserted nasogastric feeding tubes and thoracic complication in intensive care. Health. 2010;10:1135-41.

**Cite this article as:** Takhar RP, Bunkar M, Arya S, Saran RK. Lavage through malpositioned nasogastric tube: a cause of concern. Int J Res Med Sci. 2015;3:3904-6.