

Original Research Article

Bronchoscopic findings of flexible bronchoscopy: a one-year retrospective study in a tertiary care hospital

Philips Antony*, Hafiz Deshmukh

Respiratory Medicine, MGM Medical College and Hospital, Aurangabad, Maharashtra, India

Received: 21 November 2017

Accepted: 021 December 2017

***Correspondence:**

Dr. Philips Antony,

E-mail: phil.antony@gmail.com

Copyright: © the author(s), publisher and licensee Medip Academy. This is an open-access article distributed under the terms of the Creative Commons Attribution Non-Commercial License, which permits unrestricted non-commercial use, distribution, and reproduction in any medium, provided the original work is properly cited.

ABSTRACT

Background: Since the introduction of the first flexible fiberoptic bronchoscope by Shigeto Ikeda in 1966, fiberoptic bronchoscopy (FOB) has been a valuable tool in the diagnosis of pulmonary diseases. Therefore, the aim of this study is to report our one-year experience with the yield of flexible fiberoptic bronchoscopy at MGM Medical College and Hospital, a tertiary hospital in Maharashtra.

Methods: A retrospective study of fiberoptic bronchoscopy (FOB) was performed at MGM Medical College and Hospital, Aurangabad, Maharashtra during the period 2015-2016. Bronchoscopy was performed and collection of bronchial washing, bronchial brushing, bronchial biopsy and transbronchial needle aspiration was done.

Results: Out of 192 patients, 140 were males and 52 were females. Majority of them were in age group 50-59 years. Main indication was pulmonary tuberculosis. Bronchial washings were done in 168 cases and brushing in 56 cases and common location for both was right upper lobe; bronchial biopsy was done in 90 cases with commonest location left main bronchus. Transbronchial needle aspiration was done in 4 cases, active bleed was seen in 6 cases and purulent discharge was seen in 24 cases. Bronchoscopic finding in majority of patients was normal tracheobronchial tree.

Conclusions: The optimal use of conventional bronchoscopy and its techniques in the hands of experienced respiratory interventionists, with the adherence of the international guidelines for performing these techniques will improve the diagnostic outcomes of those patients with the least morbidity and mortality, employing better therapeutic strategies, and thus improving the overall management of those patients.

Keywords: Bronchial brushing, Bronchial biopsy, Bronchial washing, Fiberoptic bronchoscopy, Transbronchial needle aspiration

INTRODUCTION

Since the introduction of the first flexible fiberoptic bronchoscope by Shigeto Ikeda in 1966, fiberoptic bronchoscopy (FOB) has been a valuable tool in the diagnosis of pulmonary diseases.¹ Flexible bronchoscopy is very safe and has a high diagnostic yield. Flexible bronchoscope has replaced the rigid bronchoscope in the diagnosis and management of inflammatory, infectious

and malignant disease of the chest and also helps in the diagnosis and therapeutic approach of respiratory diseases.² For early diagnosis different diagnostic modalities are available such as brushing, washing and fine needle aspiration.³ The diagnostic sensitivity of bronchial brushing was 50% according to a study and the diagnostic sensitivity of bronchial biopsy in cases of visible cancers was 84.2% in the same study.⁴ Another study has shown that atleast five biopsies are needed to

maximise the chance of obtaining a histological evidence of cancer.⁵ FOB can help to visually evaluate the tracheobronchial tree and also to obtain bronchial brushings, bronchial washings, bronchial biopsies and transbronchial needle aspiration. This will help the physician in arriving at a firm diagnosis and can influence the therapeutic decision-making. In the recent day practice, flexible bronchoscopy has become perhaps the most commonly employed invasive procedure in the practice of respiratory medicine.

Therefore, the aim of this study is to report our one-year experience with the yield of flexible fiberoptic bronchoscopy at MGM Medical College and Hospital, a tertiary hospital in Maharashtra.

METHODS

This is a retrospective study of fiberoptic bronchoscopy (FOB) performed at MGM Medical College and Hospital, Aurangabad, Maharashtra during the period 2015-2016. Bronchoscopy was performed in these patients and collection of bronchial washing, bronchial brushing, bronchial biopsy and transbronchial needle aspiration was done.

A total of 192 patients who underwent the study were studied. Pre-bronchoscopy screening was done with history, physical examination, BT, CT, PT, platelet count, fresh X-ray chest PA view, ECG, sputum smear for AFB. All FOBs were performed by spraying 2% lignocaine in the oropharynx. Patients were instructed to be nil per oral for 3-4 hours prior to the procedure. Informed consent was taken. All bronchoscopic examinations were done using a 6mm video assisted flexible bronchoscope (BF-IT150, Olympus, Tokyo, Japan) by experienced respiratory interventionists.

A flexible bronchoscope was introduced trans-nasally in majority of patients. All bronchoscopies were performed by a single operator and were done with the patient lying supine on the table and the operator standing at the head end. The nasopharynx, larynx, vocal cords, trachea and the transbronchial tree were visualised under direct vision up to 4th-6th generations.

The brush and biopsy instrument are withdrawn through internal channel. The same fiberoptic bronchoscope was used throughout the study. Clinical files of the patients were studied. The following characteristics were analysed in each patient: age, sex, bronchoscopic findings, localization of bronchial lesion and location of washings, brushings, biopsy and transbronchial needle aspiration along with presence of active bleeding and purulent discharge.

During the bronchoscopic procedure, diagnostic materials were obtained by bronchial brushings, bronchial washing (BW), endobronchial or transbronchial lung biopsy

(TBLB) and transbronchial needle aspiration (TBNA), as decided by the bronchoscopist on a case-by-case basis.

Collection and handling of tissue sampling materials

The combination of washing, biopsy and brushing was carried out in these patients in most of the cases especially when tumour was visible. When no lesion was seen, endoscopically blind cytology was performed by brushing and washing the appropriate segment as determined by the chest radiographs/CT findings.

Brush cytology

Re-usable brush with nylon bristles was used for brushing which was cleaned between procedures. Once tumour was brushed, the brush was withdrawn, and materials were transferred directly onto glass slides.

Bronchial washings

were obtained with a lavage with 20 ml normal saline, subsequent aspiration into suction tubing. Specimen was sent in a sterile container for cytological examination.

Biopsy

For tumours which were visible through the bronchoscope and located, biopsy was not difficult. For tumours in difficult location, the tip of the bronchoscope was flexed as far as possible. Biopsy material obtained was transferred to a container containing 10% formalin and send for histopathological examination.

Transbronchial needle aspiration (TBNA)

It was performed prior to other procedures such as brushing, washing and bronchial biopsy to avoid contamination. A 13mm 21-gauge cytology needle (NA 2C1; Olympus Corporation) was used for TBNA and was sent for cytological examination. Cytological specimens were stained routinely by Papanicolaou techniques and Ziehl-Nelson method was used for staining acid-fast bacilli. Histological specimens were stained with haematoxylin and eosin. All the specimens were interpreted by a cytopathologist. All subjects were kept under constant supervision for post-bronchoscopy complications, for 4 hours following the procedure.

RESULTS

A total of 192 patients underwent bronchoscopic procedures during the period 2015-2016. Of these 192 patients, 140 patients were males and 52 patients were females. Most of the patients were of age group 50-59 years (Figure 1). Main indication for bronchoscopy was pulmonary tuberculosis in 80 cases, followed by mass in 60 cases. Six patients each presented with haemoptysis and secretions. Others included 40 cases (Table 1).

Table 1: Indications for bronchoscopy.

Indication of bronchoscopy	No. of patients
Pulmonary tuberculosis	80
Mass	60
Haemoptysis	6
Secretions	6
Others	40

The reasons why pulmonary tuberculosis patients were referred for FOB were negative sputum smear for AFB (n = 60), negative induced sputum smear for AFB (n = 18), and lack of sputum production even after hypertonic saline induction (n = 2). Bronchial washings were done in 168 of the cases and the most common location was from the right upper lobe followed by the left lower lobe (Table 2).

Table 2: Table showing the site of bronchial washings.

Site of bronchial washings	No. of cases	Site of bronchial washings	No. of cases
Right main bronchus	13	Right middle lower and left lower	2
Left main bronchus	14	Right upper lobe and bronchus intermedius	1
Both main bronchus	2	Left upper lobe	14
Right upper lobe	29	Left lower lobe	22
Right middle lobe	13	Left upper and lower lobe	3
Right lower lobe	19	Left lingula	7
Right upper and middle	2	Left lingual and lower lobe	2
Right middle and lower	6	Both upper lobes	3
Right upper and lower	1	Both lower lobes	3
Right upper middle and lower	3	Tracheal growth and left lower lobe	1
Right bronchus intermedius	7	Vocal cord	1

Bronchial brushings were done in 56 of the cases and the most common location was from the right upper lobe (Table 3).

Table 3: Table showing the site of bronchial brushings.

Site of bronchial brushings	No. of cases
Right main bronchus	7
Left main bronchus	13
Both main bronchus	2
Right upper lobe	14
Right middle lobe	4
Right lower lobe	1
Right upper and lower lobe	1
Right bronchus intermedius	5
Left upper lobe	3
Left lower lobe	4
Tracheal growth and right upper lobe	1
Carina	1

Bronchial biopsies were done in 90 of the cases and the most common location was from the left main bronchus followed by the right upper lobe (Table 4).

Transbronchial needle aspiration was done in four of the cases, out of which two were from right secondary carina and two cases each were from carina and subcarinal lymph node (Figure 2).

Table 4: Table showing the site of bronchial biopsy.

Site of bronchial washings	No. of cases
Right main bronchus	10
Left main bronchus	18
Both main bronchus	2
Right upper lobe	16
Right middle lobe	5
Right lower lobe	10
Right middle and lower lobe	1
Right bronchus intermedius	11
Left upper lobe	3
Left lower lobe	9
Left upper and lower lobe	1
Left lingula	1
Tracheal growth and right upper lobe	1
Vocal cord	1
Subglottic	1

Active bleeding was seen in 6 of the cases, out of which two cases each were seen in the apical segment of right upper lobe and left lobe followed by one case each of posterior segment of right upper lobe and left lingula (Figure 3).

Purulent discharge was seen in 24 cases with the discharge more in right and left lower lobes (6 cases each) (Figure 4).

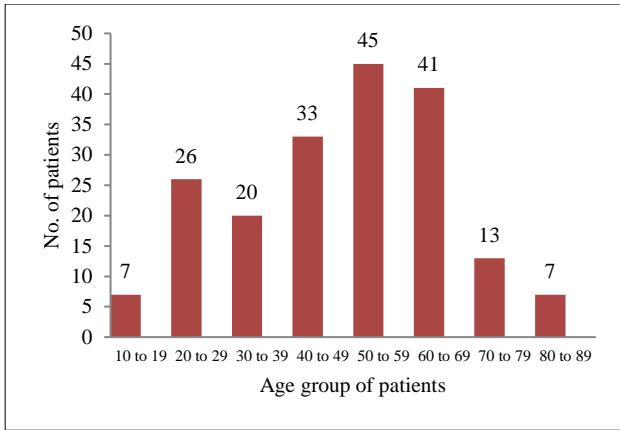


Figure 1: Bar diagram showing the age group of patients.

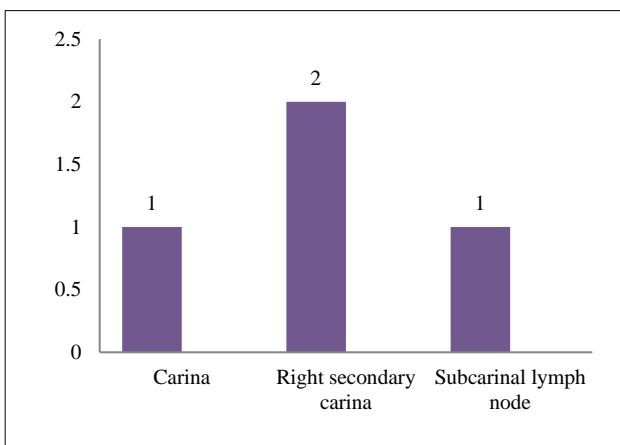


Figure 2: Bar diagram showing the site of transbronchial needle aspiration.

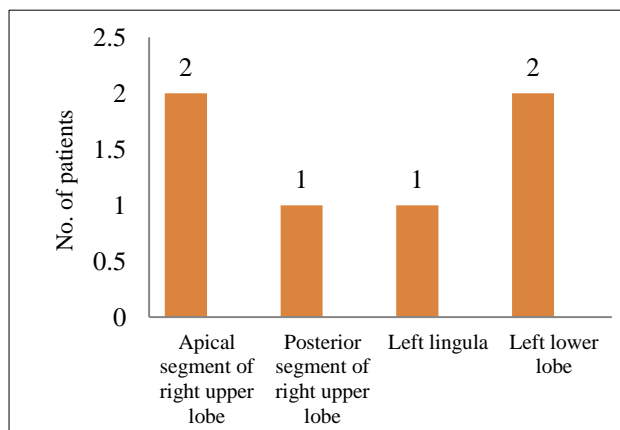


Figure 3: Bar diagram showing the site of active bleeding.

Bronchoscopic findings were reported in all the 192 patients with the majority of patients having a normal tracheobronchial tree (80 cases) next to be followed by mass lesion (60 cases) with and extra-luminal compressions (25 cases) (Figure 5).

DISCUSSION

In this study, a retrospective analysis of 192 cases of flexible fiberoptic bronchoscopies was performed over a period of one year in MGM Medical College and Hospital, Aurangabad, Maharashtra. The commonest age group in our study for undergoing bronchoscopy was 50-59years, though there was a wide age range. This was similar to a study done by Batau et al which had most of the cases done in the age group 51-60years.⁶

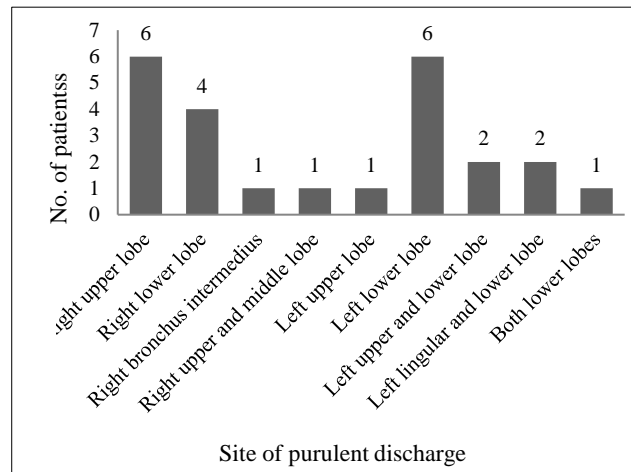


Figure 4: Bar diagram showing the site of purulent discharge.

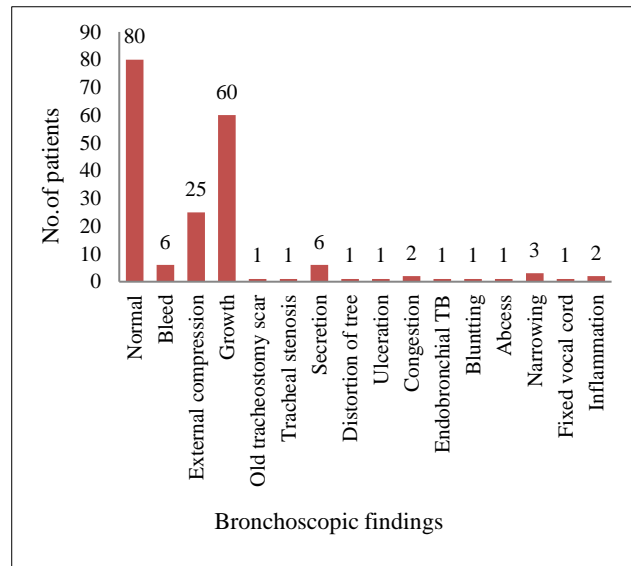


Figure 5: Bar diagram showing Bronchoscopic findings.

Flexible bronchoscopy in our cases was performed more commonly in males which were consistent with the studies done by Batau et al, Fasihuddin et al and BJ Arun et al.⁶⁻⁸ The prepondance of males probably was related to their smoking habits and greater exposure to environmental pollutants.

Lesions were more common in the right upper lobe in our study which was also seen in the study done by Fassihudin S et al.⁷ It is known that upper lobes are more susceptible to both lung cancer and pulmonary tuberculosis and this could be due to the fact that the upper lobes are less vascular and better aerated and is more affected by smoking.

Our study showed six cases of active bleed as bronchoscopic finding. This finding was also seen in a study done by Ju-Hee Park et al.⁹ According to the studies done by Nicotra MB et al bronchoscopy should be considered in the patients with significant haemoptysis.¹⁰ Bronchoscopy can localize over 60% of the bleeding cases and can be helpful in cases which have alternative causes for bleeding. Though the optimal time to do the procedure remains controversial, this is the primary method for the diagnosis and localization of the site of haemoptysis. Analysis of bronchial washing in cases of bronchiectasis and bleeding may also provide important information regarding the cause of haemoptysis.

In the present study, pulmonary tuberculosis (80 cases) was the commonest suspected clinical diagnosis for which bronchoscopy was performed irrespective of age and gender. This can be expected in a country like India where tuberculosis is a commonly encountered clinical condition and is considered in the differential diagnosis of various clinical presentations. This study was in concordance with a study done by Jacomelli M et al in which out of 286 cases who underwent bronchoscopy, 127 cases were diagnosed on bronchoscopic findings as pulmonary tuberculosis.¹¹

On comparing the top two suspected clinical diagnoses of pulmonary tuberculosis and lung malignancy with the findings during bronchoscopy, it was observed that the highest proportion (80 cases) of normal bronchoscopy findings were noted in subjects with “suspected pulmonary tuberculosis” category which was in concordance with the study done by Rahul Magazine et al who had 51.9% cases showing normal bronchoscopic findings in subjects with suspected pulmonary tuberculosis.¹² Endobronchial growth was the next common finding followed by external compression.

CONCLUSION

Flexible bronchoscopy is increasingly being utilized in diagnosis of a wide array of respiratory disorders. It is fairly safe and can be performed as an outpatient procedure. Our study suggests that, in investigating suspected cases of lung malignancy a bronchoscopist should adopt all diagnostic techniques of biopsy, brushing and washing to increase the yield of diagnosis. In short, the optimal use of conventional bronchoscopy and its techniques in the hands of experienced respiratory interventionists will improve the diagnostic outcomes of those patients with the least morbidity and mortality,

employing better therapeutic strategies, and thus improving the overall management of those patients.

ACKNOWLEDGEMENTS

Authors would like to thank all the staffs and friends from Respiratory Medicine Department for their sincere help and a special thanks to Dr. Greeshma from Department of Pathology.

Funding: No funding sources

Conflict of interest: None declared

Ethical approval: The study was approved by the Institutional Ethics Committee

REFERENCES

1. Ohata M. History and progress of bronchology in Japan. *J Japan Soci Res Endos.* 1998;20(6):539-46.
2. Anthony Seaton, Douglas Seaton. *Crofton and Douglas's Respiratory diseases*; 5th ed. Pub. Blackwell Science, 2008:148-9.
3. Shagufta Tahir Mufti1, Ghadeer A. Mokhtar; Diagnostic value of bronchial wash, bronchial brushing, fine needle aspiration cytology versus combined bronchial wash and bronchial brushing in the diagnosis of primary lung carcinomas at a tertiary care hospital. *Biomed Res.* 2015;26(4):777-84.
4. Tuladhar A, Panth R, Joshi A R. Comparative analyses of cytohistologic techniques in diagnoses of lung lesions. *J Pathol Nepal.* 2011;1:126-30.
5. Gellert AR, Rudd RM, Sinha GA, Geddes DM. Fiberoptic bronchoscopy: effect of multiple bronchial biopsies on diagnostic yield in bronchial carcinoma. *Thorax.* 1982;37(9):684-7.
6. Bhadke B, Munje R, Mahadani J, Surjushe A, Jalgaonkar P. Utility of fiberoptic bronchoscopy in diagnosis of various lung conditions: Our experience at rural medical college. *Lung India: official organ of Indian Chest Society.* 2010;27(3):118.
7. Fasihuddin S, Mashlah A, Alkaffas E, Tauheed H. Eight Year Audit of Fiberoptic Bronchoscopies Performed at King Abdul Aziz Hospital, Makkah, Saudi Arabia. *Pak J Chest Med.* 2015;18(3).
8. Arun BJ, Antin G, Vidyasagar B. Role of fiberoptic bronchoscopy in suspected cases of lung cancer. *Int J Evid Based Healthc.* 2014;1(12):1494-502.
9. Park JH, Kim SJ, Lee AR, Lee JK, Kim J, Lim HJ, et al. Diagnostic yield of bronchial washing fluid analysis for hemoptysis in patients with bronchiectasis. *Yonsei medical journal.* 2014;55(3):739-45.
10. Nicotra MB, Rivera M, Dale AM, Shepherd R, Carter R. Clinical, Pathophysiologic, and microbiologic characterization of bronchiectasis in an aging cohort. *Chest.* 1995;108:955-61.
11. Jacomelli M, Silva PR, Rodrigues AJ, Demarzo SE, Seicento M, Figueiredo VR. Bronchoscopy for the

diagnosis of pulmonary tuberculosis in patients with negative sputum smear microscopy results. *J Bras Pneumol.* 2012;38:167-73.

12. Magazine R, Rao S. Utility of flexible fiber optic bronchoscopy: Experience from a tertiary care teaching hospital. *J Dr. NTR University Health Sci.* 2013;2(4):249.

Cite this article as: Antony P, Deshmukh H. Bronchoscopic findings of flexible bronchoscopy: a one-year retrospective study in a tertiary care hospital. *Int J Res Med Sci* 2018;6:591-6.