

Original Research Article

Influence of cataract and small incision cataract surgery on the macular thickness measurements: an optical coherence tomography-based study

Anu F. Anand*, C. V. Anthrayose Kakkanatt, Monsy T. Mathai, Minu Sasikumar

Department of Ophthalmology, Jubilee Mission Medical College and Research Institute, Thrissur, Kerala, India

Received: 22 January 2018

Accepted: 26 February 2018

*Correspondence:

Dr. Anu F. Anand,

E-mail: anujafel@gmail.com

Copyright: © the author(s), publisher and licensee Medip Academy. This is an open-access article distributed under the terms of the Creative Commons Attribution Non-Commercial License, which permits unrestricted non-commercial use, distribution, and reproduction in any medium, provided the original work is properly cited.

ABSTRACT

Background: Optical Coherence Tomography (OCT) is a noninvasive imaging technique for analysing retinal architecture. It is a common investigation for various optic disc and macular diseases like glaucoma and diabetic macular oedema nowadays. OCT image quality is affected by many factors especially media opacity due to cataract. This study was done to compare macular thickness measurements by OCT in the presence of cataract and after removal of the cataract by Small Incision Cataract Surgery (SICS).

Methods: A prospective observational study was designed which included 99 eyes of 99 patients with no optic disc and retinal pathology who underwent uncomplicated small incision cataract surgery. Routine ophthalmological evaluation including scans using macular analysis protocols of Cirrus HD OCT were done on the first visit to outpatient department and repeated on the day of surgery, one week and three weeks after surgery. The difference between the visits were analysed by Student's t-test for paired samples.

Results: The best corrected visual acuity and signal strength of OCT scans improved significantly after surgery. Among the macular parameters the temporal inner, nasal inner and nasal outer area thicknesses showed significant improvement from preoperative to postoperative values. The foveal thickness, nasal inner and nasal outer thicknesses changed significantly between two postoperative visits.

Conclusions: The presence of cataract and small incision cataract surgery affects the macular measurements performed with Cirrus HD OCT. This should be taken into consideration while managing macular diseases like diabetic macular oedema.

Keywords: Cataract, OCT, SICS and macular thickness

INTRODUCTION

Optical Coherence Tomography (OCT) was introduced in 1991 and since then it has become an invaluable tool in the diagnosis and management of different retinal disorders. OCT is a method of analysing the *in-vivo* retinal architecture. It is particularly useful and accurate for measuring retinal nerve fibre layer (RNFL) thickness and macular thickness.¹ OCT uses light reflectance signal from the retina to measure its thickness. Macular oedema (ME) occurs in a variety of pathological conditions and

accounts for different degrees of vision loss. Early detection of ME is therefore critical for diagnosis and management. OCT has been routinely used in measuring retinal thickness for the evaluation of ME caused by diseases such as age-related macular degeneration, diabetic retinopathy, central serous retinopathy, hereditary retinal degenerations, retinal vein occlusion, after cataract surgery, epiretinal membrane (ERM) and uveitis. Diabetic macular oedema is the most common macular pathology detected in the macular OCT. Fluid accumulation in diabetic macular oedema can be in the

form of diffuse retinal thickening, cystoid macular oedema and serous retinal detachment.² Management of macular oedema by intravitreal injection of anti VEG- F agents and need for repeat injections are decided based on foveal thickness by OCT.

OCT image quality is influenced by many factors like visual acuity less than 20/40, moderate to severe cataract, past cataract surgery, advanced glaucoma stage, open angle glaucoma and peripapillary atrophy. Cataract was associated with an increased frequency of artifacts. As cataract severity increased, it was more likely that the corresponding scan would contain at least one artefact. Media opacity of any kind can affect OCT signal strength.³ In the elderly population, cataract is the most common cause of media opacity that is known to influence the OCT image quality and measurements. During OCT, cataract is likely to increase the light scattering and degrade the OCT image quality. Senile cataract is the most common potentially reversible blinding disorder (72.0%) among eyes presenting with blindness in south Indian population.⁴ Cataract is managed by removal of the cataractous lens and implantation of posterior chamber intraocular lens. As cataract is a common co existing disease with glaucoma and diabetic retinopathy, it can be a common confounding factor in the diagnosis and follow up of these patients.⁵

While managing optic disc diseases and macular diseases, one must be aware of how cataract affects the OCT measurements and how the measurements are altered after the removal of cataract. There are a few studies which compared the OCT measurements before and after phacoemulsification.^{1,6-9} The studies by Bambo MP et al, Martin EG et al, Pasova P et al and Gharbhiya M et al, found that the macular thicknesses are increasing after removal of cataract and some other studies like Ching HY et al, found that the macular thicknesses are decreasing after phacoemulsification.^{1,6-9} Hence this study was done to analyse the change in the macular OCT measurements using Cirrus HD OCT model 500, after removal of cataract by uncomplicated small incision cataract surgery. Small Incision Cataract Surgery (SICS) may be the more appropriate surgical procedure for the treatment of cataract in high volume camp surgery of rural patients in the developing world as compared to clear corneal phaco with rigid IOL. It is nonmachine dependent, quicker, cost effective and gives good visual results. SICS should be the preferred option in rural patients who cannot afford a foldable IOL.¹⁰ The temporal SICS with number 11 disposable surgical blade and nucleus delivery by sandwich method gave excellent outcome with minimal astigmatism and low complication rate at economic cost.¹¹

METHODS

This was a prospective observational study which included 103 patients who underwent small incision

cataract surgery in Jubilee Mission Medical College, Thrissur from June 2016 to May 2017. The exclusion criteria were those with intraocular pressure >21mmHg, previously diagnosed glaucoma, high refractive errors – more than 5D of spherical equivalent refraction or 3D astigmatism, macular diseases and very poor signal strength (<2) of OCT. All patients who were to undergo small incision cataract surgery underwent a detailed history and clinical examination. An informed consent regarding the study was taken from all the included patients. Preoperative evaluations included systemic evaluation- blood pressure and heart rate, detailed ophthalmic examinations-Visual acuity-unaided, with power glass and with pin hole, subjective refraction, intraocular pressure assessment, slit lamp examination, dilated fundus examination, keratometry and A scan biometry with IOL power calculation.

Visual acuity was measured by Snellen's chart and converted to logMar scale. All the patients subjected OCT evaluation of macular cube 512×128 at the preoperative visit when surgery date was decided. The OCT machine used was the Cirrus HD OCT model 500 in the outpatient department. In each series of macular scans the signal strength, retinal thickness values of nine areas corresponding to the Early Treatment Diabetic Retinopathy Study (ETDRS)- central 1mm circle, inner and outer rings each divided into four quadrants (superior, nasal, inferior and temporal) were analysed.

Patients were treated with antibiotic eye drops – moxifloxacin 0.5% eye drops one drop four times a day, 2 days prior to surgery. OCT evaluation of macula was repeated on the day of surgery. Tropicacyl plus eye drops containing tropicamide and phenyl ephrine was used to dilate pupil. Peribulbar block was given with 0.5% bupivocaine and 2% lignocaine. All patients underwent manual Small Incision Cataract Extraction with a superior self sealing sclerocorneal tunnel incision. All surgeries were carried out by a single experienced surgeon. Posterior chamber intra ocular lens was implanted in the capsular bag for all the patients. Only those patients who had uneventful surgery, were included in the study. Patients were discharged on the first postoperative day. Post operative medications were moxifloxacin-dexamethasone combination eye drops, fluromethalone-tobramycin combination eye drops and flurbiprofen eye drops.

Routine ophthalmological evaluation and OCT scanning of macula were repeated on the first postoperative review one week after surgery and second postoperative review three weeks after surgery. Four patients lost for second postoperative follow up and those patients were excluded during analysis.

Descriptive and inferential statistical analysis has been carried out in the present study. Results on continuous measurements are presented on Mean ± SD (Min-Max) and results on categorical measurements are presented in

Number (%). Significance was assessed at 5 % level of significance. Student t test (two tailed, independent) has been used to find the significance of study parameters on continuous scale between two groups (Inter group analysis) on metric parameters. Student t test (two tailed, dependent) has been used to find the significance of study parameters on continuous scale within each group. P value <0.05 was considered as statistically significant. The Statistical software namely SPSS 20.0, and R environment ver.3.2.2 were used for the analysis of the data and Microsoft word and Excel have been used to generate graphs, tables etc.

RESULTS

The present study was an observational prospective investigation of 99 patients who underwent cataract surgery in Jubilee Mission Medical College, Thrissur from June 2016 to May 2017. The majority of the patients included were in the age group 61-70 years (49.5%). 25.3% were between 51-60years group and 23.2% were between 71-80years group. The mean age of the study population was 66.15±7.12years. Among the 99 patients 52 patients (52.5%) were females and 47 (47.5%) were males. Right eye cataract surgery was performed in 43patients and left eye cataract surgery was performed in 56 patients. In the study group 76 patients (76.8%) were type II diabetes mellitus patients, 51 patients (51.5%) were systemic hypertensives and 58 patients (58.6%) were dyslipidemic patients.

In the present study the mean Best corrected visual acuity (BCVA) by logmar was 0.96±0.24 before cataract surgery and 0.06±0.09 three weeks after the surgery. The change in vision was strongly significant statistically (P<0.001). In the present study the mean signal strength of macular scans was 5.69±1.39 preoperatively which improved to 7.06±1.14 three weeks postoperatively. This change was statistically significant. Signal strength more than 5 was present in only 79.8 % preoperatively. It improved to 97 % postoperatively. Baseline characteristics of the study group is shown in Table 1.

Table 1: Baseline characteristics during first visit.

parameters	Mean ± SD (µm)
Vision (log Mar)	0.96±0.24
Age (years)	66.15±7.12
Macular measurements (µm)	
Signal strength macular scans	5.69±1.39
Fovea	232.97±30.62
Superior inner	300.23±30.05
Nasal inner	298.90±24.44
Inferior inner	295.56±23.86
Temporal inner	290.99±20.58
Superior outer	263.12±24.01
Nasal outer	273.34±20.92
Inferior outer	252.29±25.05
Temporal outer	251.32±30.85

Table 2: P values by comparing macular thickness between admission to first postoperative week, admission to third postoperative week and first and third postoperative weeks.

Macular quadrants	Admission to first postoperative week	Admission to third postoperative week	First to third postoperative week
Fovea	0.117	0.055	0.003
Superior inner	0.693	0.517	0.104
Nasal inner	0.102	0.040	0.005
Inferior inner	0.118	0.127	0.810
Temporal inner	0.023	0.018	0.528
Superior outer	0.596	0.528	0.092
Nasal outer	0.008	<0.001	0.031
Inferior outer	0.273	0.231	0.556
Temporal outer	0.112	0.124	0.674

Macular thickness was measured in nine areas corresponding to the Early Treatment Diabetic Retinopathy Study (ETDRS). The areas were fovea or central macular thickness, superior inner, nasal inner, inferior inner, temporal inner, superior outer, nasal outer, inferior outer and temporal outer areas. Figure 1 represents the macular thickness measurements on the day of admission, first and third week postoperative visits. Table 2 shows the P values of each macular parameters on comparing admission to first week,

admission to third week and first to third postoperative week. On comparing admission values with first postoperative week values, statistically significant increase in the thickness was found only in temporal inner and nasal outer quadrants (P=0.023 and P=0.008). The order of change between admission to first postoperative visit was temporal inner (5.050 µm) > fovea (4.222 µm) >temporal outer (4.192 µm) > inferior inner (3.565 µm) > nasal outer (3.485 µm)> nasal inner (2.576 µm) > inferior outer (2.273 µm) > superior outer

(1.818 μm) > superior inner (1.051 μm) (Figure 1). On comparing admission values with third postoperative week values statistically significant increase in the thickness was found in nasal inner, temporal inner and nasal outer areas. P values were 0.040, 0.018 and < 0.001 respectively. The order of change between admission to

second postoperative visit was temporal inner (5.202 μm) > fovea (5.152 μm) > nasal outer (4.535 μm) > temporal outer (4.040 μm) > inferior inner (3.505 μm) > nasal inner (3.222 μm) > inferior outer (2.495 μm) > superior outer (2.101 μm) > superior inner (1.737 μm).

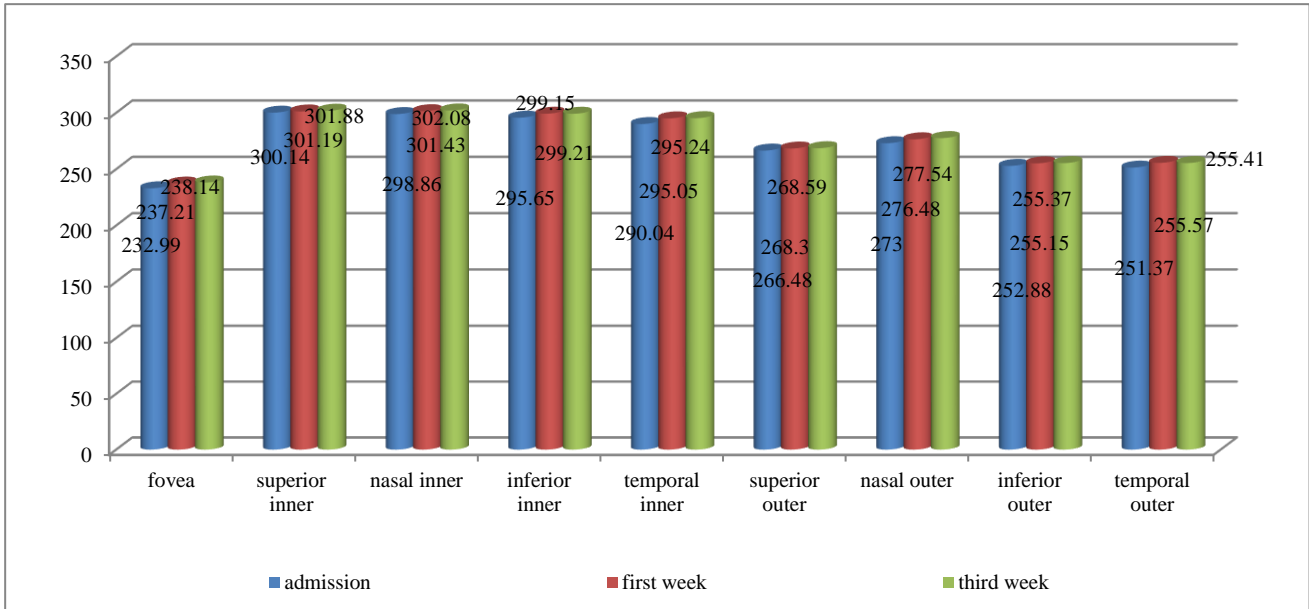


Figure 1: Representation of macular thickness before and first and third week after small incision cataract surgery.

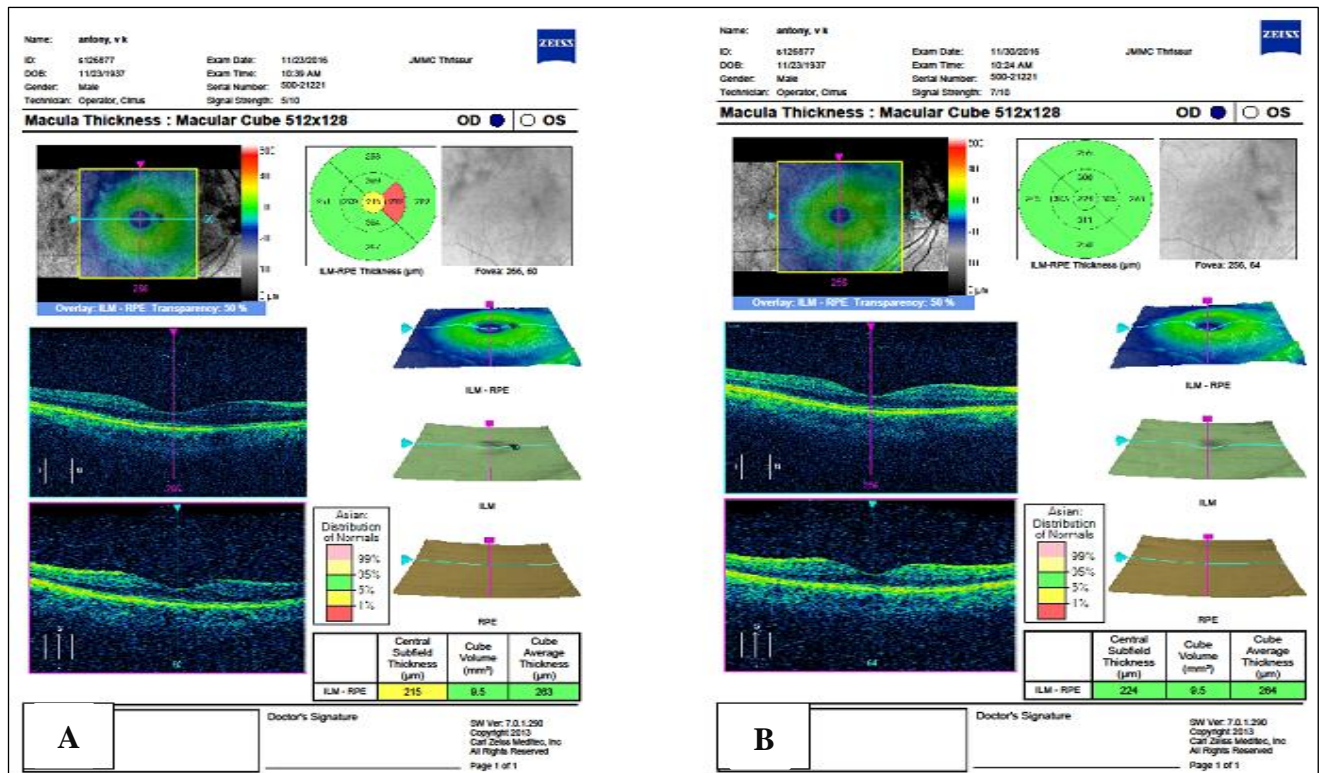


Figure 2: (A) Macular scan of a patient on the day of admission, (B) Three weeks postoperatively Macular thinning in the fovea and nasal inner disappeared in the postoperative scan.

On comparing first and second post operative visit macular thicknesses the statistically significant change was found in the foveal thickness, nasal inner and nasal outer areas. The P values were 0.003, 0.005 and 0.031 respectively. The order of change of macular thickness from first to second postoperative visits were nasal outer (1.051 μm) > fovea (0.929 μm) > superior inner (0.687 μm) > nasal inner (0.646 μm) > superior outer (0.283 μm) > inferior outer (0.222 μm) > temporal outer (0.152 μm) = temporal inner (0.152 μm) > inferior inner (0.061 μm). Figure 2 shows improvement in the foveal and nasal inner macular thickness following SICS.

DISCUSSION

In a study by Garbhiya M et al, at day 1 after surgery, mean retinal thickness of all macular subfields of the operated eyes decreased significantly in comparison to the fellow eyes.⁸ There was a significant increase in retinal thickness of the outer macular area from one week postoperatively onwards with a peak at 1 month, while retinal thickness of the central fovea began to increase from the first month, with a peak at 2 months. At 6 months after surgery, retinal thickness tended to normalize in the central fovea, whereas it remained increased in the outer macular area. As in case of aforementioned observations, in the present study also the central foveal thickness didn't show significant increase till three weeks after surgery. Furthermore, in the present study the significant increase in the thickness was found only in temporal inner and nasal outer quadrants one week after surgery and in nasal inner, temporal inner and nasal outer areas showed significant increase three weeks after surgery. This finding was comparable to that of Gharbhiya et al. Lobo CL et al, studied macular alterations following small incision cataract surgery and found not only retinal leakage after cataract extraction, using a prototype of confocal scanning laser fluorometer but also located the leaking sites in the perifoveal zone by angiography.¹² These leaking sites, which could represent focal inner blood retinal barrier disruption, were located in the vascularised regions of the macula, outside the foveal avascular zone. The above observations may explain the different patterns of change in thickness found in the present study.

In the study by Bambo MP et al, all macular parameters were significantly increased after surgery with Cirrus OCT.¹ The largest difference was noticed in the fovea thickness (60 μm). Using spectralis OCT the macular thickness measures were not significantly different after surgery. In contrast Martin EG et al, depicted all macular parameters were significantly increased after surgery based on measurements with the Cirrus OCT.⁶ The largest difference was in the superior outer thickness (34.3 μm). The macular thickness measurements made with the Spectralis OCT were not significantly different after surgery. There are several causes which may

contribute to this change in the results. In the present study the measurements on the day of surgery and first and third postoperative week were compared, rather than the measurements one month before and one month after the surgery as in case of above studies. The influence of cataract surgery on intraocular pressure and the release of inflammatory mediators inducing disturbed blood retinal barrier permeability with vessel leakage are factors that could affect the thickness measurements. These factors are highly individual to the patient. Upto 3-5 weeks post surgery these factors can play a role in the OCT measurements.⁵

Ching HY et al, in their study found that the mean preoperative thickness was higher than postoperative thickness.⁹ The mean preoperative foveal thickness was 189.367 \pm 26.83mm and postoperative thicknesses were 175.747 \pm 26.79mm, 180.257 \pm 27.13mm and 176.587 \pm 26.45mm at 2weeks, 4weeks and 8weeks postoperatively. It was explained by possibility of error in preoperative measurements because of the presence of cataracts, or it may be due to an apparent thinning of the retina when the crystalline lens is replaced by an intraocular lens. This is not comparable to our study. In our study Cirrus HD OCT model 500 was used for image acquisition. Each OCT machine will have differences in hardware, like superluminescent diode power, charge coupled device camera and software, like postacquisition processing of the signal. All the SD OCT devices on the market will show a different influence of opacities on change in measurements.⁵

CONCLUSION

The signal strength of macular scans improved significantly after removal of cataract. Statistically significant change in the macular thickness from preoperative to postoperative values were found in the temporal inner, nasal outer and nasal inner areas only (P<0.05). Significant change in thickness between first and second postoperative visits were found in foveal thickness, nasal inner and nasal outer areas (P<0.05). According to the present study the change in the macular thickness postoperatively may be due to various factors like absence of cataract, presence of intraocular lens, changes in the intraocular pressure during surgery, blood retinal barrier disruption and the type of machine used for measurements. The change in thickness should be considered while monitoring diseases like diabetic macular oedema and other macular pathologies post cataract surgery.

ACKNOWLEDGEMENTS

Authors would like to thank Department of Ophthalmology, Jubilee Mission Medical College and Research Institute for all their valuable assistance during the study period.

Funding: No funding sources

Conflict of interest: None declared

Ethical approval: The study was approved by the Institutional Ethics Committee

REFERENCES

1. Bambo M.P, Martin E.C, Otin S, Sancho E, Fulrtes I, Herrero R, et al. Influence of cataract surgery on repeatability and measurements of spectral domain OCT. *Br J Ophthalmol.* 2014;98(1):52-8.
2. Trichonas G, Kaiser PK. "Optical coherence tomography imaging of macular odema". *Br J Ophthalmol.* 2014;98Suppl2:ii24-9.
3. Liu Y, Simavli H, Que CJ, Rizzo JL, Tsikata E, Maurer R, et al. Patient characteristics associated with artefacts in spectralis OCT imaging of RNFL in glaucoma. *Am J Ophthalmol.* 2015;159(3):565-76.
4. Thulasiraj RD, Nirmalan PK, Ramakrishnan R, Krishandas R, Manimekalai TK, Baburajan NP, et al. Blindness and Vision Impairment in a Rural South Indian Population: The Aravind Comprehensive Eye Survey. *Ophthalmol.* 2003;110(8):1491-8.
5. Kok PH, van den Berg TJ, van Dijk HW, Stehouwer M, van der Meulen IJ, Mourits MP, et al. The relationship between the optical density of cataract and its influence on retinal nerve fibre layer thickness measured with spectral domain optical coherence tomography. *Acta Ophthalmol.* 2013;91(5):418-24.
6. Martin EG, Fernandez J, Arribas GL, Polo V, Larrosa JM, Otin S, et al. Effect of cataract surgery on OCT measurements and repeatability in patients with NIDDM. *Invest Ophthalmolvisci.* 2013;54(8):303-12.
7. Pasova P, SkorkovskaK. The effect of cataract surgery on the reproducibility and outcome of OCT measurements of macular and retinal nerve fiber layer thickness. *Cesk Slov Ophthalmol.* 2016;72(2):20-6.
8. Gharbiya M, Cruciani F, Cuzzo G, Parisi F, Russo P, Abdolrahimzadeh. Macular thickness changes evaluated by Spectral Domain Optical Coherence Tomography after uncomplicated phacoemulsification. *Eye (Lond).* 2013;27(5):605-11.
9. Ching HY, Wong AC, Wong CC, Woo DC, Chan CW. Cystoid macular oedema and changes in retinal thickness after phacoemulsification using optical coherence tomography. *Eye(Lond).*2006;20(3):297-303.
10. Devendra J, Agarwal S, Singh PK. A comparative study of clear corneal phacoemulsification with Rigid IOL versus SICS; the preferred surgical technique in low socio-economic group patients of rural areas. *J Clin Diagn Res.* 2014;8(11):VC01-VC03.
11. Zavar SV, Gogate P. safety and efficacy of temporal manual small incision cataract surgery in India. *Eur J Ophthalmol.* 2011;21(6):748-53.
12. Lobo CL, Faria PM, Soares MA, Bernardes RC, Cunha-Vaz JG. Macular alterations after small incision cataract surgery. *J Cataract Refract Surg.* 2004;30(4):752-60.

Cite this article as: Anand AF, Kakkanatt CVA, Mathai MY, Sasikumar M. Influence of cataract and small incision cataract surgery on the macular thickness measurements: an optical coherence tomography-based study. *Int J Res Med Sci* 2018;6:1277-82.