

## Research Article

# Dorsal sacral dimensional anatomy-revisited

Renu Chauhan<sup>1,\*</sup>, Mahindra Nagar<sup>2</sup>

<sup>1</sup>Associate Professor, <sup>2</sup>Professor and Head, Department of Anatomy, UCMS and GTB Hospital, Dilshad Garden, Delhi-110095, India

**Received:** 21 April 2015

**Accepted:** 08 May 2015

**\*Correspondence:**

Dr. Renu Chauhan,

E-mail: renuchauhan@yahoo.com

**Copyright:** © the author(s), publisher and licensee Medip Academy. This is an open-access article distributed under the terms of the Creative Commons Attribution Non-Commercial License, which permits unrestricted non-commercial use, distribution, and reproduction in any medium, provided the original work is properly cited.

### ABSTRACT

**Background:** Determination apex of sacral hiatus (SH) is of paramount importance to Anaesthetists, Orthopaedicians, Obstetricians and Gynaecologists for caudal epidural block (CEB). Dorsal sacral dimensions were therefore taken to facilitate them for easy location of SH.

**Methods:** Following parameters of each of the sixty human sacra were measured using vernier calipers at the level of spinous process of second sacral vertebra (S2).

- Distance between the two supero-lateral crests
- Distance between the right supero-lateral crest level to the apex of sacral hiatus (SH)
- Distance between the left supero-lateral crest to the apex of SH
- Distance from the spinous process of S2 to the apex of SH
- Distance from the spinous process of S2 to the base of SH

The data obtained was analysed statistically.

**Results:** Mean of the distance between the two supero-lateral crests was  $51 \pm 6.37$  mm and  $52.7 \pm 5.30$  mm in males and females respectively, mean of the distance between the right supero-lateral crest and the left supero-lateral crest to the apex of SH was  $45.91 \pm 6.94$  mm in males  $42.50 \pm 11.23$  mm in females and  $44.74 \pm 6.77$  mm in males and  $42.50 \pm 10.97$  mm in females respectively, vertical distance from spinous process of S2 to the apex of SH in males and females was  $38.83 \pm 9.33$  mm and  $32.4 \pm 1.64$  mm respectively. Vertical distance from spinous process of S2 to the base of sacral hiatus was  $59.20 \pm 10.81$  mm in males and  $52.80 \pm 9.18$  mm in females.

**Conclusion:** From the data obtained it was concluded that an isosceles triangle was formed between the two supero-lateral crests at the level of spinous process of S2 and the apex of SH.

**Keywords:** Morphometry, Sacrum, Sacral crest, Sacral hiatus

### INTRODUCTION

Sacrum is a triangular bone present at the lower end of the vertebral column, at dorsal end of the pelvic cavity wedged between the two hip bones. It has a convex dorsal and a concave pelvic surface. Its dorsal surface displays a crest in the midline, the median sacral crest representing rudimentary spinous processes of the upper 3-4 sacral vertebrae. On either side of it, it has a shallow sacral groove, the floor of which is formed by fused laminae of the corresponding vertebrae. The laminae of the fifth and sometimes of fourth, fail to meet in the midline

resulting in deficiency in the posterior wall of the sacral canal called the sacral hiatus (SH). Lateral to the sacral groove is the medial sacral crest formed by the fused articular processes. Transverse processes of the sacral vertebrae form the lateral crests of the sacrum.<sup>1</sup>

The posterior superior iliac spine lies on the lateral sacral crest at the level of spinous process of S2 vertebra in 51% of patients.<sup>2</sup> The subarachnoid space usually ends at the level of the disc between S1 and S2, but it can be more inferior.<sup>3</sup> Therefore, a detailed morphometric analysis of sacrum was conducted with respect to spinous process of

S2 to elucidate some of the important landmarks to help in locating the apex of SH which is very often used for caudal epidural block (CEB), trans- sacral thecaloscopy and for injecting drugs into epidural space.

**METHODS**

Sixty adult dry human sacra (male=46, female=14) were obtained from the Anatomy Department of U.C.M.S and G.T.B. Hospital, Dilshad Garden, Delhi. Following parameters were taken (Fig. 1):

- (a) Distance between the two supero-lateral crests at the level of spinous process of S2
- (b) Distance between the right supero-lateral crest at the level of spinous process of S2 to the apex of SH
- (c) Distance between the left supero-lateral crest at the level of spinous process of S2 to the apex of SH
- (d) Distance from the S2 spinous process to the apex of SH
- (e) Distance from S2 spinous process to the base of SH

All the measurements were taken in millimeter using Vernier calipers.

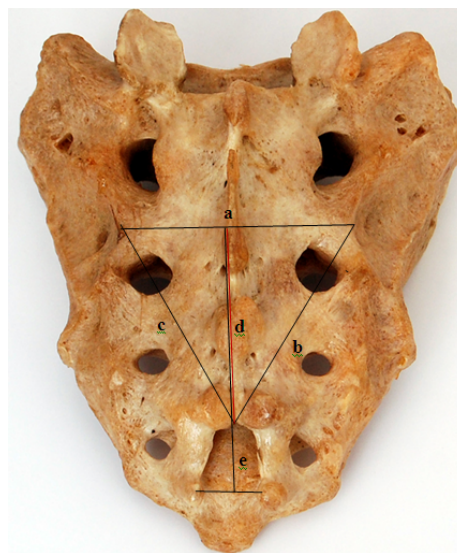
**RESULTS**

Sixty adult dry human sacra (Males = 46, Females = 14) of North Indian origin were used for the present study. Following observations were taken (Fig. 1, Table 1 and 2):

- i) The mean distance between the right and left lateral sacral crests at the level of S2 spinous process was 51.00 ± 6.37 mm in males and 52.7 ± 5.30 mm in females.
- ii) The mean distance between the right lateral sacral crest at the level of spinous process of S2 and the apex of

SH was 45.91 ± 6.94 mm in males and 42.50 ± 11.23 mm in females.

- ii) The mean distance between the right lateral sacral crest at the level of spinous process of S2 and the apex of SH was 45.91 ± 6.94 mm in males and 42.50 ± 11.23 mm in females.



**Figure 1: Dorsal aspect of sacrum showing parameters taken.**

- (a) Distance between the two supero-lateral crests at the level of spinous process of S2
- (b) Distance between the right supero-lateral crest at the level of spinous process of S2 to the apex of sacral hiatus
- (c) Distance between the left supero-lateral crest at the level of spinous process of S2 to the apex of sacral hiatus
- (d) Distance from S2 to the apex of sacral hiatus
- (e) Distance from S2 to the base of sacral hiatus

**Table 1: Various parameters measured in males.**

S. No.	Parameters in mm (n=46)	Mean (mm)	SD	SEM
1.	Distance between the right and left lateral sacral crests at S2 spinous process	51.00	6.37	9.39
2.	Distance between the right lateral sacral crest at the level spinous process of S2 and the apex of sacral hiatus	45.91	6.94	1.02
3.	Distance between the left lateral sacral crest at the level spinous process of S2 and the apex of sacral hiatus	44.74	6.77	0.99
4.	Vertical distance between spinous process of S2 to apex of sacral hiatus	38.83	9.33	1.38
5.	Vertical distance between spinous process of S2 to base of sacral hiatus	59.20	10.81	1.59

SD: Standard deviation

SEM: Standard error of mean

**Table 2: Various parameters measured in females.**

S. No.	Parameters (n=14)	Mean (mm)	SD	SEM
1.	Distance between the right and left lateral sacral crests at S2 spinous process	52.7	5.30	1.42
2.	Distance between the right lateral sacral crest at the level spinous process of S2 and the apex of sacral hiatus	42.50	11.23	2.99
3.	Distance between the left lateral sacral crest at the level spinous process of S2 and the apex of sacral hiatus	42.50	10.97	2.93
4.	Vertical distance between spinous process of S2 to apex of sacral hiatus	32.4	1.64	4.40
5.	Vertical distance between spinous process of S2 to base of sacral hiatus	52.80	9.18	2.45

SD: Standard deviation

SEM: Standard error of mean

iii) The mean distance between the left lateral sacral crest at the level spinous process of S2 and the apex of SH was  $44.74 \pm 6.77$  mm in males and  $42.50 \pm 10.97$  mm in females.

iv) Vertical distance between spinous process of S2 to apex of SH was  $38.83 \pm 9.33$  mm in males and  $32.4 \pm 1.64$  mm in females.

v) Vertical distance between spinous process of S2 to base of SH was  $59.20 \pm 10.81$  mm in males  $52.80 \pm 9.18$  mm in females.

## DISCUSSION

Surgeries conducted on the areas innervated by sacral nerves can be performed easily if sacral nerves are blocked. Sacral approach to epidural space can effectively and reliably block sacral nerves.<sup>4</sup> SH is an

important gateway for various clinical procedures like trans- sacral thecaloscopy, CEB and injection of drugs into epidural space.<sup>5</sup>

Due to the anatomical variations of the level of apex or difficulty in palpation of SH in some patients, certain anatomical landmarks have been described in this study which will help the clinicians to approach SH easily and perform various procedures successfully. Mean distance between the right and left lateral sacral crests at the level of S2 spinous process was  $51.00 \pm 6.37$  mm in males and  $52.7 \pm 5.30$  mm in females in the present study. The data obtained in our study was in accordance to the study of Phalgun and Baskaran<sup>6</sup> who conducted their study on the sacra of Southern origin suggesting that the sacra of South Indians is quite similar to that of North Indians. On the contrary, the present study was not consistent with the studies of Senoglu et al. and Bhattacharya et al.<sup>7,8</sup> Regional and ethnic variation could be a possible explanation for this difference (Table 3).

**Table 3: Comparison between various parameters of dorsal sacrum with study of other authors.**

Parameters in mm	Phalgunan and Baskaran <sup>6</sup>	Senoglu et al. <sup>7</sup>	Bhattacharya et al. <sup>8</sup>	Current study
Distance between the right and left lateral sacral crests at S2 spinous process	$55.46 \pm 16.51$	$66.5 \pm 53.5$	$64.8 \pm 5.23$	$51.00 \pm 6.37$ (M)
				$52.7 \pm 5.30$ (F)
Distance between the right lateral sacral crest at the level spinous process of S2 and the apex of sacral hiatus	$50.83 \pm 19.57$	$67.1 \pm 10.0$	$58.4 \pm 2.71$	$45.91 \pm 6.94$ (M)
				$42.50 \pm 11.23$ (F)
Distance between the left lateral sacral crest at the level spinous process of S2 and the apex of sacral hiatus	$49.76 \pm 19.55$	$67.5 \pm 9.5$	$58.37 \pm 2.77$	$44.74 \pm 6.77$ (M)
				$42.50 \pm 10.97$ (F)

**Table 4: Comparison between the distance of apex and base of sacral hiatus with the studies of other authors.**

Parameter (mm)	Gupta et al. <sup>5</sup>	Phalgunan and Baskaran <sup>6</sup>	Bhattacharya et al. <sup>8</sup>	Current study
Vertical distance between S2 to apex of the sacral hiatus	38.28 ± 5.42	31.1 ± 16.03	43.41 ± 8.55	Male= 38.83 ± 9.33
				Female= 32.4 ± 1.64
Vertical distance between S2 to the base of sacral hiatus	59.23 ± 4.77	60.23 ± 17.97	79.64 ± 8.92	Male= 59.20 ± 10.81
				Female= 52.80 ± 9.18

Phalgun and Baskaran,<sup>6</sup> Senoglu et al. <sup>7</sup> and Bhattacharya et al.<sup>8</sup> found the mean distance between the right and left lateral sacral crest and the apex of SH to be greater in their studies as compared to the data obtained in the current study. The mean distance between the right and left lateral sacral crest at the level of spinous process of S2 and the apex of SH in our study was R=45.91 ± 6.94 and L=44.74 ± 6.77 mm in males and R= 42.50 ± 11.23 and L=42.50 ± 10.97 mm in females. Sacra of different population group may have different dimensions (Table 3).

Between the right and left supero-lateral crests and the apex of the SH an equilateral triangle was found to be occurring in four sacra (14.2%)<sup>6</sup>, 29%<sup>9</sup> and 95%<sup>5</sup>. In another study, equilateral triangle was found between the posterior superior iliac spine and SH in 51% specimens.<sup>10</sup> Our findings were not consistent with these studies. In the present study an isosceles triangle was formed between the right and left lateral sacral crest at the level of S2 spinous process and the apex of the sacral hiatus. Bhattacharya et al.<sup>8</sup> also found it to be an isosceles triangle in majority of cases.

Vertical distance between spinous process of S2 to apex of SH was 38.83 ± 9.33 mm in males and 32.4 ± 1.64 mm in females in the present study. Gupta et al.<sup>5</sup> were also of same opinion. But Phalgunan and Baskaran<sup>6</sup> and Bhattacharya et al. <sup>8</sup> differed in their opinion. Regional variation could be the possible cause for this difference.

In the present study vertical distance between spinous process of S2 to base of SH was 59.20 ± 10.81 mm in males 52.80 ± 9.18 mm in females. Our study was consistent with the studies of Gupta et al.<sup>5</sup> and Phalgunan and Baskaran.<sup>6</sup> Though Bhattacharya et al. <sup>8</sup> differed in their view. Vertical distance between S2 to the base of SH according to them was longer than the data obtained in the current study. This difference could be attributed to their sample of study being from Eastern India as compared to the present study where the North Indian sacra were seen (Table 4).

Data obtained from the present investigation suggests that the dorsal sacra forms an isosceles triangle in North Indians between the right and left supero-lateral crests measured at the level of spinous process of S2 and the apex of the sacral hiatus contrary to the findings of other authors.<sup>5,6,9,10</sup> Length of the sacral hiatus obtained in the present study was 20.37 mm, 20.40 mm in males and females respectively. This was consistent with the findings of Gupta et al.<sup>5</sup> who suggested it to be 20.71 mm. Longer length of sacral hiatus was observed in the studies of Phalgunan and Baskaran<sup>6</sup> and Bhattacharya et al.<sup>8</sup> who observed it to be 29.13 mm and 36.23 mm respectively.

Though all these three studies were carried out on Indian subjects yet SH was longer in the work done by Phalgunan and Baskaran<sup>6</sup> and Bhattacharya et al.<sup>8</sup>. Length of the SH could be different in different regions.

The present study is an attempt to revisit the anatomy of dorsal sacral dimensions to provide a data which will help the clinicians in approaching SH of North Indian population easily. As the sample size of female sacra was small therefore it is difficult to comment on the sexual dimorphism of the SH.

*Funding: None*

*Competing interests: None declared*

*Ethical approval: Not required*

## REFERENCES

1. Standring S. The back. In: Newell RLM, Collins P, Healy JC, eds. Gray's Anatomy The Anatomical Basis of Clinical Practice. 40th ed. UK, US, Churchill Livingstone Elsevier; 2008: 724 –728.
2. Chakraverty R, Paul P, and Karen I. Which spinal levels are identified by palpation of the iliac crests and the posterior superior iliac spines? J Anat 2007; 210(2): 232–236.
3. Agur MRA, Dalley FA. In: Grant's Atlas of Anatomy, 12th ed. New Delhi, London, New York,

- Woter Kluwer/Lippincott Williams Wilkins; 2009: 337.
4. Aggarwal A, Aggarwal A, Harjeet, Sahni D. Morphometry of sacral hiatus and its clinical relevance in caudal epidural block. *Surg Radiol Anat* 2009; 31(10): 739-800.
  5. Gupta R P, Gupta N, Rai A: Morphometric Study of Sacral Hiatus with Significance in Interventional Clinical Procedure. *International Journal of Contemporary Surgery* 2013; 1( 2): 59-63.
  6. Phalgunan V, Baskaran S Morphometrical analysis of sacral hiatus and its clinical significance. *The Health Agenda* 2013; 1(1): 10 – 15.
  7. Senoglu N, Senoglu M, Oksuz H, Gumusalan Y, Yuksel K Z, Zencirci B et al. Landmarks of the sacral hiatus for caudal epidural block: an anatomical study. *BJA* 2005; 95 (5): 692-695.
  8. Bhattacharya S, Majumdar S, Chakraborty P, Mazumdar S, Mazumdar A . A morphometric study of sacral hiatus for caudal epidural block among the population of West Bengal. *Indian J Basic & App Med Res* 2013; 7(2): 660-667.
  9. Patil D, Jadav H, Kumar B, Mehta CD, Patel VD. Anatomical study of sacral hiatus for caudal epidural block. *Nat J Med Res* 2012; 12(3): 272-275.
  10. Aggarwal A, Kaur H, Yatindra K, Aditya K, Subramanyam R, Sahni D et al. Anatomical consideration of caudal epidural space: a cadaver study. *Clinical Anatomy* 2009; 22(6): 730-737.

DOI: 10.18203/2320-6012.ijrms20150170

**Cite this article as:** Chauhan R, Nagar M. Dorsal sacral dimensional anatomy-revisited. *Int J Res Med Sci* 2015;3:1473-7.