

## Original Research Article

# Morphometric analysis of menisci of adult human knee joint in North Indian population

Jyoti Rohila<sup>1\*</sup>, Suresh Kanta Rathee<sup>1</sup>, Suresh Kumar Dhatarwal<sup>2</sup>, Zile Singh Kundu<sup>3</sup>

<sup>1</sup>Department of Anatomy, <sup>2</sup>Department of Forensic Medicine, <sup>3</sup>Department of Orthopedics, Pandit Bhagwat Dayal Sharma Post Graduate Institute of Medical Sciences, Rahtak, Haryana, India

**Received:** 02 December 2016

**Accepted:** 02 January 2017

### \*Correspondence:

Dr. Jyoti Rohila,

E-mail: [jyotirohilla41@yahoo.in](mailto:jyotirohilla41@yahoo.in)

**Copyright:** © the author(s), publisher and licensee Medip Academy. This is an open-access article distributed under the terms of the Creative Commons Attribution Non-Commercial License, which permits unrestricted non-commercial use, distribution, and reproduction in any medium, provided the original work is properly cited.

## ABSTRACT

**Background:** Of the synovial joints in the body knee joint is the largest. Each meniscus is a piece of fibrocartilage with a thickened outside edge and a thin inner edge so that it is wedge-shaped in cross section. The purpose of the present study was to establish database on standard dimensions in knee menisci of adults of north Indian population.

**Methods:** The sample for this study was collected from April, 2012 to June, 2013. For this study, 200 menisci (100 right and left each) of 50 adult humans were taken for analysis. Measurements were done with the help of non-elastic thread and digital vernier calipers. All dissections were performed in a systematic fashion.

**Results:** The width of the lateral meniscus was significantly different from medial meniscus with lateral and medial menisci widest in middle and posterior third respectively. The middle one third of both lateral and middle menisci was the thickest.

**Conclusions:** It is always good to have a set of anatomical morphometric parameters of the menisci like the width and thickness. The measurements of suitable grafts may provide a more acceptable meniscal replacement in the future.

**Keywords:** Menisci, Morphometry, Thickness, Width

## INTRODUCTION

Of the synovial joints in the body knee joint is the largest. It is a compound joint that includes two condylar joints between the femur and the tibia, the former being partly divided by menisci.

The menisci (formerly called semilunar cartilages) of the knee lie within the knee joint between the femur and tibia and somewhat adapt the tibial and femoral condyles to each other. Each meniscus is a piece of fibrocartilage with a thickened outside edge and a thin inner edge so that it is wedge-shaped in cross section. The menisci are largely avascular, but are more vascular at their extremities than elsewhere.<sup>1</sup> In most cases, the width of

the medial meniscus, that is, from the thick convex periphery to the thin concave central margin, differs in the anterior and posterior halves. The anterior is narrow whereas the posterior is broad but some variations is encountered and occasionally little difference in width is noted between the anterior and posterior halves.

The periphery of the lateral meniscus is thicker and the width of the meniscus is greater and more uniform in the anterior and posterior halves, than the medial part. The lateral meniscus, however, being subject to congenital anomalies, is also subject to greater variation in general configuration than is encountered on the medial side of the joint, for example, it is often wider in the middle segment than it is at either anterior or posterior horns.

The anatomical abnormalities and variations of intra-articular structures of the knee joint have recently become significant because of new techniques such as arthroscopy, computed tomography and magnetic resonance imaging. Removal of meniscus after trauma is the most commonly performed procedure in the knee and often leads to degenerative arthritis. Tears of the menisci are common. Most are in the avascular zones and if treatment is needed, are best resected. Peripheral tears in the vascular zones have the capacity to heal which makes repair a possibility.

Geometry of the articular surfaces of menisci has been shown to be an important determinant of stresses and strains within tissue during functions. If normal contact mechanics are to be successfully restored by meniscal transplant then geometric match between transplant and original meniscus must be considered in transplant selection procedure. The purpose of the present study was to establish database on standard dimensions and morphological variations, if any, in knee menisci of adults of north Indian population.

**METHODS**

The study was carried out in 50 adult human male cadavers with age ranging from 20 to 50 years. The study was conducted during medico-legal autopsies done in the Department of Forensic Medicine, PGIMS Rohtak, Haryana, India. Family members of the subjects were fully informed and written consent was taken before taking the specimen. This research work was approved by the Institutional Ethical Committee.

After the dissection of skin and muscles, the menisci were approached anteriorly by a longitudinal incision on each side of the joint capsule, cutting the patellar ligament and the collateral ligaments transversely. In order to expose the menisci clearly, the joint capsule and the intra articular ligaments were cut and the condyles were circumferentially detached from their soft tissue attachments, exposing the tibial plateau. Approximately 2-3 cm thick tibial plateau was taken out along with menisci with the help of electric saw. After that skin was stitched.

**Inclusion and exclusion criteria**

Specimens were analyzed for different measurements whose autopsies had been performed within 24 hours of death. Cases with any primary traumatic injury, any arthroscopic surgical interventions on knee joint and in which structures were seen to be distorted before or during autopsy were excluded.

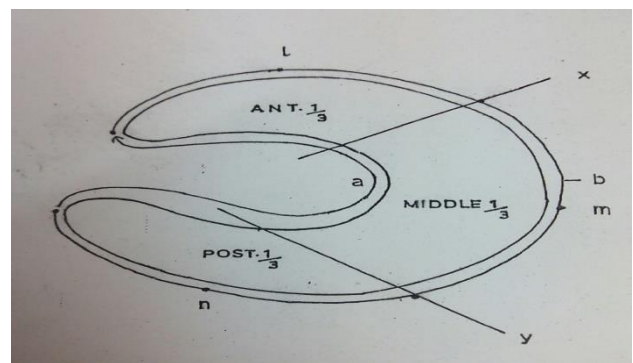
**Study duration and sample size**

The sample for this study was collected from April, 2012 to June, 2013. For this study, 200 menisci (100 right and

left each) of 50 adult humans were taken for analysis. All dissections were performed in a systematic fashion.<sup>3</sup>

**Measurements**


Firstly the length of each meniscus was measured, for this; a piece of non-elastic cotton thread was placed across the outer edge of the meniscus from the apex of the anterior horn to the apex of posterior horn. Next, the thread length was measured using a digital Vernier caliper (least count-0.02mm). Then, the distances between the anterior and posterior horns were measured using digital caliper, which was placed between the apex of the anterior horn and the apex of the posterior horn. The width was measured at three points - the anterior third, middle third, and posterior third (Figure 1).



a= Inner border length, b= Outer border length; The meniscus is divided into three equal parts by two lines x and y along the outer border length. The mid points of these three parts were marked as l, m, and n. The thickness of the outer border and width of meniscus to be noted at these three points (l, m and n).

**Figure 1: Meniscus of knee joint to showing measurements.**

From each point, the caliper was positioned from the outer edge to the inner edge of each meniscus. The thickness of the meniscus was determined using the same width points (Figure 2), and then the caliper was placed between the top and bottom edge in the outer circumference only. Measurements were repeated twice and the mean value was taken to avoid intra-observer bias. The data thus obtained was recorded on a standardized collection sheet.



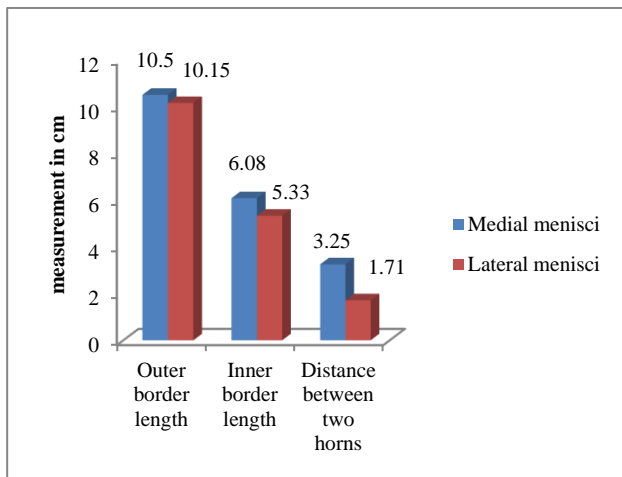
**Figure 2: Measurement of thickness of meniscus.**

**Statistical analysis**

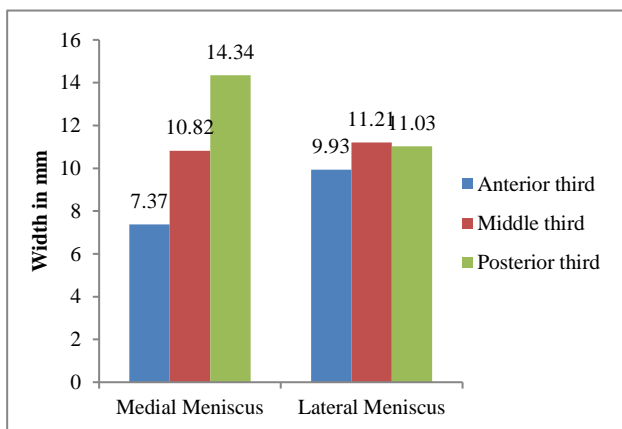
Data collected was analyzed using SPSS 20.0. Descriptive statistics were presented as mean and standard deviation and parametric test were applied (student t-test and analysis of variance (ANOVA)) to see significant difference between mean values. The level of significance was considered when p value was less than 0.05 (<0.05).

**RESULTS**

From the results obtained, it was observed that there was statistically significant difference in the length of the outer circumference (p<0.05) between the medial (10.50±0.65 cm) and lateral meniscus (10.15±0.72 cm). The difference between inner border length of medial (6.08±0.57 cm) and lateral menisci (5.33±0.75 cm) was significant (p<0.001). The distance between the anterior and posterior horn of the medial meniscus (3.25±0.37 cm) was significantly higher than that of the lateral meniscus (1.71±0.40 cm) (Figure 3).

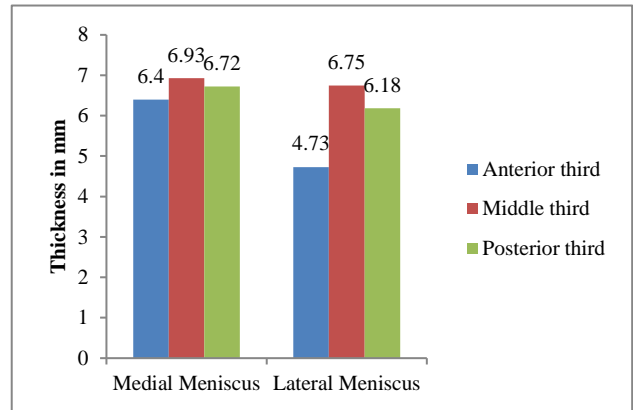


**Figure 3: Peripheral length between medial and lateral menisci.**



**Figure 4: Width of Medial and Lateral menisci.**

With regard to the width of the lateral meniscus, there was significant difference between the anterior (9.93±1.71 mm), middle (11.21±2.91 mm), and posterior thirds (11.03±1.40 mm). However, in the medial meniscus, the posterior third was the widest part (14.34±2.37 mm) followed by the middle (10.82±1.69 mm) and anterior third (7.37±1.06 mm). This finding was found to be statistically significant. Comparing the width of the medial and lateral menisci, a statistically significant difference (p <0.05) in two points was found (Figure 4).



**Figure 5: Thickness of medial and lateral menisci.**

When analyzing the thickness of the outer circumference of the medial meniscus, the anterior third (6.40±1.37 mm) appeared thinner compared to the middle (6.93±1.15 mm) and posterior thirds (6.72±1.12 mm). There was no significant difference between these two last thirds. In the lateral meniscus, the middle third (6.75±1.13 mm) was the thickest followed by the posterior (6.18±0.99 mm) and anterior third (4.73±1.12 mm), respectively (Figure 5).

Comparing the average thickness value of the medial meniscus with the value of the lateral meniscus, it was observed that the anterior third and posterior third of the medial meniscus were significantly thicker (p <0.05) compared to the lateral meniscus.

**DISCUSSION**

The data related to the morphology of the menisci is scarce; therefore, the main objective of this study was to analyze the morphometric variations present in the human knee meniscus, enriching the literature on this subject. In the present study, the outer and inner border lengths were significantly more in the medial meniscus than the lateral meniscus. Braz & Silva and Ashwini et al reported same findings regarding outer border length which were not significant.<sup>4,5</sup> On the other hand, Ashwini et al. reported that inner border length of medial meniscus (59.96±8.55 mm) was significantly more than (p<0.05) that of the lateral meniscus (49.0±5.49) mm which matched with present study results.<sup>5</sup> In present study,

inner border length results matched with the results of Ashwini et al whereas that of outer border length did not match with other studies.

When the distance between anterior and posterior horn in medial meniscus and lateral meniscus was compared, medial meniscus had significantly higher distance between two horns. Same findings were reported by Braz & Silva and Ashwini et al who reported significantly higher distance for medial meniscus between two horns than the lateral meniscus.<sup>4,5</sup> The findings of our study are consistent with the studies cited above. This greater proximity of the horns of the lateral meniscus may explain why they are less prone to injury.

In our specimens, the posterior third of medial meniscus was the widest part followed by the middle and anterior third ( $p=0.001$ ). Above results were in agreement with Moore and Dalley who described that the medial meniscus is larger posteriorly than anteriorly and also by Almeida et al.<sup>6,7</sup> Same findings were reported by Braz and Silva that the posterior third was the widest part ( $14.96\pm 2.66$  mm) followed by the middle ( $9.32\pm 2.24$  mm) and anterior third ( $7.68\pm 1.36$  mm).<sup>4</sup> Ashwini et al in a study in Kerala, India reported that the posterior third ( $11.28\pm 2.09$  mm) was the widest part of the medial meniscus ( $p=0.00$ ) than the anterior ( $6.52\pm 1.29$  mm) & middle thirds ( $6.66\pm 1.11$  mm).<sup>5</sup> Present study is in agreement with other studies cited above in terms of width of posterior third of medial meniscus which is the widest part.

With regard to the width of the lateral meniscus, we found that there was significant difference between the anterior, middle third, and posterior thirds. However, on individual analysis, no significant difference was found on comparing the width between middle third and posterior third. Ashwini et al reported for lateral meniscus that the posterior third part ( $9.36\pm 1.19$  mm) was the widest compared to the anterior third ( $8.08\pm 1.14$  mm) and the middle third parts ( $8.52\pm 2.12$  mm).<sup>5</sup> Braz and Silva reported that for width of the lateral meniscus, there was no significant difference between the anterior ( $11.32\pm 1.46$  mm), middle ( $11.16\pm 1.64$  mm), and posterior thirds ( $11.67\pm 1.54$  mm) while no statistically significant difference was reported by Almeida et al in the lateral meniscus between the three points analyzed.<sup>4,7</sup> Results of our study are not in agreement with other studies with reference to lateral meniscus as our study showed that middle one-third was the widest part whereas others reported posterior one third as the widest part.

In present study there was significant difference between medial and lateral meniscus in terms of width of its anterior one-third and posterior one third ( $p<0.05$ ) whereas middle one third part comparison was not found statistically significant ( $p>0.05$ ), whereas Braz and Silva reported significant difference ( $p<0.05$ ) in three points after comparing width of medial and lateral menisci.<sup>4</sup> According to Smillie, the lateral meniscus shows a width

higher and more uniform than the medial meniscus.<sup>9</sup> However, Testut et al and Didio mentioned that it is common for the medial meniscus to be a little wider than the lateral meniscus.<sup>10,11</sup> Result of our study is consistent with Testut et al and Didio which says that medial meniscus is little wider with average value of 10.84 mm than lateral meniscus with average value of 10.72 mm.<sup>11</sup>

According to Cailliet, the lateral meniscus shows an average width of 12-13 mm, while the medial meniscus has an average width of 10 mm.<sup>12</sup> According to Motta Filho et al, the lateral meniscus has an average width of 12 mm.<sup>13</sup> Average width of menisci in present study is less than the above study populations compared.

In medial meniscus, the thickness of all the three points was not significantly different from each other except the anterior and middle one-third. The middle third was the thickest part followed by the posterior and anterior third. Braz et al reported that the posterior third of the medial meniscus was the thinnest followed by anterior and middle thirds showing an average of 5.88 mm.<sup>4</sup> Almeida et al<sup>7</sup> reported that the middle third of medial meniscus was the thinnest (5.31 mm) followed by the posterior (5.91 mm) and anterior (5.92 mm) thirds, showing an average value of 5.71 mm. Ashwini et al reported that the posterior third of the medial meniscus was the thickest part and anterior third was the thinner.<sup>5</sup> Present study results do not corroborate with the results of any of the authors cited above in terms of thickness in medial meniscus. According to our study, middle third being the thickest part while anterior third part is the thinnest which may be due to squatting position frequently adopted by study population of this region.

With regard to the thickness of the lateral meniscus of our study, the thickness of all the three points was significantly different from each other. The middle third was the thickest part whereas anterior third was the thinnest. Braz et al, in the lateral meniscus, reported that the anterior third was the thinnest (4.40 mm) followed by the posterior (5.46 mm) and middle (6.52 mm) thirds, and their average value was 5.46 mm.<sup>4</sup>

Almeida et al reported that the lateral meniscus showed a significant difference among the anterior (3.57 mm), middle third (6.10 mm) and posterior (5.92 mm) thirds.<sup>7</sup> In contrast to above studies, study done by Ashwini et al reported that the posterior third ( $2.06\pm 9.3$  mm) of the lateral meniscus was the thickest part ( $p<0.05$ ) followed by middle third ( $1.76\pm 0.81$  mm) & anterior third ( $1.41\pm 0.51$  mm) was the least.<sup>4,5</sup> Our study is in consistent with Braz et al and Almeida et al in its measurement of thickness of lateral menisci.

In present study there was significant difference between medial and lateral meniscus in the thickness of its anterior and posterior one-third ( $p<0.05$ ), whereas the difference in the thickness in its middle one-third between medial and lateral meniscus was not found

statistically significant ( $p>0.05$ ). Braz and Silva<sup>4</sup> reported anterior third whereas Ashwini et al reported middle third of medial meniscus significantly thicker ( $p<0.05$ ) compared to the lateral meniscus.<sup>5</sup>

Menisci of both medial and lateral side showed significant difference in anterior and posterior third in the present study while other workers reported significant difference in anterior and middle part showing that our menisci parameters are different from the other study population.

According to Smillie, the morphological differences of menisci, in particular, in the thickness and width can determine not only the possibility of an injury, but also the location and the kind of injury.<sup>7</sup> It was further suggested that the narrow meniscus is less prone to ruptures than the wide. This supposition is justified because the narrow meniscus is liable to a less action of femoral condyle. This point is of clinical significance and studies can be done on the status of injury in the future as data regarding morphometry of knee menisci is very scarce in North-Indian population.

## CONCLUSION

Menisci perform important functions and are frequently exposed to injuries. Meniscal transplantation is being evaluated to restore normal contact mechanisms to the joint. In allograft transplantation of the torn knee menisci, a mismatch would lead to the failure of the allograft or might end up in the degenerative changes.

It is always good to have a set of anatomical morphometric parameters of the menisci like the width and thickness. These grafts may provide a more acceptable meniscal replacement in the future.

*Funding: No funding sources*

*Conflict of interest: None declared*

*Ethical approval: The study was approved by the Institutional Ethics Committee*

## REFERENCES

1. Hollinshead WH. Anatomy for Surgeons: The back and limbs. New York: Hoeber & Harper. 1958;783-5.
2. Chandler SB. The semilunar cartilages of the knee joint. Anat. Rec. 1949;103:531.
3. Murlimanju BV, Nair N, Pai S, Pai M, Chethan P, Gupta C. Morphological study of the menisci of the knee joint in the adult cadavers of the South Indian population. MMJ. 2010;23(2):270-5.
4. Braz PRP, Silva WG. Meniscus morphometric study in humans. J Morphol Sci. 2010;27(2):62-6.
5. Ashwini C, Nanjaiah CM, Saraswathi GS, Shamsundar NM. Morphometric study of menisci of human knee joint. Int J Cur Res Rev. 2013;5(8):118-25.
6. Moore KL, Dalley AF. Anatomia orientada para clínica. 4<sup>th</sup> ed. Rio de Janeiro; Guanabara Koogan: 2001.
7. Almeida SKS, De Moraes ASR, Tashimiro T, Neves Se, Toscano Ae, De Abreu RRM. Morphometric study of menisci of the knee joint. Int J Morph. 2004;22(3):181-4.
8. Kaur A, Sodhi S. Morphometric study of the medial meniscus of the knee joint in thirty adult male cadavers. J Acad and Indust Res. 2013;2(4):226-9.
9. Smillie IS. Injuries of the knee Joint. 4<sup>th</sup> ed. London: Living Stone. 1975;79-84.
10. Testut L, Latarjet A. Tratado de Anatomía Humana. 10<sup>th</sup> ed. Barcelona. Salvat. 1975.
11. Didio LJA. Tratado de Anatomia Aplicada. 2<sup>nd</sup> ed. São Paulo. Atheneu. 2002.
12. Cailliet RMD. Síndromes Dolorosas. Joelho: dor e incapacidade. Río de Janeiro; Manole. 1976.
13. Motta Filho LAJ, Motta LAJ, Motta Filho GR. Menisco lateral discóide: correlaçãoanátomo-clínica. Rev Bras Ortop. 1999;34(8):457-60.

**Cite this article as:** Rohila J, Rathee SK, Dhatarwal SK, Kundu ZS. Morphometric analysis of menisci of adult human knee joint in North Indian population. Int J Res Med Sci 2017;5:569-73.