

## Case Report

# Sacrococcygeal giant hemangiopericytoma: a rare presentation and management

Jose de Jesus Orozco<sup>1</sup>, Enrique Vaca Perez<sup>2</sup>, Jose Eduardo Telich Tarriba<sup>1</sup>, Enrique Chavez Serna<sup>1\*</sup>, Enrique Velazquez Zabaleta<sup>1</sup>, Heriberto Garza de la Llave<sup>1</sup>, Antonio Ruiz Fernandez<sup>1</sup>

<sup>1</sup>Division of Plastic and Reconstructive Surgery, Dr. Manuel Gea Gonzalez General Hospital, México City, México

<sup>2</sup>Division of Oncology Surgery, Del Bajío General Hospital, Leon, México

**Received:** 09 April 2019

**Accepted:** 04 May 2019

### \*Correspondence:

Dr. Enrique Chávez Serna

E-mail: [Enrique.chavez.serna@gmail.com](mailto:Enrique.chavez.serna@gmail.com)

**Copyright:** © the author(s), publisher and licensee Medip Academy. This is an open-access article distributed under the terms of the Creative Commons Attribution Non-Commercial License, which permits unrestricted non-commercial use, distribution, and reproduction in any medium, provided the original work is properly cited.

## ABSTRACT

Hemangiopericytoma is a tumor derived from the mesenchymal cells that surround the capillary of blood vessels. It has a several anatomic localization and clinic scenarios, it's presentation with a media in the 6th decade; an early diagnostic and treatment represents a better clinic scenario for the patient. The next article presents a case report of a 51 years old man with a tumor localized in the sacrococcygeal space, with big dimensions that limited his daily activities without other symptomatology, image studies with no evidence of distant progression. Surgical resection was performed, removing mass depending from mayor and minor gluteus, achieving an immediate reconstruction with a satisfactory aesthetic and functional result. The authors presented this rare case due to the lack of published information and how it can be treated to achieve good results.

**Keywords:** Endothelium, Hemangiopericytoma, Neoplasm, Reconstruction, Sacrococcygeal, Vascular

## INTRODUCTION

Hemangiopericytoma is a neoplasm of vascular origin first described in 1942 by Stout and Murray. Of low frequency and variable degree of malignancy, it represents 5% of all sarcomatous tumors.<sup>1,2</sup> It can occur in any anatomical location, however, in the lower extremities, retroperitoneum, pelvis, head and lungs, a higher incidence is reported.<sup>3</sup>

Being a tumor of vascular origin, its precursor cell are Zimmerman's pericytes; a type of smooth muscle cells that surround small blood vessels. Reports of this type of lesions in the sacro-coxigea region are rarely larger than 20 cm and for its resection it should be a broad approach, with free surgical margins and adjuvant radiotherapy.<sup>4</sup> These patients should be monitored regularly for their

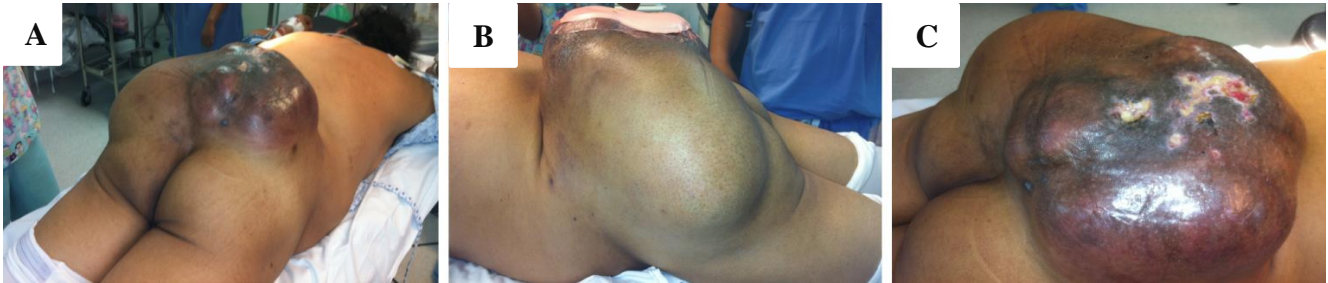control. We present a case of a large lesion of slow growth, in an unusual anatomical site.

## CASE REPORT

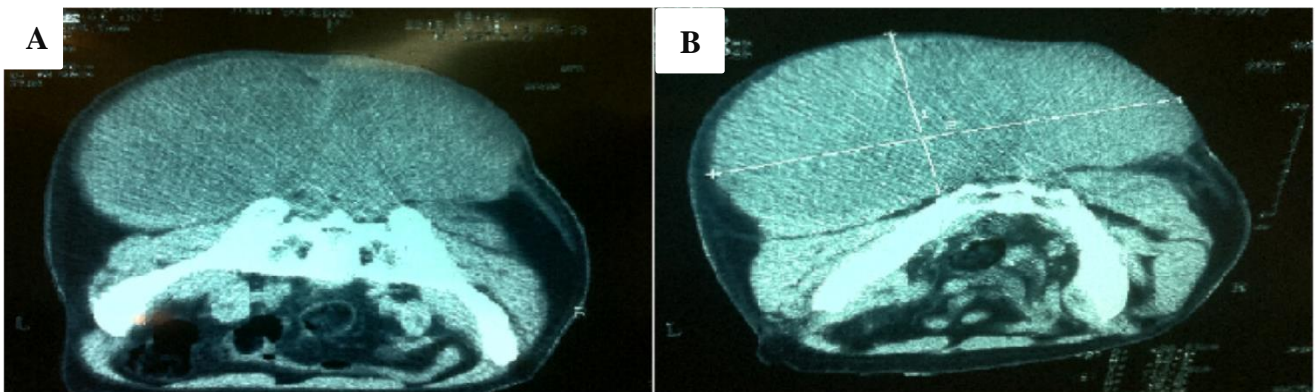
Male patient of 51 years of age, farmer, with chronic exposure to fertilizers and organic compounds; does not refer to clinical or surgical history of importance. He began his current condition 7 years ago with the presence of a tumor in the slowly growing gluteal region. On physical examination, large volume lesion, multilobulated, adhered to deep planes, not painful, with areas of skin ulceration. It does not present secretion discharge, nor infection data, Karnofsky 100%, cervical and inguinal adenopathies not palpable. The position of decubitus and ambulation is impeded. Approximate dimensions of 40x22x14cm (Figure 1A, Figure 1B, Figure 1C). The patient was received by the Oncology

Surgery Service with a biopsy that reports epithelioid hemangioepithelioma without vascular permeation. A simple and contrasted Computed Axial Tomography is performed that reports: Tumor localized in soft tissues of

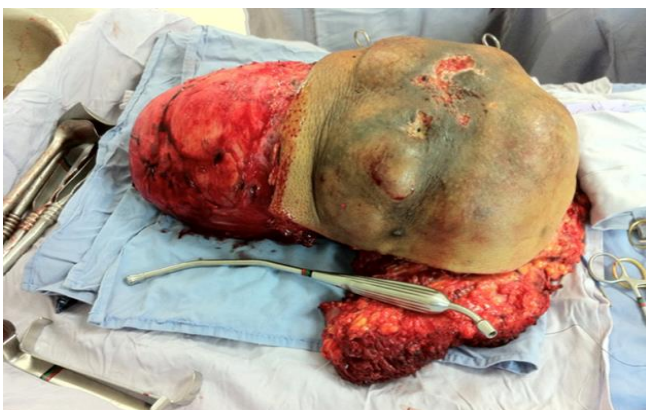lumbosacral region of left predominance that exceeds the midline, without apparent osseous invasion (Figure 2A, and 2B).



**Figure 1: Preoperative clinical photographs. tumor injury of large dimensions in the lumbosacral region, (A) Three-quarter view, skin ulcerations are seen, (B) Side view of the tumor, (C) posterior view.**



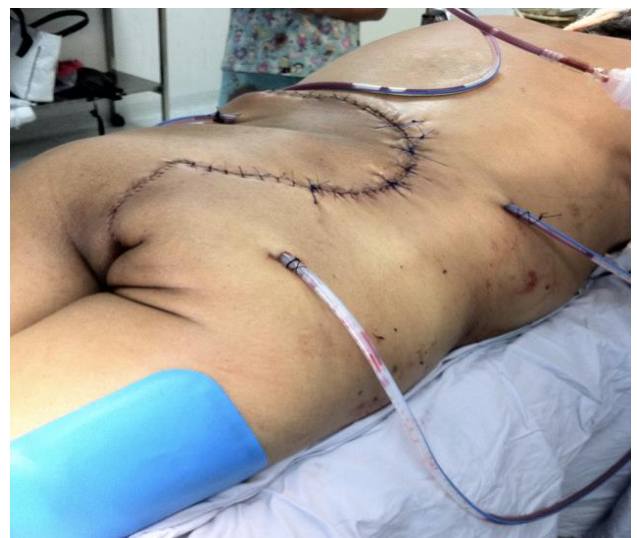**Figure 2: Computed Axial Tomography slices. (A) Slice at the level of the largest transversal diameter, (B) Tumor localized in soft tissues of lumbosacral region of left predominance that exceeds the midline, without apparent osseous invasion.**



**Figure 3: Macroscopic tumor. Piece obtained from the surgical procedure.**

Magnetic resonance imaging shows a diffuse lesion of general botryoid morphology that presents heterogeneous ovoid components predominantly hyperintense in fat suppression and with post gadolinium centrifugal reinforcement with apparent extension to the left sacrotuberal ligament. Resection was performed with

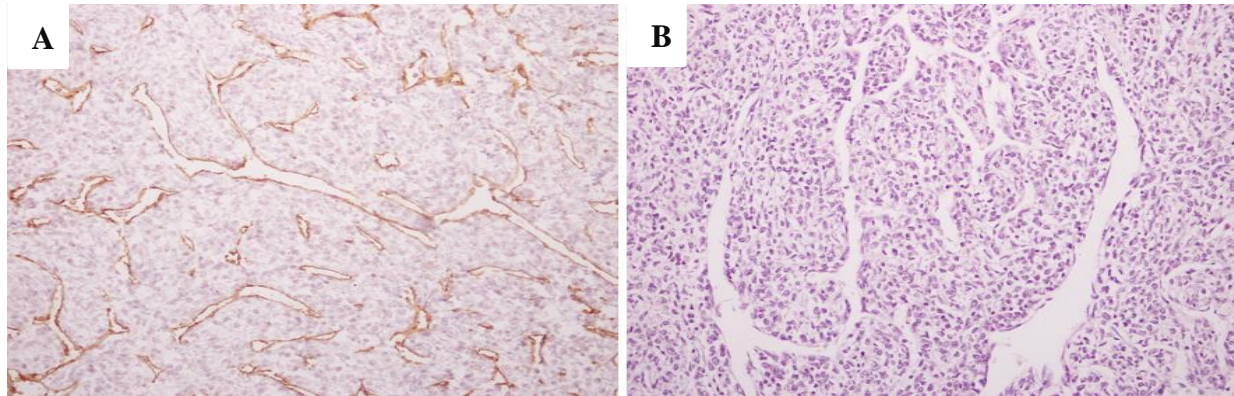
wide margins and reconstructed with contralateral skin flap advance (Figure 3 and Figure 4).



**Figure 4: Immediate postoperative clinical photographs, reconstruction with advancement flap.**

The histopathological study with Hematoxylin-Eosin stain reports a solid neoplastic lesion formed by oval and elongated cells in the periphery of vascular spaces of multiple sizes (Figure 5A). Diagnosis by the pathology department: Hemangiopericytoma Grade 2. Immunohistochemistry with positive reaction for CD34,

predominantly in the endothelium of the vascular spaces of the perivascular pattern of the neoplastic cells (Figure 5B). After 5 days the patient left the hospital with adjuvant radiotherapy; Currently the patient continues in clinical surveillance without the presence of recurrence.



**Figure 5: Histopathological study. (A): Hematoxylin and eosin Image (20x). Solid neoplastic lesion formed by oval and elongated cells in the periphery of vascular spaces of variable sizes. (B): CD34 Image (20x): Immunohistochemistry reaction for CD34 which evidences the endothelium of the vascular spaces accentuating the perivascular pattern of the neoplastic cells.**

## DISCUSSION

Sarcomas are a rare group of heterogeneous neoplasms derived from mesoderm with uncertain biological behavior and an underestimated incidence. It constitutes 2.5% of all soft tissue neoplasms and 1% of all vascular tumors. With a peak incidence in the fourth and fifth decade of life, its diagnosis is complicated in early stages. The clinical presentation is nonspecific, the pain is associated with the expansion of the neoplasm and usually has a painless, slow and progressive growth. Palpation of the tumor is the sign most frequently found (96%); Characteristically, the hemangiopericytoma is a spongiform lesion, brown, well circumscribed, surrounded by a pseudo-capsule, often there are satellite nodules. Imaging studies play a fundamental role in the diagnosis and appropriate treatment, the vascular nature of the tumor is important for management, reveals the exact source of the blood supply.

The diagnosis of certainty is only obtained through histological examination, characterized by being highly cellular, composed of spindle cells with round or ovoid nuclei and scarce cytoplasm, the mitotic index is variable, as well as the degree of reticulin staining. Zimmerman pericytes are a modified muscle cell without myofibrils that surround small blood vessels. Embedded within the basal membrane of the capillaries, serve as scaffolding and communicate with endothelial cells by direct physical contact, as well as paracrine signaling pathways, increasing angiogenesis and capillary stability.<sup>7</sup> The

fusiform aspect of the cells in this type of tumors makes it difficult to identify the precursor cell, so the immunohistochemical study will be necessary, they will be positive for CD34 and vimentin, and negative for Bcl-2 and CD 99. The treatment of choice is radical resection of the neoplasm with free borders, systemic chemotherapy is reserved for metastasis and recurrence. Metastases appear in 37-65% of cases and are distributed, in order of frequency, in lungs, bone tissue and liver.<sup>6</sup> The case presented is infrequent, both in size of the neoplasm and in its location; its evolution was silent without causing greater affectation to the patient's daily activities, for which reason it came 7 years after the appearance of the same.

The diagnostic approach included all extension studies to assess distant disease or loco-regional invasion, which was not demonstrated, so it was planned for resection and reconstruction in the same surgical time. There are few reports in the literature of tumors of such extension, since it is usually performed in a timely manner with extensive resections and follow-up. Due to the location of the neoplasm and the adequate surgical planning, a resection with negative margins was achieved and a reconstruction with underlying tissues was achieved without the need to use expanders or free flaps to achieve it. The patient's functional result achieved that he could walk 1 week after the surgery and be able to return to his daily activities within 1 month of the procedure with virtually no sequelae.

## CONCLUSION

Neoplasms of vascular origin represent a challenge in the surgical approach for its resection, in lumbosacral region and large volume report minimal frequency. The clinic will be the initial finding, the location will be of great importance because of the functional structures involved. Its diagnosis must be rigorous due to the vascular etiology, the histopathology will always be the most important diagnostic tool. The resection, as well as the reconstructive aspect, should be planned from the beginning in order to obtain the best functional and aesthetic results from a first surgical time.

*Funding: No funding sources*

*Conflict of interest: None declared*

*Ethical approval: Not required*

## REFERENCES

1. Onokl T, Kanno H, Alzawa T, Hashimoto K, Itol E, Ozawa H. Recurrent Primary osseus hemangiopericitoma in the thoracic spine: a case report and literature review. *Eur Spine J.* 2018 Jul;27(Suppl 3):386-392
2. Damodaran O, Robbins P, Knuckey N, Bynevelt M, Wong G, Lee G. Primary intracranial haemangiopericytoma: comparison of survival outcomes and metastatic potential in WHO grade II and III variants. *J Clin Neurosci.* 2014;21(8):1310-4.
3. Zhang G, Zhang L, Li D, Wu Z, Zhang J. Analysis of prognostic factors, survival rates, and treatment in anaplastic hemangiopericytoma. *World Neurosurg.* 2017 Aug 1;104:795-801.
4. Lorigan J, David C, Evans H, Wallace S. The Clinical and Radiological Manifestations of Hemangiopericytoma. *AJR.* 1989;153:345-9.
5. Enzinger FM, Smith BH. Hemangiopericytoma. An analysis of 106 cases. *Hum Pathol.* 1976;7:61-82.
6. Catalano PJ, Brandwein M, Shah DK, Urken ML, Lawson W, Biller HF. Sinonasal hemangiopericytomas: a clinicopathologic and immunohistochemical study of seven cases. *Head Neck.* 1996;18:42-53.
7. Stout AP, Murray MR. Hemangiopericytoma: vascular tumor featuring Zimmermans pericytes. *Ann Surg.* 1942;116:2633.
8. Fukunaga M, Shimoda T, Nikaido T, Ushigome S, Ishikawa E. Soft tissue vascular tumor. A flowcytometric DNA analysis. *Cancer.* 1993;71:2233-41.
9. Morandi U, Stefani A, De Santis M, Paci M, Lodi R. Preoperative embolization in surgical treatment of mediastinal hemangiopericytoma. *Ann Thorac. Surg.* 2000;69:937-9.
10. Damodaran O, Robbins P, Knuckey N, Bynevelt M, Wong G, Lee G. Primary intracranial haemangiopericytoma: comparison of survival outcomes and metastatic potential in WHO grade II and III variants. *J Clin Neurosci.* 2014;21(8):1310-4.

**Cite this article as:** Orozco JDJ, Perez EV, Tarriba JET, Serna EC, Zabaleta EV, Llave HG, et al. Sacrococcygeal giant hemangiopericytoma: a rare presentation and management. *Int J Res Med Sci* 2019;7:2445-8.