

Original Research Article

Histopathological spectrum of neoplastic lesions of female reproductive system-a two-year experience in Eastern Nepal

Mrinalini Singh*, Krishna Kumar Jha, Prija Poudyal, Santosh Upadhyay Kafle

Department of Pathology, Birat Medical College and Teaching Hospital, Tankisinwari, Morang, Nepal

Received: 12 December 2017

Accepted: 09 January 2018

***Correspondence:**

Dr. Mrinalini Singh,

E-mail: guddisinghdas4@yahoo.co.in

Copyright: © the author(s), publisher and licensee Medip Academy. This is an open-access article distributed under the terms of the Creative Commons Attribution Non-Commercial License, which permits unrestricted non-commercial use, distribution, and reproduction in any medium, provided the original work is properly cited.

ABSTRACT

Background: Neoplastic lesions of female reproductive system (FRS) consist majority of surgical cases. The aim of this study is to find out the frequency distribution of tumors occurring in FRS.

Methods: This is a retrospective study carried out in Birat Medical College, situated in eastern Nepal. All formalin fixed surgical specimen of FRS from August 2015 to September 2017 were subjected for histopathology and examined under light microscopy. All neoplastic lesions were included, and non-neoplastic lesions were excluded from the study.

Results: A total number of ninety (90) histopathological tissues representing various types of neoplastic lesion of FRS were studied. Out of which 6 (6.6%) tumors were from uterine cervix, (including 1 cervical leiomyoma and 5 squamous cell carcinoma cervix) 45(50%) tumors were from uterine body, (all leiomyoma) 20 (22.2%) tumors were from ovary (including 9 mature teratoma, 1 immature teratoma, 6 mucinous cystadenoma and 4 cases of serous cystadenoma) and 19 (21.2%) tumors were from breast (including 16 fibroadenoma, 1 lactational adenoma, 2 infiltrating ductal carcinoma and 1 comedo carcinoma). Majority 81(90%) were benign and 9 (10%) were malignant. Most common benign tumor was leiomyoma of uterine body and most common malignant tumor was squamous cell carcinoma of uterine cervix both commonly occurring in the age group of 41-50 years.

Conclusions: Benign tumor, leiomyoma is the common tumor occurring in FRS. Carcinoma of the cervix is the common malignant tumor.

Keywords: Benign tumors, Leiomyoma, Malignant tumors, Squamous cell carcinoma cervix

INTRODUCTION

Female reproductive system includes ovaries, fallopian tubes, uterus (body /corpus and cervix) vagina, vulva and breasts. Common sites for the occurrence of tumors are breast, ovaries, cervix and endometrium.

Tumors of fallopian tubes; vulva and vagina are less common. Breast cancer and the cervical cancer are the two common cancers occurring in women. Almost 80% of the new cases of cervical cancer occur in the

developing countries.¹ On the other hand, breast cancer incidence is higher in develop countries because it is associated with the Western lifestyle.

Most of the time these tumors do not show any specific symptoms. That is why they come into medical attention only when they become larger in size. The study was done to find out the age wise frequency of various histopathological types of neoplasms (both benign and malignant) of female reproductive system and to compare the data with other studies.

METHODS

This is the retrospective study done in the department of pathology Birat Medical College and Teaching Hospital, Tankisinwari Morang Nepal for the period of August 2015 to September 2017. The patient’s clinical profile and their histopathological findings were retrieved and collected from the data available in the pathology department and were analyzed. Various surgical specimens were from surgical procedures including Mastectomy, excision biopsy, trucut biopsy (from breast), Pan hysterectomy, hysterectomy, cystectomy and cervical biopsies. The specimens were fixed in 10% formalin. The gross examinations of surgical specimens were done in the department of histopathology by the pathologist. Sections were taken from the representative areas. Paraffin blocks were prepared. After cutting, the slides were stained with hematoxylin and eosin stains, mounted with distyrene, a plasticizer and xylene (DPX). All histopathological tissues revealing neoplastic lesions were included in the study. All the tumors were classified according to the standard set by World Health Organization-Classification of Tumours of the Breast and Female Genital Organs.

RESULTS

A total number of ninety (90) cases of neoplasm of female reproductive system were observed. Out of which (81cases) 90% was benign tumor and (9cases) 10% was malignant tumor. Most common benign tumor was leiomyoma comprising of (46cases) 51.11% of the total tumor. Majority forty-five (45 cases) were seen arising from uterine body and only one (1 case) was seen arising from uterine cervix. Other benign tumors were from ovary comprising of mature cystic teratoma nine (9) cases, mucinous cystadenoma six (6) cases, and serous cystadenoma four (4) cases.

Fifteen (15) benign tumors comprising of Fibroadenoma and one (1) tumor comprising of lactational adenoma was seen from breast. Out of the malignant tumor, majority was squamous cell carcinoma of cervix comprising of (5cases) 5.55% of the total tumor. (Figure 1). One (1) of the malignant tumor was immature teratoma of ovary, (Figure 2) and two (2) tumors comprised of infiltrating ductal carcinoma of breast and one (1) tumor was identified as comedo carcinoma of breast. (Figure3) (Table 1).

Table 1: Distribution of neoplasms of female reproductive tract in various organs.

| Organ | Number of cases(percentage) | Histopathological types |
|----------------|-----------------------------|--|
| Uterine cervix | 6 (6.66) | 1 leiomyoma and 5 squamous cell carcinoma of cervix |
| Uterine body | 45 (50%) | All leiomyomas |
| Ovary | 20 (22.22%) | 1 immature teratoma, 9 mature cystic teratoma, 6 mucinous cystadenoma, 4 serouscystadenoma, |
| Breast | 19 (21.12%) | 1comedocarcinoma, 2 infiltrating ductal carcinoma, 15 fibroadenoma and 1 lactational adenoma |

Table 2: Distribution of benign and malignant tumors in various age groups.

| Age in years | Benign | malignant |
|--------------|--------|-----------|
| 11-20 | 13 | |
| 21-30 | 20 | 1 |
| 31-40 | 20 | 1 |
| 41-50 | 24 | 5 |
| 51-60 | 4 | |
| 61-70 | | 1 |
| > 70 | | 1 |

Youngest age of the patient showing neoplastic lesion was 12 years old girl with fibroadenoma in right breast and the oldest patient in our study was 90 years old female with invasive ductal carcinoma in right breast. In our study 41-50 years was the commonest age group for both benign and malignant tumors. Our observation of various age groups of benign and malignant tumor is mentioned in (Table 2).

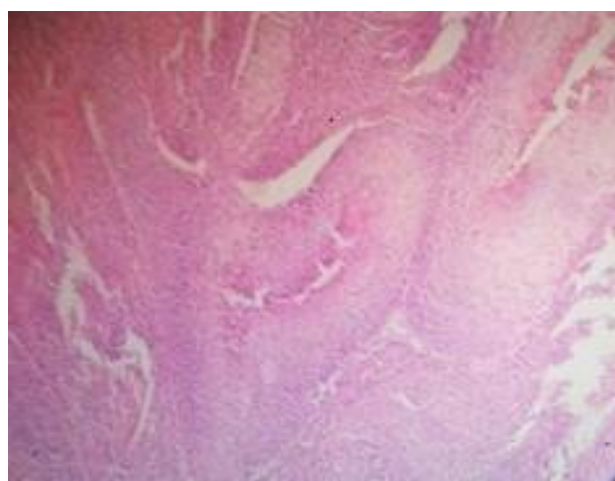


Figure 1: Hematoxylin and eosin stain slide of squamous cell carcinoma of cervix X4x view.

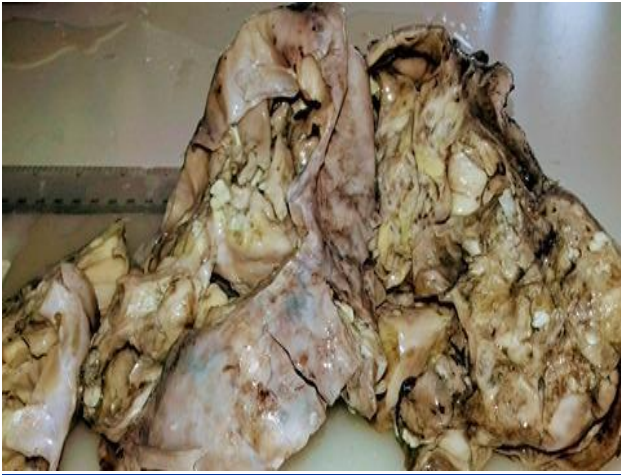

Figure 2: Gross photograph of immature teratoma of ovary-a cystic neoplasm with few focal solid areas.

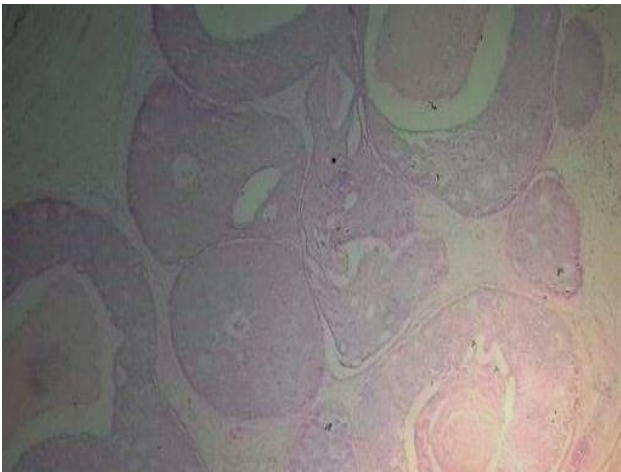


Figure 3: Hematoxylin and eosin stain slide of comedo carcinoma of breast X4x view.

DISCUSSION

Many of the FRS malignancies are known as “silent killers” because women are most of the time unaware of the signs and symptoms associated with these tumors. There are several types of gynecologic tumors which include vulval, vaginal, cervical, gestational trophoblastic disease (GTD), ovarian, endometrial and myometrial. Regular screenings, self-examinations, patient’s awareness of family history and life style changes such as exercise and diet can result in the decline of many types of these malignancies.

The lesions of the female reproductive system constitute a vast majority of the various surgical biopsy specimens received in the pathology department. The patients get operated for both benign and malignant lesions. It is very difficult to diagnose malignancy before surgery. Though clinical history, signs and symptoms, Ultrasonography and fine needle aspiration cytology (FNAC) helps in provisional diagnosis. But histopathological examination

is mandatory for confirmation of diagnosis, correct categorization of tumor and further staging of the tumor.

Benign tumors

Fibroid (leiomyoma) uterus is the most frequently encountered tumor in the genital tract. The common types are intramural, subserosal and submucosal. It has been studied that over 70% of the female by the time of onset of their menopause may present with uterine fibroid.²⁻⁴ The commonest risk factor for development of fibroid is the age of patient. It has been seen that this tumor is ten times more common in women in their fifth and sixth decade of life as compared to those in their third decade.^{5,6}

In our study also, the commonest tumor occurring in the female reproductive tract was leiomyoma comprising of 50% of the total neoplasm. The most common site of occurrence was the uterine body and one was seen in the cervix.

The second common benign tumor seen in our study was fibroadenoma of breast which comprised of 16.66% of the total neoplasm of female reproductive tract and 78.94% of the total neoplasm occurring in breast. Studies done by Haque et al showed (52.88%) and Oluwale et al showed (48.51%) of fibroadenoma out of the total neoplasms in breast.^{7,8} One case was seen as the lactational adenoma of breast. This is also a benign tumor of breast which shows proliferation of tubules with prominent secretory changes in lactating women. Tumors of the ovaries are classified into three major categories surface epithelial tumors, germ cell tumors and sex cord-stromal tumors. This classification is based according to the anatomic structures from which the tumors originate. Each category includes both benign and malignant tumor and many other subtypes.

Mature cystic teratoma (germ cell tumor) was the commonest benign neoplasm of ovary in our study which comprised of 45% of the total neoplasm occurring in ovary. Studies done among Malaysian women also showed that mature cystic teratoma was the commonest benign tumor of ovary.⁹ The second most common tumor was Mucinous Cystadenoma followed by Serous Cystadenoma (surface epithelial tumor) of ovary. Both of the tumors were cystic in nature. On gross examination, serous neoplasm show uniloculated cyst filled with serous fluid and mucinous neoplasms showed multiloculated cysts filled with gelatinous material. Microscopically serous cystadenoma showed cysts lined by single layer of ciliated columnar epithelial cells and mucinous cystadenoma reveal cysts lined by tall columnar epithelial cells with presence of apical mucin. None of these tumors reveal nuclear atypia and any other features suggestive of malignancy.

Western literature states that surface epithelial tumors of ovary comprise 58% of all ovarian neoplasms. But their

incidence is less in the studies done in east.¹⁰⁻¹² Our study showed 50% of surface epithelial tumors out of total ovarian neoplasm.

Malignant tumors

The commonest malignant tumor in our study was squamous cell carcinoma of cervix, comprising of 5.55% of the total neoplasms. Screening programmes for cervical Pap smear examinations in some countries have brought about a marked decline in both the mortality from cervical carcinoma and the incidence of cervical carcinoma. Though the screening awareness has begun in Nepal by various institution and NGOs, but it is not adequately available and is still a big challenge. Human papilloma virus (HPV) type 16 and 18 infections is the major cause of development of cancer cervix. In late 1980, the vaccine against HPV infection was developed.

It is effective in preventing cervical dysplasia and carcinoma. Due to lack of awareness and high cost of vaccine it has become difficult to implement the vaccination programme in countries with low economic resource. This could be the reason that 80% of the cancers occurring in women of developing countries comprise of cervical cancer and it accounts for the fourth common cause of mortality among all cancers.¹³ The two major histologic types of cervical cancer are squamous cell carcinoma and adenocarcinoma. All the cancer in the cervix in our study was squamous cell carcinoma. Among this the most common subtype was large cell non keratinizing.

The second common malignant tumor in our study was infiltrating ductal carcinoma of breast, comprising of 2.22% of the total neoplasm. Infiltrating carcinoma means that the tumor cells have broken the epithelium of glands and ducts and they have spread in the surrounding breast parenchyma. All our patients presented with a breast mass. Malignancies were confirmed radiologically and on cytologic examination. All the patients underwent Modified Radical Mastectomy. Carcinoma of breast generally is symptomless when the tumor size is small. That is why screening is very important for early detection. The American Cancer Society has updated the guidelines for breast cancer screening, in 2015. It states that all women should start annual screening for breast cancer between the ages of 40 and 44. It also states that women who have an average risk for development of breast cancer should undergo regular screening mammography starting at age 45 years.¹⁴

For general public (non-medical professionals) breast cancer is understood as a single disease. However, there are up to 21 different histopathological subtypes and minimum four different molecular subtypes of breast cancer. These subtypes differ in terms of clinical presentation, risk factors, response to chemotherapy and radiotherapy, and patient's survival rate.¹⁵⁻¹⁷

So microscopic subtyping and four main molecular subtyping are now a day is generally done in all newly diagnosed breast cancer. In our study after the diagnosis of breast cancer we referred the patients to higher centre for molecular subtyping and further treatment.

One of our patients also showed histologic subtypes of comedo carcinoma. It is a type of ductal carcinoma in situ which is confined within the ducts and show presence of central necrosis. Extensive gross sampling was done in order not to miss out any foci of invasion. After diagnosis of comedocarcinoma in situ the patient was referred to higher center for immunohistochemistry examination to assess the myoepithelial cells. Invasive carcinoma of breast is characterized by lack of myoepithelial cell marker.

A single case of malignant ovarian neoplasm, immature teratoma was found in our study. Our patient was a young girl 25-year-old. The tumor presented as an enlarged cystic ovary with few foci of solid areas. Microscopic examination showed mature cell components from all the germ cell layers as well as immature neuroepithelial cells. A diagnosis of immature teratoma grade 1 was given and the patient was discharged for further treatment at higher center. We do not find any case of neoplastic lesion of endometrium, vulva, vagina and fallopian tube. This may be due to small sample size.

CONCLUSION

Though in our study the sample size is small, but still the incidence of various neoplasm correlate with other studies of big sample size. Among the various neoplasms leiomyoma was the most common benign tumor and carcinoma cervix was the commonest malignant neoplasm.

To reduce the incidence of carcinoma cervix, regular, effective Pap smear screening programme covering the major population of sexually active women should be organized by the Nepal government and NGOs. Carcinoma of breast was the second common malignant tumor. Similarly, the incidence of carcinoma breast can decline if self-breast examination and regular screening by mammography is done in high risk patients.

ACKNOWLEDGEMENTS

Authors would like to thank all surgeons of department of Gynaecology and Obstetrics and pathologist and technician of department of Pathology Birat Medical College Teaching Hospital, Tankisiniwari, Morang, Nepal for their cooperation in the study.

Funding: No funding sources

Conflict of interest: None declared

Ethical approval: The study was approved by the Institutional Ethics Committee

REFERENCES

1. Stewart BW, Kleihues P (Eds.). *Cancers of the female reproductive tract.* In: *World Cancer Report.* Lyon, France: IARC Press;2003.
2. Boosz AS, Reimer P, Matzko M, Romer T, Muller A. The conservative and interventional treatment of fibroids. *Dtsch Arztebl Int.* 2014;111:877-83.
3. Flake GP, Andersen J, Dixon D. Etiology and pathogenesis of uterine leiomyomas: a review. *Environ Health Perspect.* 2003;111:1037-54.
4. Baird DD, Dunson DB, Hill MC, Cousins D, Schectman JM. High cumulative incidence of uterine leiomyoma in black and white women: ultrasound evidence. *Am J Obstet Gynaecol.* 2003;188:100-7.
5. Baird DD, Dunson DB, Hill MC, Cousins D, Schectman JM. Association of physical activity with development of uterine leiomyoma. *Am J Epidemiol.* 2007;165:157-63.
6. Lurie S, Piper I, Woliovitch I, Glezerman M. Age-related prevalence of sonographically confirmed uterine myomas. *J Obstet Gynaecol.* 2005;25:42-4.
7. Haque R, Tyagi SP, Khan MH, Gahlaut YVS. Breast lesions. A clinicopathological study of 200 cases of breast lumps. *Ind J Surg.* 1980;42:419-25.
8. Oluwole SF, Freeman HP. Analysis of benign breast lesions in blacks. *Ame J Surg.* 1979;137(6):786-9.
9. Thanikasalam K, Ho CM, Adeed N, Shahidan MN, Azizah WK. Links pattern of ovarian tumours among Malaysian women at general hospital, Kuala Lumpur. *Med J Malaysia.* 1992;47:139-46.
10. Scully RE, Clement PB, Young RH. Ovarian surface epithelial stromal tumors. In: Carter D, Greenson JK, Oberman HA, Reuter V, Stoler MH, editors. *Sternberg's Diagnostic Surgical pathology.* 4th ed. Lippincott Williams and Wilkins: Philadelphia; 2004:2543-73.
11. Scully RE, Young RH, Clement PB. Tumors of the Ovary, Maldeveloped Gonads, Fallopian Tube, and Broad Ligament. *Inter J Gynecol Pathol.* 1999;18(3):288.
12. Zaloudek C. tumors of the ovary. In: Fletcher CDM, editor. *Diagnostic histopathology of tumors.* 2nd ed. Churchill Livingstone, Philadelphia;2005:567-641.
13. Schottenfeld D, Fraumeni Jr JF, editors. *Cancer epidemiology and prevention.* Oxford University Press; 2006.
14. Oeffinger KC, Fontham ET, Etzioni R, Herzig A, Michaelson JS, Shih YC, et al. Breast cancer screening for women at average risk: 2015 guideline update from the American Cancer Society. *Jama.* 2015;314(15):1599-614.
15. Dieci MV, Orvieto E, Dominici M, Conte P, Guarneri V. Rare breast cancer subtypes: histological, molecular, and clinical peculiarities. *Oncologist.* 2014;19:805-13.
16. Tamimi RM, Colditz GA, Hazra A, Baer HJ, Hankinson SE, Rosner B, et al. Traditional breast cancer risk factors in relation to molecular subtypes of breast cancer. *Breast Cancer Res Treat.* 2012;131:159-167.
17. Cancer Genome Atlas Network. Comprehensive molecular portraits of human breast tumours. *Nature.* 2012;490(7418):61-70.

Cite this article as: Singh M, Jha KK, Poudyal P, Kafle SU. Histopathological spectrum of neoplastic lesions of female reproductive system-a two-year experience in Eastern Nepal. *Int J Res Med Sci* 2018;6:426-30.