

Case Report

A high risk unstable case of left main bifurcation lesion treated with simultaneous kissing stents as salvage procedure

Brajesh Kumar Kunwar^{1*}, Vikrant Pawar², Ravneet Singh Villkhoo², Shivram Mishra¹

¹Department of Cardiology, ²Department of Intensive Care, Fortis Hospital, Navi Mumbai, Maharashtra, India

Received: 28 November 2019

Revised: 24 December 2019

Accepted: 30 December 2019

*Correspondence:

Dr. Brajesh Kumar Kunwar,
E-mail: Kunwar_brajesh@yahoo.com

Copyright: © the author(s), publisher and licensee Medip Academy. This is an open-access article distributed under the terms of the Creative Commons Attribution Non-Commercial License, which permits unrestricted non-commercial use, distribution, and reproduction in any medium, provided the original work is properly cited.

ABSTRACT

Bifurcation treatment with percutaneous coronary intervention is still one challenging task especially the left main bifurcation. And it becomes still more challenging when it is done in emergency situation in a very unstable patients. There are many one-stent and two-stent approaches available to treat the bifurcation lesions but no approach has proven superior to other. Here, we present a case of a 78-year-old male diagnosed with distal left main bifurcation lesion treated with simultaneous kissing stents technique presented with acute coronary syndrome, non-ST elevation myocardial infarction with pulmonary oedema in cardiogenic shock.

Keywords: Bifurcation, Left main, Simultaneous kissing stents

INTRODUCTION

Turbulent blood flow may develop high shear stress at the bifurcation which eventually accumulates atherosclerotic plaque. Percutaneous coronary intervention of bifurcation lesions require technical expertise and have also reported poor clinical outcomes¹. Importantly, it becomes more challenging in a condition when bifurcation PCI is attempted in emergency high risk unstable patient unfit for coronary artery bypass surgery as a salvage procedure. Several one stent/two stent techniques like crush, culotte, V-stenting, Y-stenting, simultaneous kissing stenting, T-stenting, and modified T-stenting techniques are available to treat bifurcation lesions. No particular two stent technique has proven superior to another¹. Here, we present a case of a 78 year old male diagnosed with Non-ST elevation myocardial infarction with pulmonary oedema with severe LV systolic dysfunction in cardiogenic shock having significant stenosis in all major epicardial vessels: bifurcation lesion involving proximal left anterior

descending artery and proximal left circumflex artery treated with simultaneous kissing stents technique and long diffuse lesion in proximal to mid right coronary artery.

CASE REPORT

A 78 years-old male presented to our emergency department with complaints of breathlessness and chest pain. He had an episode of abdominal distention and 3-4 episodes of vomiting. He was found to be in cardiogenic shock. He was a known case of diabetes mellitus and hypertension. He had Non-ST elevation myocardial infarction and his echocardiogram showed severe LV systolic dysfunction. He was immediately taken up for coronary angiography. His angiogram revealed triple vessel disease. Long diffuse lesions were observed in ostial to mid left anterior descending artery (LAD) and ostial to mid left circumflex (LCx) artery (Figure 1A). Proximal to mid right coronary artery (RCA) was also diseased with diffused lesion (Figure 1B). He was

advised for percutaneous coronary intervention (PCI) as he was not fit for high risk CABG surgery in view of comorbidities associated.

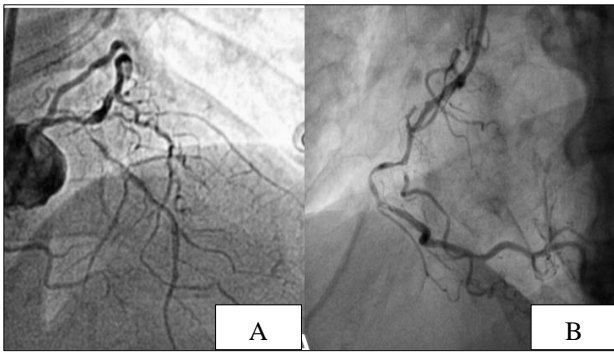


Figure 1: (A) From ostial to mid long and diffuse lesions in left anterior descending (LAD) artery and left circumflex (LCx) (B) long diffuse lesion in proximal to mid right coronary artery (RCA).

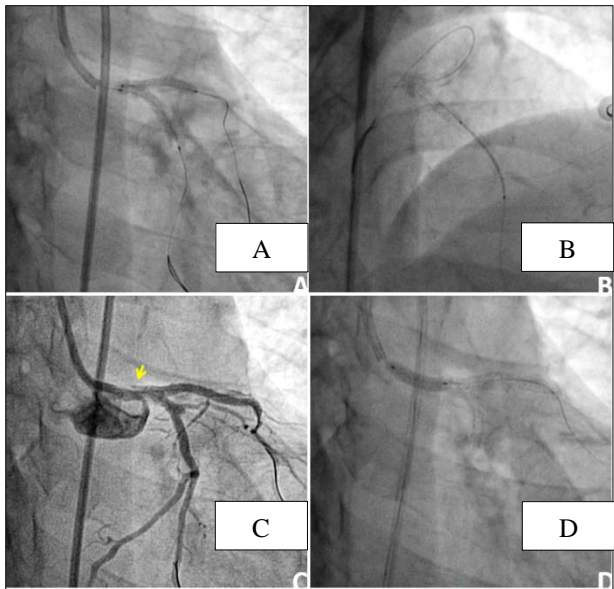


Figure 2: (A) LAD and LCx bifurcation lesion treated with simultaneous kissing stents (B) another stent deployed in mid LAD overlapping the previous stent (C) post stenting dissection flap was observed (yellow arrow) (D) bailout stenting was performed to cover the dissection flap.

Seven thousand unit of heparin was administered and PCI was initiated via femoral route. The LAD and LCx were crossed with two different Fielder FC 0.014” guidewires. The LAD lesion was pre-dilated with 1.5 x 12 mm Minitrek, 2.5 x 12 mm Traveler and 2.75 x 12 mm NC Cosmos balloons at 12 atm. The LCx lesion was pre-dilated with 2.75 x 12 mm NC Traveler balloon at 12 atm. Considering location of stenosis in LAD and LCx and unstable patient with falling BP with pulmonary oedema, it was decided to use simultaneous kissing technique (SKS).

The stents were negotiated in left main-LAD (LM-LAD) and LM-LCx and stented with 2.5 x 20 mm and 2.75 x 24 mm DES (Tetralimus, Sahajanand Medical Technologies, Surat, India), respectively at 14 atm (Figure 2A). Post dilatation was done with final kissing keeping NC balloon 2,75x12mm in LAD and 3x12mm NC balloon in LCX. A second DES was negotiated in the mid LAD overlapping the first stent and deployed there (Figure 2B). A dissection was observed at proximal LM after stenting (Figure 2C). Bailout stenting was done with 4.0 x 12 mm DES at 14 atm to cover the dissection flap (Figure 2D).

The RCA was crossed using Fielder FC 0.014” guidewire and lesion was pre-dilated with 2.0 x 12 mm Mini Trek balloon at 10 atm. A 2.25 x 24 mm DES was negotiated and stented in mid RCA at 12 atm (Figure 3A) followed by another 2.5 x 32 mm DES in proximal RCA at 12 atm (Figure 3B).

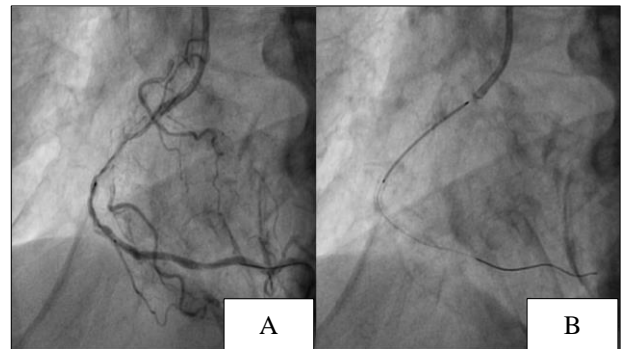


Figure 3: Mid RCA (A) and proximal RCA (B) stented with drug eluting stents.

Post-dilatation was done with 2.5 x 12 mm Traveler balloon at 16 atm. The final angiogram showed TIMI III flow in all treated vessels (Figure 4A and B). Post-procedure, foley catheter was removed and patient developed hematuria. Hence, irrigation of bladder was done. The patient was discharged after he was hemodynamically stable and his condition became normal. Patients is living normal life at 6-month follow-up.

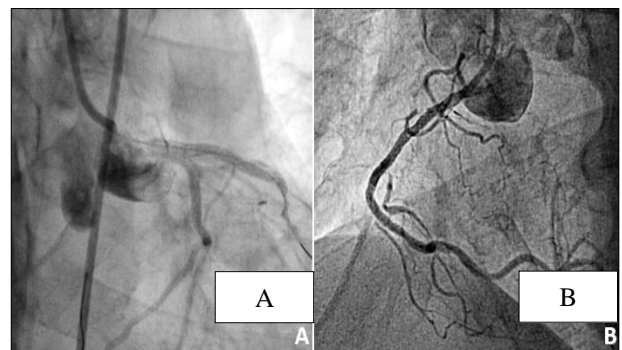


Figure 4: Final TIMI III flow in (A) LAD and LCx (B) RCA.

DISCUSSION

Simultaneous kissing stents (SKS) technique is the modified version of V-stenting technique, where delivery and implantation of two stents is done together keeping a two barrel metallic carina in the left main. The main advantage of SKS technique is that it assures vessel patency in both the branches, final kissing balloon is done simultaneously without requirement of rewiring. This technique becomes especially important in emergency situation in unstable patient where accidentally occlusion of side branch is expected to be very poorly tolerated. The SKS technique was reported first in 1993 by Colombo et al, since the introduction of the SKS technique, the major concerns are two barrel metallic carina which may act as a stimulus for stent thrombosis. Optical coherence tomography study in two patients who underwent treatment for bifurcation lesion by SKS technique reported that the struts in the metal carina were completely covered with the tissues and no uncovered or incomplete struts apposition was observed.² The authors in another study reported that after 4-months of implantation with SKS technique, the metallic carina was completely endothelialized.³ Another major concern with SKS technique is that it is difficult to place a stent proximal to metallic carina. In our case, a dissection was observed proximal to the metallic carina. This dissection flap was covered by placing a stent proximal to the metallic carina without much difficulty. Our patient had narrow angle of bifurcation, large diameter of LCx (>2.5 mm) and concomitant diffused lesion in LCx. Such anatomy favours implantation of SKS.⁴ The patient also was unstable high risk requiring quick procedure time and simultaneously avoiding risk of side branch occlusion. An all comer study done on 150 consecutive patients with distal left main bifurcation lesion treated with SKS technique reported that at one-year follow-up target lesion revascularisation rate was 4.3% and at two-year follow-up 6.2%. The study reported that the SKS technique was simple, safe and effective in patients with left main bifurcation treatment. In the present case, the patient was event-free at 6-month follow-up.

CONCLUSION

SKS technique for bifurcation stenting is a very safe and effective procedure in tackling high risk and unstable

patients presented with difficult disease involving left main and LAD and LCX vessels. The roomy Left main easily accepts two simultaneous stents without risk of side branch occlusion. This technique does not require recrossing of wire through the struts of stents. The short procedure time also makes it favorable in unstable patients. If properly done with the help of imaging can have long term good patency rate with almost similar rates of in-stent stenosis as other techniques.

Funding: No funding sources

Conflict of interest: None declared

Ethical approval: Not required

REFERENCES

1. Siotia A, Morton AC, Malkin CJ, Raina T, Gunn J. Simultaneous kissing drug-eluting stents to treat unprotected left main stem bifurcation disease: medium term outcome in 150 consecutive patients. *EuroInterven.* 2012 Oct 1;8(6):691-700.
2. Yamada T, Takahashi A. Membranous diaphragm formation after simultaneous kissing stenting with sirolimus-eluting stents for the left main bifurcation: Insight from optical coherence tomography findings. *Catheteriza Cardiovas Interven.* 2013;82(3):E221-E4.
3. Morris PD, Iqbal J, Chiastra C, Wu W, Migliavacca F, Gunn JP. Simultaneous kissing stents to treat unprotected left main stem coronary artery bifurcation disease; stent expansion, vessel injury, hemodynamics, tissue healing, restenosis, and repeat revascularization. *Catheteriza Cardiovas Interven.* 2018 Nov 15;92(6):E381-92.
4. Ahn JM, Lee PH, Park SJ. Practical based approach to left main bifurcation stenting. *BMC Cardiovas Disorders.* 2016;16(1):49.

Cite this article as: Kunwar BK, Pawar V, Villkhoo RS, Mishra S. A high risk unstable case of left main bifurcation lesion treated with simultaneous kissing stents as salvage procedure. *Int J Res Med Sci* 2020;8:764-6.