

## Case Report

# Laparoscopic cholecystectomy in a patient with situs inversus totalis: a case report

Chaithanya Babu Bogarapu\*, Rathna Kishore Bujjitha Savalam,  
Jayaraj Chinthagada, Satish Chaitanya Kattupalli

Department of Surgery, Andhra Medical College & King George Hospital, Visakhapatnam, Andhra Pradesh, India

**Received:** 29 January 2015

**Accepted:** 8 February 2015

**\*Correspondence:**

Dr. Chaithanya Babu Bogarapu,  
E-mail: drbchaitanya@gmail.com

**Copyright:** © the author(s), publisher and licensee Medip Academy. This is an open-access article distributed under the terms of the Creative Commons Attribution Non-Commercial License, which permits unrestricted non-commercial use, distribution, and reproduction in any medium, provided the original work is properly cited.

### ABSTRACT

Situs inversus totalis is a rare congenital condition present in approximately 0.01% of the population in which the major visceral organs are reversed from their normal position and can pose difficulties in the diagnosis and management of acute abdominal pathology. Symptomatic cholelithiasis is very common in India and laparoscopic cholecystectomy is the gold standard treatment at present. Laparoscopic surgery in a situation of situs inversus is challenging due to the mirror-image anatomy. Diagnostic pitfalls and technical details of the laparoscopic cholecystectomy are discussed.

**Keywords:** Laparoscopic cholecystectomy in situs inversus totalis, Situs inversus totalis, Laparoscopic cholecystectomy

### INTRODUCTION

Situs inversus totalis also called situs transverses or oppositus is a rare autosomal recessive genetic condition in which the major visceral organs are reversed from their normal position. Situs inversus viscerum has been observed in animals since the time of Aristotle.<sup>1</sup> The first known human case of dextrocardia has been reported by Fabricius in 1600.<sup>2</sup> More than a century later Matthew Ballie described the complete mirror-image reversal of the thoracic and abdominal organs in situs inversus. Situs inversus is present in approximately 1 in 5000 to 20000 live births and it accounts for 0.01% of the population.<sup>3</sup>

The normal development requires a 270 degree counter clockwise rotation yielding to normal anatomy but in situs inversus totalis the 270 degree rotation is in the clockwise direction.<sup>4</sup> The heart is located on the right side of the thorax, the stomach and spleen on the right side of the abdomen and the liver, gall bladder on left side. The

left lung is trilobed and right lung is bilobed. The transposition of the organs maybe associated with other congenital anomalies, such as renal dysplasia, biliary atresia, congenital heart disease, or pancreatic fibrosis. Situs inversus totalis associated with bronchitis, chronic sinusitis, and deficient tracheobronchial cilia is known as the Kartagener's syndrome.<sup>2,5</sup>

There is no evidence to suggest that cholelithiasis occur in greater frequency in situs inversus population.

Since the introduction of the technique of laparoscopic cholecystectomy in 1987, the first known report on laparoscopic cholecystectomy in a patient with situs inversus totalis is in 1991 by Campos and Sipes.<sup>5</sup> The laparoscopic treatment may have technical difficulties and need for modifications in operative technique because of the mirror-image anatomy.

Here we report a rare case of situs inversus totalis who presented with severe upper abdominal pain, vomiting, fever and an eventual diagnosis of gallstone disease. While maintaining the basic operative techniques in dissection of Calot's triangle but in mirror image, laparoscopic cholecystectomy was performed safely.

## CASE REPORT

A 58 year old male presented with 2 days history of left upper quadrant pain, vomiting and fever. The pain was intermittent, colicky in nature radiating to left scapular region and aggravated by fatty meals. He was afebrile and physical examination revealed positive murphy's sign in the left hypochondrium. Ultrasound abdomen showed location of liver and gallbladder on left side of the body and spleen to the right side of the body with 11×7cm calculus in the gall bladder without wall thickening or pericholecystic fluid. No biliary duct dilatation appreciated.

Chest X ray showed dextrocardia consistent with situs inversus (Figure 1).

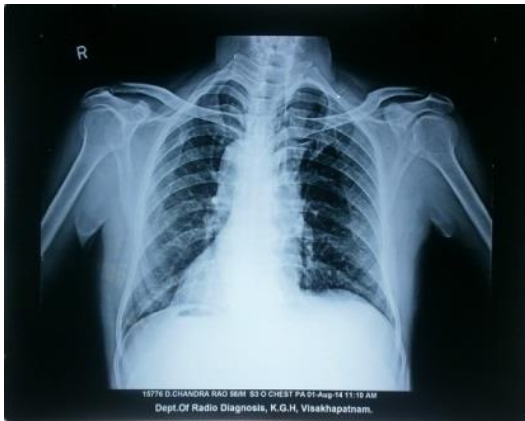

Figure 1: Chest X-ray showing dextrocardia.

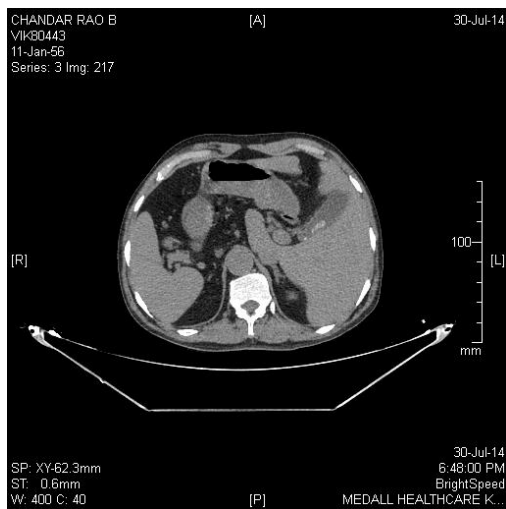


Figure 2: CT showing complete transposition of major abdominal and thoracic organs.

An computed tomography scan shows the complete transposition of major abdominal and thoracic organs with a calculus in left sided gallbladder and no evidence of intrahepatic or common bile duct dilatation (Figure 2).

With the diagnosis of symptomatic cholelithiasis, elective laparoscopic cholecystectomy was performed.

## Technique

The approach in the operating room required modification with the surgeon and the 1st assistant (camera surgeon) positioned on the right side of the patient and the 2<sup>nd</sup> assistant, scrub nurse on the left side. A head-end-up and left-side-up positioning of the patient was adopted to optimize views of the gall bladder and the Calot's triangle. The monitor was placed at the head-end of the patient on left side. A 10 mm 300 laparoscope was introduced through transverse sub umbilical incision. Another 10 mm port was placed in the sub-xiphoid region just left to the midline. The other two 5 mm ports were placed in the left mid-clavicular and left mid-axillary lines about 5 cm apart (Figure 3).

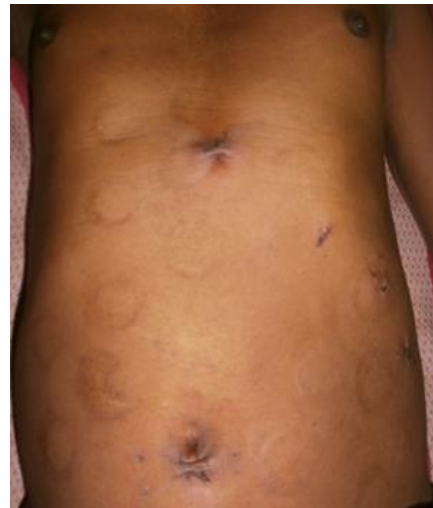

Figure 3: Post-operative picture of patient's abdomen showing sutured port sites.

The right handed surgeon standing on the right side of the patient feels comfortable to use the medial (sub-xiphoid) port to retract the infundibulum with left hand and operate with the right hand through the lateral (mid-clavicular) port. A toothed grasper was inserted through the lateral most mid-axillary port to retract the fundus of the gall bladder laterally and cephaloid. Dissection of the Callot's triangle and demonstrating the critical view of safety before clipping and resection of gall bladder proceeded as usual. Cystic duct and cystic artery were separately clipped and divided through the sub-xiphoid port. It was again found to be difficult to apply clips as the angle of the clip applicator did not fit along the direction of the cystic artery. The gall bladder was dissected out from the gall bladder fossa using the hook

diathermy through the sub-xipoid port with the 2<sup>nd</sup> assistant maintaining traction on the gall bladder. Finally gall bladder was extracted out through the sub-xiphoid port. The total duration of the operation was found to be 55 min. The post-operative period was uneventful and patient was discharged on 3<sup>rd</sup> post-operative day.

## DISCUSSION

Situs inversus totalis is an extremely rare condition and performing successful laparoscopic cholecystectomy in these patients is even rarer. There are several important aspects in the management of gallstones in patients with situs inversus that are worth highlighting. In our case, both the surgeon and 1st assistant were right-handed and therefore the technique has to be adjusted. It would be much easier for a left-handed surgeon to perform laparoscopic cholecystectomy in such patients.<sup>1,6</sup> Patients with situs inversus who are scheduled for laparoscopic cholecystectomy should be assessed pre-operatively for any associated potentially serious cardiac or respiratory abnormalities. As the mirror-imaged orientation while operating on a left sided gall bladder requires mental adaptability and manual dexterity to cope with any evolving difficulties or potentially dangerous intra-operative situations, laparoscopic cholecystectomy in patients with situs inversus should be performed by an experienced laparoscopic surgeon.<sup>7</sup>

Laparoscopic cholecystectomy is a technically difficult procedure in patients of situs inversus but not a contraindication.<sup>8</sup> It is the adaptation of the position of the surgeon, the assistants, and ports for the dissection that are important.

*Funding: No funding sources*

*Conflict of interest: None declared*

*Ethical approval: Not required*

## REFERENCES

1. Drover JW, Nguyen KT, Pace RF. Laparoscopic cholecystectomy in a patient with situs inversus viscerum: a case report. *Can J Surg.* 1992;35(1):65-6.
2. Nursal TZ, Baykal A, Iret D, Aran O. Laparoscopic cholecystectomy in a patient with situs inversus totalis. *J Laparoendosc Adv Surg Tech A.* 2001;11(4):239-41.
3. Moreli SH, Young L, Reid B, Ruttenberg H, Bamshad MJ. Clinical analysis of families with heart, midline and laterality defects. *Am J Med Genet.* 2001;101:388-92.
4. Song JY, Rana N, Rottman CA. Laparoscopic appendectomy in a female patient with situs inversus: case report and literature review. *JSLS.* 2004;8:175-7.
5. Campos L, Sipes E. Laparoscopic cholecystectomy in a 39-year-old female with situs inversus. *J Laparoendosc Surg.* 1991;1:123-6.
6. Oms LM, Badia JM. Laparoscopy cholecystectomy in situs inversus totalis: the importance of being left-handed. *Surg Endosc.* 2003;17:1859-61.
7. Senthil Kumar, Giuseppe Fusai. Laparoscopic cholecystectomy in situs inversus totalis with left-sided gall bladder. *Ann R Coll Surg Engl.* 2007;89(2):W16-8.
8. Banerjee JS, Vyas FL, Jesudason MR, Govil S, Muthusami JC. Laparoscopic cholecystectomy in patient with situs inversus. *Indian J Gastroenterol.* 2004;23:79-80.

DOI: 10.5455/2320-6012.ijrms20150357

**Cite this article as:** Bogarapu CB, Savalam RKB, Chinthagada J, Kattupalli SC. Laparoscopic cholecystectomy in a patient with situs inversus totalis: a case report. *Int J Res Med Sci* 2015;3:805-7.