

Original Research Article

Near total laryngectomy: a single institutional experience

Manas P. Das*, Mridul K. Sarma, Mrinmoy M. Choudhury, Ajit K. Missong

Department of Head and Neck Oncology, State Cancer Institute, GMCH, Guwahati, Assam, India

Received: 21 October 2021

Revised: 06 November 2021

Accepted: 08 November 2021

*Correspondence:

Dr. Manas P. Das,

E-mail: manaspratimdas20@gmail.com

Copyright: © the author(s), publisher and licensee Medip Academy. This is an open-access article distributed under the terms of the Creative Commons Attribution Non-Commercial License, which permits unrestricted non-commercial use, distribution, and reproduction in any medium, provided the original work is properly cited.

ABSTRACT

Background: Near total laryngectomy (NTL) aims to remove cancer of larynx and hypopharynx while maintaining a lung powered, prosthesis free voice. The oncological and functional outcomes of NTL have been encouraging but the surgical procedure is complex. In this study, we present our experience with NTL in order to encourage more ENT and head and neck surgeons to take up the procedure.

Methods: Twenty-eight patients, who had undergone NTL at State cancer institute, Guwahati are analysed retrospectively for survival, disease free status, functional outcomes and complications.

Results: There were two recurrences: one local recurrence which was salvaged by a completion total laryngectomy. The other patient had distant metastasis and died eventually. Overall survival (OS) was 96.43% and event free survival (EFS) was 92.86%. The patient who died had extra-nodal extension (ENE) on post op histology ($p=0.274$). Two patients failed to develop any speech had stenosis of the shunt. One of these was the only Salvage NTL case ($p=0.057$). Tracheostome stenosis, poor swallow and shunt stenosis were the common complications in our series. Most of them resolved with some intervention. Multiple complications were seen in the salvage NTL cases.

Conclusions: Careful case selection and well executed surgery leads to acceptable results following NTL. Special attention should be paid to the salvage cases as they are prone to develop complications and failure to attain speech. Patients with adverse post-op histopathological examination (HPE), like ENE should be kept under close follow up.

Keywords: Cancer larynx, Cancer hypopharynx, Complications in, NTL, Voice in

INTRODUCTION

Cancer of the larynx is a common head and neck cancer affecting 14.33 cases annually per 100,000 globally.¹ The global age standardised incidence of hypopharyngeal cancer is 0.8 per 100,000 population.² This figure for hypopharyngeal cancer goes much higher for countries of south-central Asian region including India.² Treatment is mostly directed at cure with an aim to preserve function.³ Recommended surgery in advanced laryngeal and hypopharyngeal cancer is total laryngectomy.^{3,4} However in a subset of these patients, who are candidates for total laryngectomy, preservation of voice is possible by a modification, called near total laryngectomy (NTL).

In NTL, a vertical strip of tissue opposite to the diseased side is preserved to maintain continuity between the

trachea and the newly constructed pharynx. This shunt contains a functioning Crico-arytenoid unit comprising of a mobile crico-arytenoid joint, the vocalis muscle and an intact recurrent laryngeal nerve.^{5,6} This, acts like a 1-way valve allowing air from lung to enter pharynx and enable voice production but preventing aspiration of food.⁷

The main idea of an NTL is to enable speech in patients without needing voice prosthesis.⁶ A permanent tracheostomy however remains necessary.

History

NTL was described by Pearson et al in the early 1980s and therefore also called the 'Pearson procedure'.⁷⁻⁹ Initially, the terms extended hemi-laryngectomy and subtotal laryngectomy were used to describe it. As the

term 'near total' was more descriptive for the procedure, it gained much popularity and acceptance. For resection of disease of the pyriform sinus (PFS), they used the term near total laryngopharyngectomy.³

Aim of the study

This study aims to evaluate the outcome in terms of disease clearance, voice quality, operative complications and survival in patients undergoing NTL.

Primary outcome

Locoregional recurrence and distant metastasis were the primary outcome

Secondary outcome

Presence and quality of voice post operatively and operative complications were the secondary outcome.

METHODS

This is a retrospective analysis of all patients who have undergone an NTL surgery at the department of head and neck oncology, State Cancer Institute, Gauhati Medical College, Assam from June 2017 up to December 2020. The study has been approved by the institutional ethical committee. Medical records of all 19 patients have been used in this study. Patients were staged according to AJCC 8th edition. Primary treatment modality, type of surgery, extent, use of any reconstruction and the type of neck dissection performed; along with any post op event and time to discharge are recorded. Patients were asked to follow up after 10 days of discharge for stitch removal along with the HPE reports. Subsequent follow up was done at 2 monthly intervals for the first year, 3 monthly for 2nd and 3rd year and 6 monthly thereafter. Time to first appearance of voice, its quality and persistence was noted. Voice quality was subjectively evaluated by the operating surgeon. Any complications that arose were noted down. Locoregional recurrence and distant metastasis was looked for in patients who completed treatment for at least 3 months. Statistical analysis is done using IBM-SPSS software, Microsoft excel and word.

Patient selection

All patients with advanced (T3 and T4) laryngeal and hypopharyngeal/ PFS cancers, including post irradiated cases who were amendable to surgical salvage were selected for NTL provided the following criteria:

Inclusion criteria

Lateralised cancers of the larynx and PFS, not involving the post cricoid and inter arytenoid region and disease free and functional crico-arytenoid (CA) joint and posterior part of the true vocal cord on the contralateral side were included in the study.

Exclusion criteria

Disease involving the post cricoid region (PCR), inter-arytenoid (IA) region or involvement of the contralateral side. Non-functional contralateral CA unit with fixed/paralysed contralateral vocal cord. Poor pulmonary reserve. Post radiotherapy edema and fibrosis of the larynx and hypopharynx were excluded from the study.

Surgical procedure

NTL is done by only one primary operating surgeon in our institution and the following is an account of the procedure done here.

The patient is positioned on the operation theatre (OT) table in a supine position. Preliminary tracheostomy is done and general anaesthesia (GA) induced. Slight extension of the head is maintained. Gluck- Sorenson incision is made with a 15-size surgical knife and subplatysmal flaps elevated both superiorly and inferiorly. Neck dissection is then commenced on both sides. The extent of neck dissection is guided by the N stage. After completion of the neck dissection, the diseased side of the larynx is first operated on. This part is quite similar to a total laryngectomy. The strap muscles are divided both inferiorly from the sternum and superiorly from the hyoid on the diseased side. Paracarotid tunnel is dissected, superior thyroid vessels and recurrent laryngeal nerve are divided. Parathyroids are preserved only if free from disease and the thyroid lobe on the diseased side is left intact over the specimen. On the contralateral side, a strip of laryngeal tissue is preserved consisting of the greater cornua of the hyoid bone with attached strap muscles, a thin vertical portion of the thyroid cartilage, a part of the cricoid (approximately 1/4th circumference), the crico-arytenoid joint and the vocal cord with the vocalis muscle. Paracarotid region is not dissected on this side. Usually, a hemithyroidectomy is done and on this side, the thyroid lobe is preserved along with its blood supply and attached parathyroids. Recurrent laryngeal nerve is visualised and care is taken not to injure it. Subglottic mucosa is stripped off the cricoids on the diseased side and preserved along with the strip of cricoid on the uninvolved side. The entry to the pharynx however is not made in a trans-ventricular fashion as per Pearson's technique.⁵ A trans-vallecular technique is used instead. A margin of at least 5 mm is kept on endo-laryngeal side while in the hypopharynx, 15mm is considered safe. The specimen is delivered after making the inferior cut. Crico- pharyngeal myotomy is done in all the cases. A shunt is fashioned around a 14F size foley's catheter using the vocalis muscle and the remnant mucosa of the subglottic. Pharyngeal closure is done next using interrupted 3-0 vicryl sutures over a 14F Ryle's feeding tube. Vacuum neck drains are put bilaterally and skin closure is done. A permanent tracheostomy is made. The distal end of foley's catheter is kept out through the tracheostome.

The foley's catheter is kept overnight for the shunt to fashion. Neck drains are removed 72-96 hours post operatively. Ryle's tube feeding initiated within 24 hours and patient is discharged once all drains and IV lines are removed, patient is clinically stable and taking oral feeding comfortably.

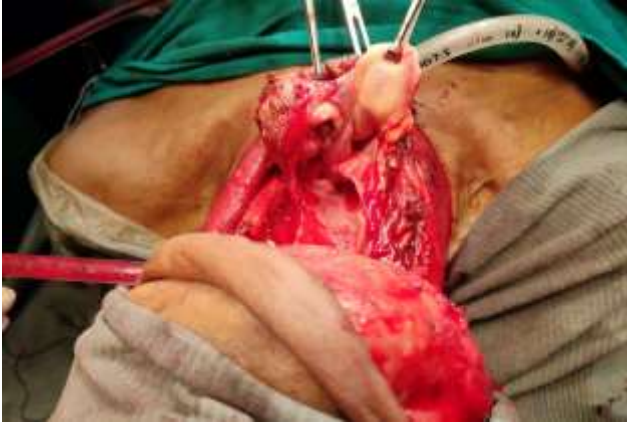

Figure 1: Cut through the supra-glottis on the uninvolved (Right) side extending from the epiglottis up to the anterior commissure. The picture shows involvement of the left PFS by tumour.

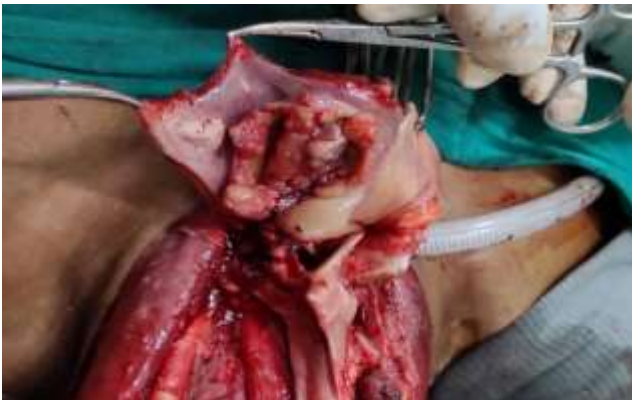

Figure 2: Further rotation reveals the cut on the cricoid and the inter-arytenoid region.

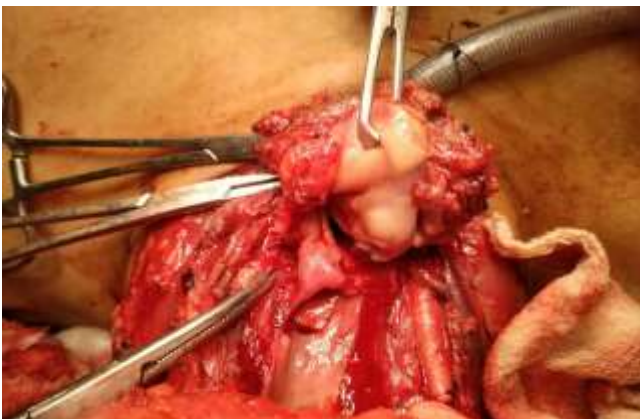

Figure 3: Disease involving the right AEF region. laryngeal cut through the left supra-glottis is seen.

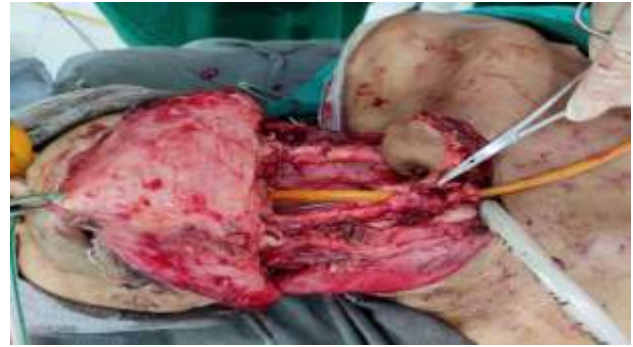

Figure 4: Voice conduit is fashioned around the foley's catheter while the neopharynx will be closed around the nasogastric tube. Patch PMMC flap is used to reconstruct the neopharynx.

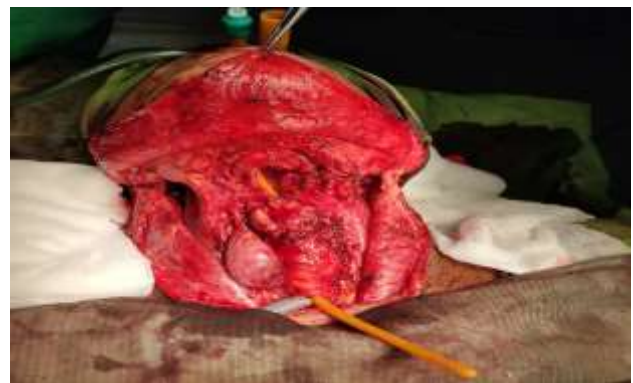

Figure 5: Fully developed voice conduit.

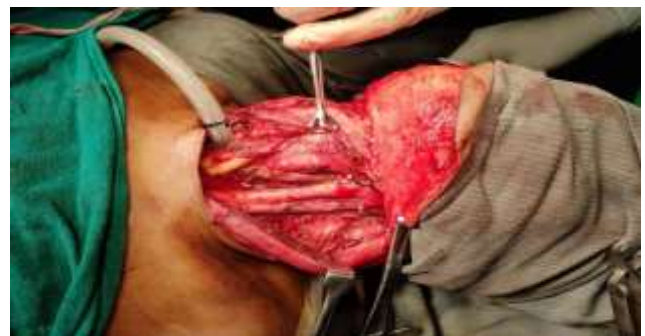

Figure 6: Neck dissection completed before proceeding to NTL.

RESULTS

Twenty eight patients have undergone NTL operation at our institution from 2017 till date. Following is an account of the results in terms of epidemiology, complications and outcomes in terms of voice and oncological safety.

Epidemiology

A total of 28 patients are included in the study with age ranging from 37-70 years (mean age=54.25 years) (Table 1).

Table 1: Age and sex.

Age (years)	Male	Female	Total
31-40	3	1	4
41-50	2	2	4
51-60	7	4	11
61-70	6	3	9
Total	18	10	28

All the patients who underwent NTL had squamous cell carcinoma (SCC) involving the larynx or hypopharynx pre operatively (Table 2). All cases were treated with upfront surgery except two cases (rT2N2b right PFS and rT3N0 right PFS) which had recurrence following radical chemoradiation (CRT) and were treated by salvage NTL. Bilateral neck dissection (ND) was done in all cases. N+ cases had at least a modified radical ND (MRND) done on the involved side; rest had a selective ND (SND) to levels 2, 3 and 4 bilaterally. Mean ICU stay and mean post op hospital stays 1.29 and 8.57 days respectively.

Table 2: Clinical T and N stage.

Variables	N0	N1	N2	N3	Total
T2	0	0	1	0	1
T3	1	1	0	0	3
T4a	12	6	5	1	24
Total	13	7	6	2	28

Post-op HPE

Post operative histology revealed SCC in all cases (Table 3). Four cases had close margin. Seven cases had Extranodal Extension. These patients with 1 or another adverse feature received concurrent chemotherapy with adjuvant radiotherapy.

Table 3: Post-op HPE.

Variables	Numbers
WDSCC	9
MDSCC	16
PDSCC	3

One case with ENE later developed pulmonary and hepatic metastases and died eventually (Table 4). Rest of the cases with adverse HPE features did not develop any locoregional or distant recurrence (Table 5).

Table 4: Post-op HPE and survival.

Status	Adverse post-op HPE			Total	
	Absent	ENE	Close margin		
Alive	Count	16	7	4	27
	%	100	87.5	100	96.43
Dead	Count	0	1	0	1
	%	0	12.5	0	4.57
Total	Count	16	8	4	28
	%	100	100	100	100

Chi-square=2.5926, p=0.274

Table 5: Post-op HPE and recurrence.

Recurrence status	Adverse post-po HPE			Total	
	Ab	ENE	Close margin		
Non-recurrence	Count	15	7	4	26
	%	93.7	87.5	100	92.86
Recurrence	Count	1	1	0	2
	%	6.25	12.5	0	7.14
Total	Count	16	8	4	28
	%	100	100	100	100

Chi-square=0.6731, p=0.714, Ab-absent

Complications

Fifteen patients in our series had one or a combination of different complications. The most common complications seen were stenosis of tracheostome (6 cases) and poor swallow (4 cases) (Table 6).

Table 6: Complications and outcome.

Complication	No. of cases	Outcome/ intervention
Shunt stenosis	3	2 did not develop voice
Stenosis of tracheostomy	6	Corrected by surgical widening
Chyle leak	1	Repaired surgically PO-day 20
Aspiration	3	Aspiration resolved without any surgical intervention
Pharyngo-cutaneous fistula	4	One developed in the salvage NTL case. All were admitted, IV antibiotics, NPO, RT feed, ASD. Resolved in 10 days
Poor swallow	5	1 stricture, 0 recurrences. Dilatation successful in 4 cases

The cases of shunt stenosis were evaluated endoscopically which showed no recurrence. One patient developed speech after dilatation while the rest failed to develop any speech. There was stenosis of shunt in one case of salvage NTL who eventually did not develop voice.

There were four cases of pharyngocutaneous fistula (PCF) in our series, one of which occurred in a salvage NTL patient. In all cases, PCF developed after the patients were discharged. All the cases were managed by admitting them and administering IV antibiotics, nasogastric tube feeding, and aseptic dressing. PCF resolved within 10 days in each case.

Complications were more common in the salvage surgery group (100%) than the upfront surgery group (50%) (p=0.167); complication rates were similar in N0

(52.94%) and N+(54.55%) cases. Type of neck dissection also did not influence complication rates.

Speech

Most of the patients after NTL developed some intelligible speech. Twenty-five patients developed speech and all retained it permanently. Three patients failed to develop speech, two of them had shunt stenosis (Table 7).

Table 7: Speech development.

Voice	Yes	No
Developed	25	3
Total with speech	25	

The mean time to develop speech was 45.41 days.

The quality of speech was graded as excellent, fair and poor by the primary surgeon as follows (Table 8).

Table 8: Quality of voice developed.

Excellent	Full sentence	15
Fair	Short sentence with effort	8
Poor	Breathy whisper with considerable effort	2

Twenty-five patients (92.31%) from the upfront surgery group developed voice subsequently. It is seen that one patient who underwent salvage surgery did not have any voice post operatively. This was nearly statistically significant (p=0.057) on analysis (Table 9).

Table 9: Voice in upfront vs salvage NTL.

Voice		Up front surgery	Salvage surgery	Total
Absent	Count	2	1	3
	(%)	7.69	50	10.72
Present	Count	24	1	25
	%	92.31	50	89.28
Total	Count	26	2	28
	%	100	100	100

Chi-square=3.4749, p=0.057

All upfront surgery cases underwent adjuvant therapy in the form of RT or CRT. Post operative RT did not seem to adversely affect the presence of voice. The only patient in this group who did not develop voice received post op CRT.

Disease control

All the patients treated with upfront surgery completed prescribed adjuvant therapy. The salvage NTL cases were not advised any adjuvant therapy. Patients were followed up every 2 months in the initial year, 3 monthly in the 2nd and 3rd year and 6monthly in 4th year and annually

thereafter. Symptomatic cases were further evaluated with a CT scan of the Head and neck region and upper GI endoscopy.

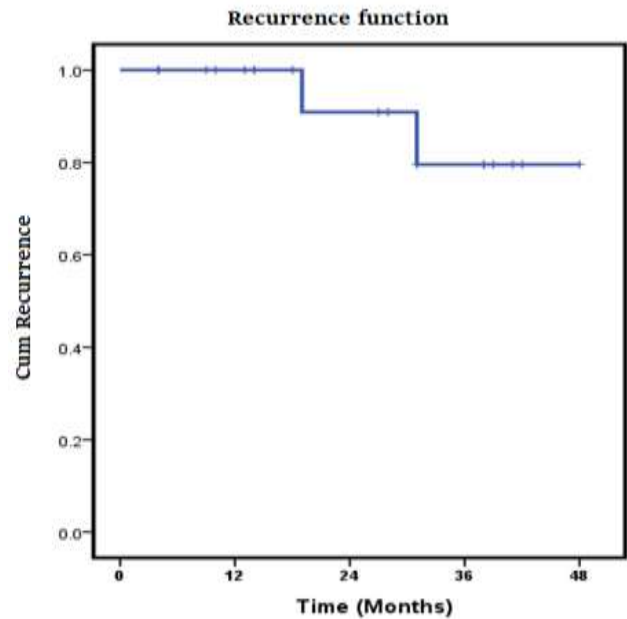


Figure 7: Recurrence.

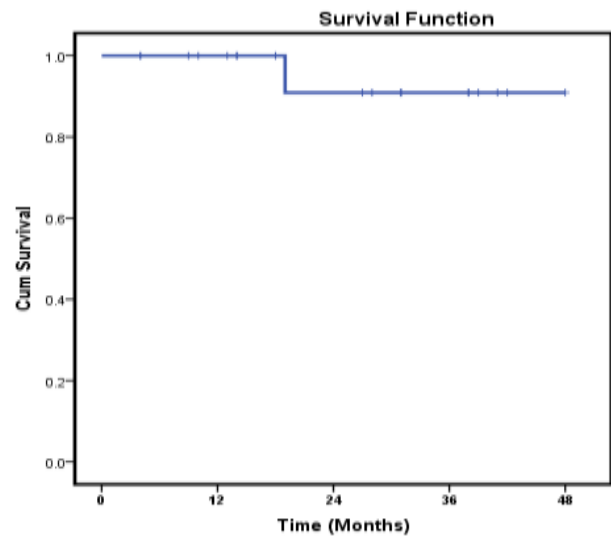


Figure 8: Overall survival.

There were 2 cases of recurrence in our series, both of which occurred in the primary surgery group (p=0.682) (Figure 7). One local recurrence was in the neopharynx and the other was a distant metastasis. Recurrence was higher in those who received adjuvant CRT (9.09% vs 6.67% in adjuvant RT group, p=0.818) and when ENE was present in post op HPE (12.5% vs 6.25% when no adverse HPE feature present; p=0.714).

Recurrence in the shunt was detected 2 years after completing treatment. The patient came with foreign

body sensation in the throat, which after endoscopic evaluation and biopsy revealed carcinoma. He was initially treated by upfront NTL followed by adjuvant RT. Completion Total laryngectomy was done and patient is doing well now.

Another patient developed distant metastases in the lung and liver 1 year after completing treatment. He was also treated by upfront surgery followed by adjuvant RT+CT for ENE. He received 2 cycles of palliative chemotherapy and succumbed to disease (Figure 8).

DISCUSSION

NTL constitutes approximately 1/3rd of all the laryngectomies at our institute. So far, the procedure has been done here only by a single primary surgeon. Along with the good oncological outcome and another chief aim of NTL is to provide prosthesis free voice to the patient.

Neck node and neck dissection

Presence of clinically palpable neck node seemed to influence recurrence and survival. Aslan et al described a survival rate of 84.2%, 66.7% and 0% for N1, N2 and N3 disease respectively.¹⁰ Pradhan et al had 60.6% patients with nodal disease of which 11.2% had regional and 2.2% had locoregional recurrence.⁶ Most patients with regional failure (12 of 16 patients) had advanced nodal disease at presentation (N2 or N3) and had undergone neck dissection for the same.

Table 10: Review of literature.

Authors	Percentage (%)
Pearson et al ¹¹	85
Pradhan et al ¹²	90
Aslan et al ¹⁰	70.8
Bernáldez et al ¹³	77.2
Shenoy et al ¹⁴	81
Andrade et al ¹⁵	83.3
Maamoun et al ¹⁶	81.6
Thakar et al ¹⁷	82
Cakli et al ¹⁸	82.6
Kavabata et al ¹⁹	80

In our series, there was no nodal recurrence. One case with N+(cN2, ENE+) disease had distant metastasis who eventually died. Also, those cases harbouring ENE postoperatively had higher recurrence. Considering the small number of cases, it is worth mentioning here that increased nodal disease burden and ENE should be considered as risk factors for recurrence and such patients have to be followed up closely.

NTL allows for safe oncologic resection and with simultaneous neck dissection. In the series of Pradhan et al 99 (72.3%) cases had a concurrent neck dissection at

the time of NTL.⁶ In our series, all patients had bilateral neck dissection; those with N0 neck had SND bilaterally and those with a N+ neck at least had MRND on involved side.

Voice outcome

Most of the patients (89.28%) developed voice and had communicable speech. Only 3 patients did not develop any speech. Two of them had shunt stenosis. One of them was in a salvage NTL case.

Pradhan et al found 90% of patients having communicable speech in their analysis of patients who underwent NTL.⁶ D’Cruz et al in their review paper on NTL, suggested that satisfactory voice outcome is achieved in NTL even after adjuvant radiotherapy.⁷

Table 10 shows intelligible voice outcome ranging between 70.8% and 90% following NTL.

Oncological outcome

The prime concern in an oncological procedure is its safety, measured in terms of recurrence and survival. In the study by Pradhan et al 70.1% patients were alive and disease free.⁶ Seven (5.1%) patients had local recurrence, 3 (2.19%) had locoregional, 16 (11.67%) patients had pure regional and 9 (6.57%) patients had distant metastasis. In the largest series of NTL by Pearson et al they could demonstrate a local recurrence rate of 7%.¹¹

Kavabata et al demonstrated a survival rate of 81.6% in their series with 19.9% local recurrence and 13.3% distant metastasis.¹⁹ Andrade et al could show 5-year actuarial overall survival rates were of 81.7% in larynx carcinoma and 66.6% in pyriform sinus carcinoma.¹⁵ There were 8 (19.04%) recurrences, 2 local, 2 in the neck and 4 distant.

In our study there were 2 recurrences, one in the shunt and the other was a distant metastasis to lung and liver. There was no case of nodal recurrence. The case of shunt recurrence was salvaged by surgery and is now disease free. This patient even had his voice restored with a TEP.

The patient with metastasis died eventually. It is to be noted that this patient had ENE on post op HPE. All the remaining patients are alive and disease free at their last follow-up.

Salvage NTL

In our series, there were two cases where NTL has been performed as a salvage procedure. Both patients had recurrence of Ca PFS following radical RT and were restaged rT2N1 and rT3N0. Both are disease free after NTL.

However, the first patient developed PCF 3 weeks post operatively. He also had tracheostomy site stenosis and shunt stenosis. Tracheostomy site was widened surgically but dilatation of the shunt failed to produce any voice. The other patient had some difficulty in swallowing but he has acceptable voice.

Pearson et al had a shunt recurrence rate of 20% with a 0% surgical salvage in patients with failed radiotherapy in supraglottic and pyriform sinus cancers.¹¹

Pradhan et al had 15 patients selected for NTL as salvage surgery.⁵ The local control rate was 93.3% in salvage NTL after radical radiotherapy. Two patients had major pharyngeal leak, one of whom died and the other lost the voice shunt.

Patient selection in a post irradiated patient is very crucial. Not only the PCR and IA region has to be disease free and non edematous, there should also be no fibrosis and the mucosa should be lax in that region.⁶ All these criteria were fulfilled in our case.

Still one patient had multiple complications and did not eventually have any communicable voice and the other patient had difficulty in swallowing. Our experience with salvage NTL is however low and further experience will help us come to a consensus regarding management of such patients.

Complications

NTL is based on creating an active, unidirectional shunt that permits air from lung to the neopharynx while preventing aspiration. Any disruption in its function can jeopardise outcome.

Literature quotes shunt stenosis, aspiration and PCF as major complications after NTL.^{6,7,11,18,20}

In our series, tracheostomy stenosis (6 cases) was the most common complication, followed by poor swallowing (5 cases), PCF (4 cases) shunt stenosis (3 cases), aspiration (3 cases) and Chyle leak (1 case).

Shunt stenosis

In NTL, shunt stenosis can affect the voice outcome subsequently. Also, it can point to a local recurrence.

Kavabata et al reported a single case of shunt stenosis who subsequently failed to develop any voice in their series of 15 patients.¹⁹ Pradhan et al observed a shunt stenosis rate of 6.6%.⁶

D'Cruz et al in their review of NTL recommends several dilatations in cases of shunt stenosis.⁷ They also recommend using a size 14F catheter to construct the shunt. Pearson used and recommended using the same

size for shunt creation.⁵ We have also used 14F catheter while developing the shunt.

In our series, 3 patients had shunt stenosis, all of which were evaluated endoscopically which showed no recurrence. One patient developed speech after dilatation while the other 2 failed to develop any speech. One of those was the salvage NTL case.

Aspiration

NTL with a properly functioning shunt acts as a one-way valve preventing food materials to enter the respiratory tract. While aspiration generally means compromise of function of the unit, it also warrants a look into the neopharynx for any recurrence.

Aspiration rates from 10% to 42% have been reported in the literature.⁷ In our series, 3 cases (10.71%) developed minor aspiration, all of which resolved after conservative treatment.

Aslan et al reported 26.7% aspiration in their series and 5.5% were major requiring surgical intervention.¹⁰ However, only 57.1% could be corrected after a surgical procedure. Pradhan et al reported 12.1% minor aspiration in their series and only 0.7% major aspiration that required total laryngectomy.⁶

PCF

PCF is a dreaded complication following total laryngectomy and it is anticipated more so in NTL because of the uneven suture line caused by the invagination of the shunt into the neopharynx.⁷ The highest incidence (53%) was reported by Kavabata et al and 50% by Gallivan et al.^{18,21} Pradhan et al reported 8.7% of major PCF with 3.5% requiring surgical intervention.⁶ Similarly, Andrade et al had 21.4% PCF in their series.¹⁵

The incidence of PCF was 14.29% in our series and all resolved by conservative means within 6 weeks.

Tracheostomy site stenosis

This was the most common complication in our series with 6 patients (21.43%) presenting to the OPD with progressive difficulty in respiration. All of them were managed initially by inserting wide bore tracheostomy tube and subsequently were surgically widened.

Andrade et al reported 4 patients with tracheal stenosis as the most common late complication and they could correct it with a simple tracheoplasty.¹⁵

This could be attributable to the fact that the side wall of the trachea is sutured to the skin as opposed to the end of the trachea in a total laryngectomy.

Limitations

There are a few limitations of this study however. First, the surgery was carried out by a single surgeon and any technical difficulties or methods shared are entirely from his experience. Secondly, the number of salvage NTL is low in our series. Higher number of cases would enable us to come to a clearer conclusion regarding management and outcome of salvage NTL cases.

CONCLUSION

NTL is an oncologically safe procedure with good oncological outcome and acceptable voice in most patients. The complications are also manageable. However, the procedure itself is technically challenging which is why despite the favourable outcomes, there are only a few centres across the world/ country where NTL is performed.

We share our experience with NTL performed at State cancer institute, Guwahati, India, by a single primary surgeon with an aim to encourage more ENT and Head and Neck Surgeons to learn the skill and perform the surgery in carefully selected cases.

ACKNOWLEDGEMENTS

Author would like to thank Dr. R. Borthakur, Dr. (Mrs.) A. Chakraborty, Dr. Jyotish Saikia, Dr. Arjun Roy and Dr. Yousuf F. Choudhury, department of head and neck oncology, SCI, GMC for their valuable support.

Funding: No funding sources

Conflict of interest: None declared

Ethical approval: The study was approved by the Institutional Ethics Committee

REFERENCES

- Nocini R. Updates on larynx cancer epidemiology. Chin J Cancer Res. 2020;32(1):18-25.
- Bradley PJ, Eckel HE. Hypoharyngeal Cancer. Adv Otorhinolaryngol. Basel, Karger. 2019;83:1-14.
- Forastiere AA. Use of larynx-preservation strategies in the treatment of laryngeal cancer: American Society of Clinical Oncology clinical practice guideline update. J of clinical oncol. 2018;36(11):1143-69.
- NCCN guidelines version 3. 2021.
- Pearson BW, Desanto LW. Operative techniques in otolaryngology-head and neck surgery. 1990;1(1):28-41.
- Pradhan SA, D'Cruz AK, Pai PS, Mohiyuddin A. Near-total laryngectomy in advanced laryngeal and pyriform cancers. Laryngoscope 2002;112:375-80.
- D'Cruz A, Sharma S, Pai PS. Current status of near-total laryngectomy: review. J Laryngol Otol. 2012;126:556-62.
- Pearson BW, Woods RD 2nd, Hartman DE. Extended hemilaryngectomy for T3 glottic carcinoma with preservation of speech and swallowing. Laryngoscope. 1980;90:1950-61.
- Pearson BW. Subtotal laryngectomy. Laryngoscope. 1981;91:1904-12.
- Aslan I, Baserer N, Yazicioglu E, Biliciler N, Hafiz G, Tinaz M et al. The functional and oncologic effectiveness of near-total laryngectomy. Am J Otolaryngol. 2002;23:196-20.
- Pearson BW, DeSanto LW, Olsen KD, Salassa JR. Results of near-total laryngectomy. Ann Otol Rhinol Laryngol 1998;107:820-5.
- Pradhan SA, D'Cruz AK, Pai PS. Near-total laryngectomy. Asian J Surg. 2002;25:27-34.
- Bernáldez R, García-Pallarés M, Morera E, Lassaletta L, Del Palacio A, Gavilán J. Oncologic and functional results of near total laryngectomy. Otolaryngol Head Neck Surg. 2003;128:700-5.
- Shenoy AM, Plinkert PK, Nanjundappa N, Premalata S, Arunodhay GR. Functional utility and oncologic safety of neartotallaryngectomy with tracheopharyngeal speech shunt in a Third World oncologic center. Eur Arch Otorhinolaryngol. 1997;254:128-32.
- Andrade RP, Kowalski LP, Vieira LJ, Santos CR. Survival and functional results of Pearson's near-total laryngectomy for larynx and pyriform sinus carcinoma. Head Neck. 2000;22:12-6.
- Maamoun SI, Amira G, Younis A. Near total laryngectomy: a versatile approach for voice restoration in advanced T3 and T4 laryngeal cancer: functional results and survival. J Egypt Natl Canc Inst. 2004;16:15-21.
- Thakar A, Bahadur S, Toran KC, Mohanti BK, Julka PK. Analysis of oncological and functional failures following near total laryngectomy. J Laryngol Otol. 2009;123:327-32.
- Cakli H, Ozudogru E, Cingi E, Kecik C, Gürbüz K. Near total laryngectomy: the problems influencing functions and their solutions. Eur Arch Otorhinolaryngol. 2005;262:99-102.
- Kavabata NK, Silva Neto AL, Gonçalves AJ, Alcadipani FA, Menezes MB. A nine-year institutional experience with near total laryngectomy. Am J Surg. 2004;188:111-4.
- Puri A, Patel MH, Kothari KC. Near total laryngectomy-complications, function and survival: A sixteen-year institutional experience. Ann Otol Rhinol Laryngol. 1998;107(10 Pt 1):820-5.
- Gavilan J. Speech results and complications of near-total laryngectomy. Ann Otol Rhinol Laryngol. 1996;105:729-33.

Cite this article as: Das MP, Sarma MK, Choudhury MM, Missong AK. Near total laryngectomy: a single institutional experience. Int J Res Med Sci 2021;9:3526-33.