

Review Article

Orthopaedic aspect of anatomy and radiology of proximal femur

Pokhraj P. Suthar^{1*}, Chirag D. Patel², Manoj Gamit², Dhaval J. Dave³, Chandni Wadhvani¹,
Bhumikaben P. Suthar¹

¹Department of Radiology, S.S.G. Hospital, Medical College, Vadodara, Gujarat, India

²Department of Orthopaedics, S.S.G. Hospital, Medical College, Vadodara, Gujarat, India

³Department of Medicine, S.S.G. Hospital, Medical College, Vadodara, Gujarat, India

Received: 12 June 2015

Accepted: 09 July 2015

*Correspondence:

Dr. Pokhraj Suthar,

E-mail: pokhraj_suthar@yahoo.co.in

Copyright: © the author(s), publisher and licensee Medip Academy. This is an open-access article distributed under the terms of the Creative Commons Attribution Non-Commercial License, which permits unrestricted non-commercial use, distribution, and reproduction in any medium, provided the original work is properly cited.

ABSTRACT

Femoral pathology is common in relation to the orthopedic. There is complex anatomy of the proximal femur and hip joint. So, its knowledge regarding anatomy and radiological correlation is necessary to the well-known fact for the orthopedics for the routine day to day practice. This review article briefly illustrates important anatomical and radiological aspect of the proximal femur.

Keywords: Proximal Femur, Anatomy, Radio imaging, Orthopaedics

INTRODUCTION

Proximal femur:

The form of the femur is relatively complex, with bows and twists that distort its basically tubular structure. The anterior bow of the midportion of the femur is well recognized. This is commonly envisioned as an anterior bow because of the position that the separate femur assumes when it is placed on a horizontal surface, resting on the posterior margin of the trochanter and the posterior aspects of the condyle. However, in vivo the orientation is somewhat different. In the erect position, the central portion of the femur is more in the coronal plane of the body, with the distal portion inclined posteriorly to the knee and the proximal portion inclined anteriorly to the acetabulum (Figure 1). The posterior bow of the proximal femur is just as constant as the midportion anterior bow.¹ The central portion of the proximal posterior bow is opposite the level of the lesser trochanter. This bow is constant. It is also noteworthy that the radius of curvature does not seem to change dramatically with the size of the femur. The length of the curve increases with increasing femur size from the base of the neck until the curve

reverses distal to the lesser trochanter, but the radius of the curve is relatively constant.

The neck-shaft angle:

The head of the femur considerably overhangs the femoral shaft. This occurs because the neck makes an oblique angle with the shaft of an average of range 125°-140°.² Although there is considerable variability in both the neck-shaft angle and neck length, in general the center of the femoral head is extended medially and proximally by the femoral neck so that the center of the femoral head is at the level of the tip of the greater trochanter. The effect of the overhanging head and neck is to lateralize the abductors, which attach to the greater trochanter, from the center of rotation (center of the femoral head). This increases the torque generated by the abductors and reduces the overall force necessary to balance the pelvis during single leg stance. Reducing this lever arm (coxavagla) increases total load across the hip and coxavara reduces it as it increases the lever arm. (Coxavara with a short neck would have a negative effect) (Figure 2).



Figure 1: Femur positioned in the neutral plane, as it is in the body.

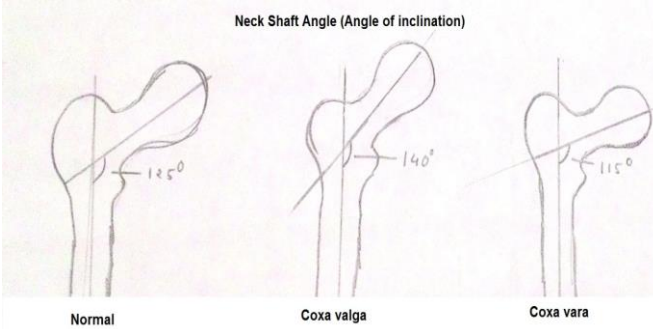


Figure 2: Femoral neck shaft angle.

Femoral anteversion:

The coronal plane of the femur is generally referenced to the posterior distal femoral condyles. When oriented in this plane, it can be seen that the proximal femur, including the femoral head and neck, are rotated anteriorly.³ This is commonly referred to as femoral head-neck anteversion. However, it is really a combination of a torsional change in the intertrochanteric part of the femur and a further anteversion of the femoral neck based upon this torsion. The sum of this change is that the adult femoral head and neck are in a plane 10-15° anteriorly oriented to the coronal plane (Figure 3).

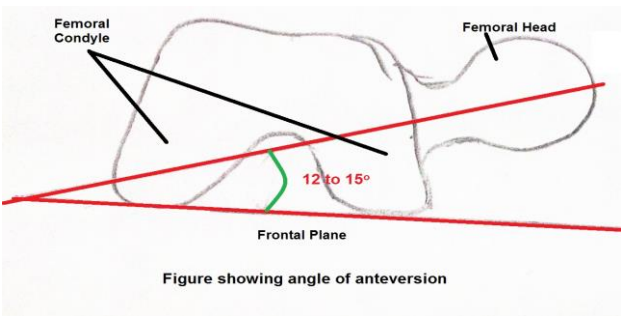


Figure 3: Femoral neck anteversion.

The femur is the longest and the strongest bone of the body. Its length is associated with mankind's striding gait and strength with the weight and muscular forces which it must withstand. The upper end bears a rounded head whereas the lower end is widely expanded to form two condyles.

The upper end of the femur comprises of the head, neck, greater trochanter and the lesser trochanter (Figure 4).

Plain radiographic and computed tomographic anatomy is also illustrated (Figure 5 and 6).

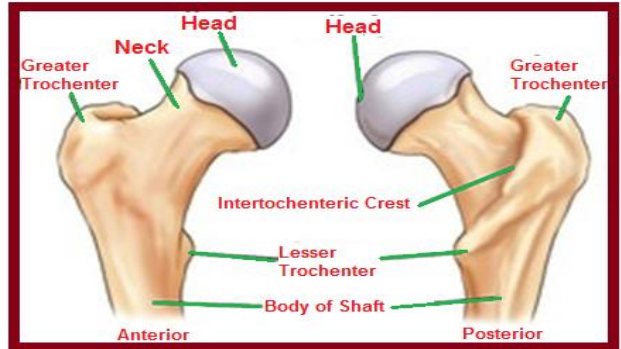


Figure 4: Anatomy of proximal femur.

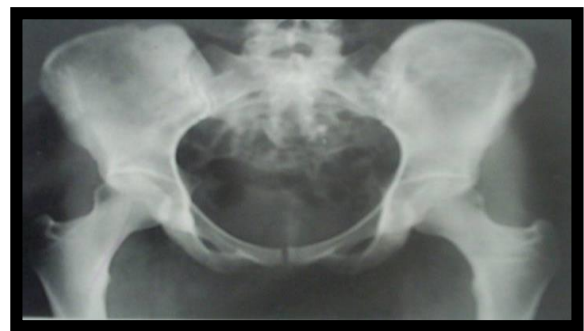

Figure 5: X-ray pelvis with both hip joint antero-posterior views shows entire pelvis along with the proximal femora, lesser trochanters demonstrated on the medial border of the femora. Femoral necks in their full extent without superimposition. Greater trochanters in profile.

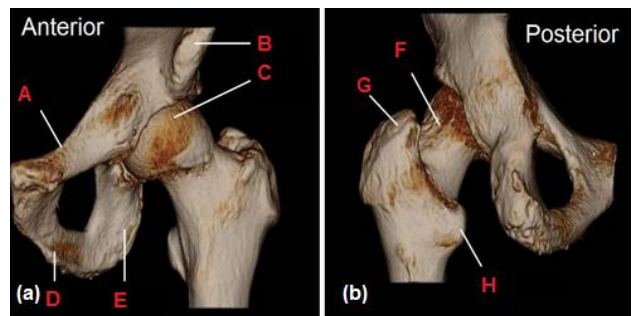


Figure 6: 3-D volume rendered CT image of the proximal femur and hip is seen from the anterior view (a) and posterior (b) aspects: superior pubic ramus (A), inferior pubic ramus (D), ilium (B), head of femur and hip joint (C), and ischium (E). From the posterior view structures demonstrated are: the neck of the femur (F), greater trochanter (G), and lesser trochanter (H). The intertrochanteric crest is seen as a sharp ridge of bone on the posterior side of the proximal femur between the lesser and greater trochanters.

Head

It forms more than half of a sphere and is directed medially, upwards and slightly forward to articulate with the acetabulum. Its surface is smooth and covered with hyaline cartilage. A little below and behind its center is a small-roughened pit called the fovea, which provides attachment to the ligament of the head of femur (ligamentum teres). The head is entirely intracapsular and is encircled immediately to its greater diameter by the acetabular labrum. The inferomedial part of the anterior surface of the head is related to the femoral artery, from which it is separated by the tendon of the psoas major and the articular capsule.

Neck

It is about 5 cm long and connects the head and the shaft, with which it forms an angle of about range 125°-140° degrees.⁴ This arrangement facilitates the movement of the hip joint and enables the lower limb to swing to clear of the pelvis. This angle is less in females due to their wider pelvis. The neck is narrowest at its middle and is wider at its lateral than medial end. Its two borders are rounded. The upper border is roughly horizontal and is gently concave upwards. The lower border is straighter but oblique and is directed downwards, laterally and backward to meet the shaft near the lesser trochanter. The anterior surface of neck is flattened and a prominent rough ridge termed the intertrochanteric line marks its junction with the shaft. The posterior surface is convex backwards and upward in its transverse axis and concave in its long axis and its junction with the shaft is marked by a rounded ridge, termed the intertrochanteric crest. The anterior surface of the neck is entirely intracapsular while only a little more than the medial half of the neck lies within the capsule posteriorly. The neck of the femur does not lie in the same plane as the shaft, but is carried forwards as it passes upwards and medially. On this account, the transverse axis of the head of the femur makes an angle with the transverse axis of the lower end of bone and this angle is known as the angle of femoral torsion (approx. 15 degrees).

Greater trochanter

It is a quadrangular projection at the upper part of the junction of the neck with the shaft. Its postero-superior portions project upwards and medially so as to overhang the adjoining part of the posterior surface of the neck. In this situation its medial surface presents a roughened-depressed area, the trochanteric fossa. The upper border of trochanter lies at the level of center of head. The anterior surface is rough.⁵ Its lateral surface is divided into two areas by an oblique ridge directed downwards and forwards. Medial surface presents rough impression, which provides insertion to the common tendon of obturator internus and two gemelli. The lateral surface of the trochanter can be palpated in the living; and when the adjoining muscles are relaxed, trochanter can be gripped.

Lesser trochanter

It is a conical eminence, which projects medially and backwards from the shaft at its junction with the lower and posterior part of the neck. Its summit and anterior surface are roughened, but its posterior surface with lower end of intertrochanteric crest is smooth. It is placed too deeply to be felt in the living.

Intertrochanteric line

It marks the junction of the anterior surface of the neck with the shaft of femur. It is a prominent roughened ridge, which commences in a tubercle at the upper and medial part of the anterior surface of the greater trochanter and runs downwards and medially. It reaches the lower border of the neck on a level with the lesser trochanter, but in front of it. Below, it is continuous with the spiral line.

Intertrochanteric crest

It marks the junction of the posterior surface of the neck with the shaft of femur. It is a smooth round bridge, which commences at the postero-superior angle of the greater trochanter and runs downwards and medially to terminate at the lesser trochanter. A little above its middle, it presents a low rounded elevation, the quadrate tubercle.⁶

Ossification

The upper end of femur is ossified from three secondary centers, one each for the head, greater trochanter and lesser trochanter. The secondary center appears in the head during the first 6 months after birth, in the greater trochanter during the 4th year and in the lesser trochanter between the 12th and 14th year. The epiphysis fuse independently with the shaft and the lesser trochanter soon after puberty, then the greater trochanter, then the head at 16th year in females, and 18th year in males.

Blood supply of the trochanter

The medial and lateral circumflex femoral arteries, which are the branches of the profunda femoris artery, are the primary arteries supplying proximal end of the femur. At the base of the femoral neck, at the level of capsular attachments, an extracapsular ring of arteries is formed; its posterior portion is derived from a well-defined branch of medial circumflex femoral artery while anteriorly, branches of lateral circumflex femoral artery complete the ring.

Branches arise from this ring at regular intervals passing upwards along the femoral neck and downwards and laterally to supply trochanter and base of the neck. Because of this arterial ring, the trochanter has very rich blood supply.

MUSCULAR ATTACHMENTS

Greater trochanter

It provides insertion for most of the muscles of the gluteal region. Gluteus minimus is inserted into the rough impression on its anterior surface.⁷ The gluteus medius is inserted into the oblique flattened strip, which runs downwards and forwards across its lateral surface. The area in front of this insertion is separated from the tendon by the trochanteric bursa of gluteus medius; the area behind the insertion is covered by the deep fibers of the gluteus maximus and part of the trochanteric bursa of that muscle may be interposed. The upper border of the trochanter gives insertion of piriformis and its medial surface to the common tendon of obturator internus and the gemelli. The trochanteric fossa receives the insertion of obturator externus.

Lesser trochanter

Psoas major is inserted on the apex and medial part of the rough anterior surface. Iliacus is inserted on the anterior surface and on the base of lesser trochanter and the area below it. The smooth surface is covered by a bursa deep to the upper horizontal fibers of adductor magnus.

Intertrochanteric line

It marks the lateral line of the capsular ligament of the hip joint. Its upper part receives attachment of the upper band of the ilio-femoral ligament; its lower part receives the lower band of the same ligament. The highest fibers of the vastuslateralis arise from the upper end of the line and the highest fibers of the vastusmedialis from its lower end.

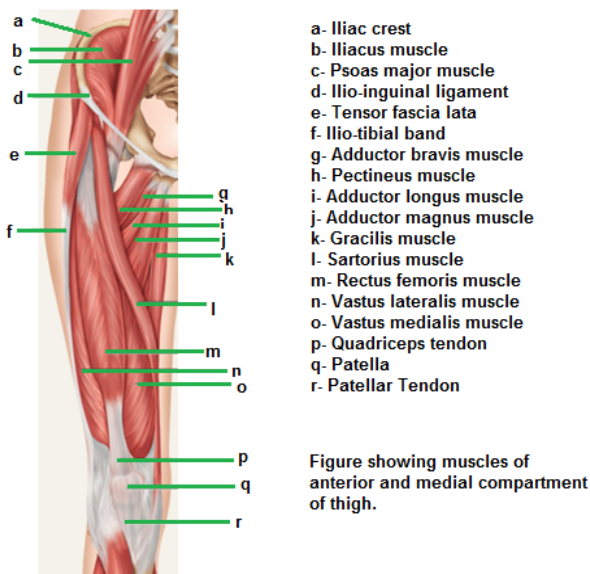


Figure 7: Figure showing muscle attachment on the anterior and medial aspect of femur.

Inter trochanteric crest

Above the quadrate tubercle, it is covered by the gluteus maximus; below the quadrate tubercle, it is separated from that muscle by the quadratusfemoris and the upper border of adductor magnus. The tubercle itself a portion of the bone below and receive the insertion of the quadratusfemoris (Figure 7 and 8). Normal MRI anatomy with muscle attachments also illustrated (Figure 9 and 10).

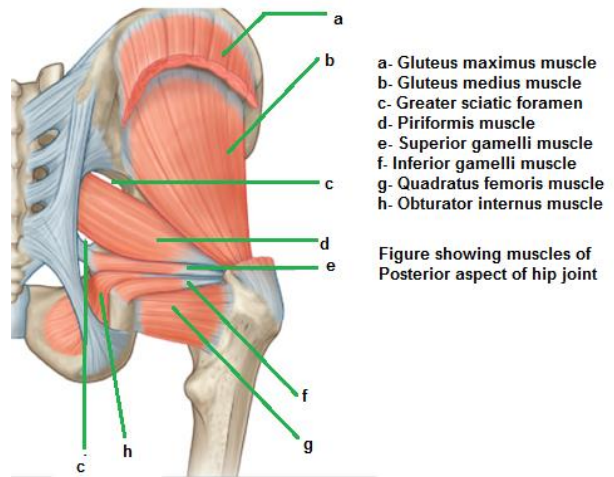


Figure 8: Figure showing muscle attachment on the posterior aspect of the hip joint.

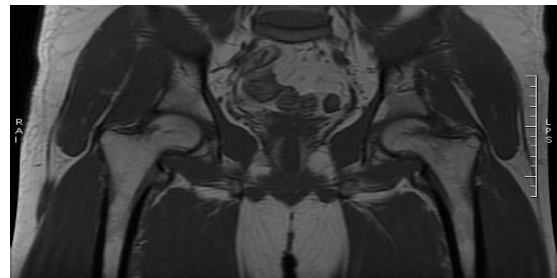


Figure 9: Coronal T1 Weighted MR image shows normal bilateral proximal femur with hip joints.

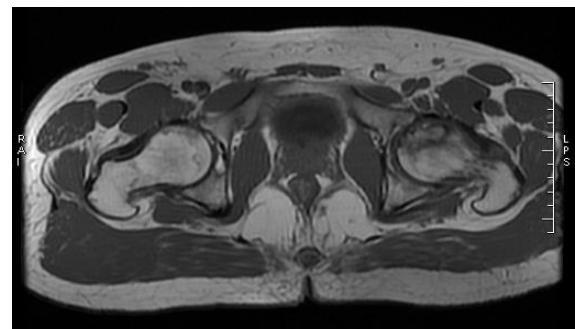


Figure 10: Axial T1 Weighted MR image shows normal bilateral proximal femur with hip joints.

MOVEMENTS OF THE HIP JOINT

The hip joint is a multi-axial ball and socket variety of synovial joint. It is a very Stable joint, which has been gained at the cost of its movement⁸ (Table 1).

Pecularity of hip joint movers

Hip joint motion results from the contraction and controlled relaxation of muscle groups, and as such, these movements are represented in the cerebral cortex. The initial position of joint has a marked influence on the

action of adjacent muscle.⁹ Starting from the extension, the gluteus medius and minimus produce abduction of the hip joint, although the anterior fibers may aid in internal rotation and posterior fibers in external rotation. The obturator internus are an external rotator. However, starting from the flexed position, the same glutei now produces internal rotation of the joint and the obturator internus has become an abductor. Similarly, at the flexed hip joint, the gluteus maximus slips anteriorly over the greater trochanter to become an abductor. The short pericapsular muscles are more important as postural muscles and stabilizers, reinforcing the capsule to which they are often attached, than as prime movers of the joint.

Table 1: Shows muscle involve in the movement around the hip joint.

Movements	Primary Muscles	Secondary Assisted by
Flexion	Psoas major, Iliacus	Pectineus, Rectus femoris, Sartorius
Extension	Gluteus Maximus, Hamstrings	-
Abduction	Gluteus medius, Gluteus minimus	Tensor Fascia lata, Sartorius
Adduction	Adductor longus, Adductor brevis, Adductor magnus	Pectineus, Gracilis
Medial Rotation (Internal)	Tensor fascia lata, Anterior fibers of gluteus medius and minimus	-
Lateral Rotation (External)	Obturator, Gamelli, Quadratus femoris	Pyriformis, Gluteus maximus, Sartorius

SUMMARY

Femoral pathology is common in relation to the orthopedic. There is complex anatomy of the proximal femur and hip joint. So, its knowledge regarding anatomy and radiological correlation is necessary to the well-known fact for the orthopedics for the routine day to day practice.

Funding: No funding sources

Conflict of interest: None declared

Ethical approval: Not required

REFERENCES

- Gdalevich M, Cohen D, Yosef D, et al. Morbidity and mortality after hip fracture: the impact of operative delay, Arch Orthop Trauma Surg. 2004;124:334.
- Cornwall R, Gilbert MS, Koval KJ, et al. Functional outcomes and mortality vary among different types of hip fractures: a function of patient characteristics, Clin Orthop Relat Res. 2004;425:64.
- Southwell-Keely JP, Russo RR, March L, et al. Antibiotic prophylaxis in hip fracture surgery: a meta-analysis, Clin Orthop Relat Res. 2004;419:179.
- Gautier E, Ganz K, Krügel N, et al. Anatomy of the medial femoral circumflex artery and its surgical implications, J Bone Joint Surg. 2000;82B:679.
- Haentjens P, Autier P, Boonen S. Clinical risk factors for hip fracture in elderly women: a case-control study, J Orthop Trauma. 2002;16:379.
- Tyllianakis M, Panagopoulos A, Papadopoulos A, Papisimos S, Mousafirios K. Treatment of extracapsular hip fractures with the proximal femoral nail (PFN): Long term results in 45 patients Acta Orthop Belg. 2004;70:444-54.
- Endo Y, Aharonoff GB, Zuckerman JD, et al. Gender differences in patients with hip fracture: a greater risk of morbidity and mortality in men, J Orthop Trauma. 2005;19:29.
- Su H, Aharonoff GB, Zuckerman JD, et al. The relation between discharge haemoglobin and outcome after hip fracture, Am J Orthop. 2004;33:576.
- Harrison T, Robinson P, Cook A, Parker MJ. Factors affecting the incidence of deep wound infection after hip fracture surgery, J Bone Joint Surg. 2012;94B:237.

Cite this article as: Suthar PP, Patel CD, Gamit M, Dave DJ, Wadhvani C, Suthar BP. Orthopaedic aspect of anatomy and radiology of proximal femur. Int J Res Med Sci 2015;3(8):1820-4.