

Case Report

Microsurgery in complex trauma of pelvic limb in a pediatric patient: case report

Rodrigo Banegas-Ruiz¹, Luis E. Loyo Soriano², Francisco Fabián Gómez-Mendoza³,
Rodrigo A. Mendoza-Aceves⁴, Rigoberto Roman-Hernández⁵, Christian Porrás-Méndez⁶,
Alan I. Valderrama-Treviño⁷, Emilio Pérez-Ortega⁸, Ismael Vejar Alba⁹, Rubén Olivares Ulloa¹,
Leonel Dalain Hernández-Arteaga¹⁰, Erick Salvador-Juárez Duarte¹¹,
Baltazar Barrera-Mera^{12*}

¹Department of Traumatology, ²Department of Pediatric Surgery, Rehabilitation Hospital, Luis Guillermo Ibarra Ibarra, CDMX, Mexico

³Department of Hand Surgery, ⁵Department of Peripheral Vascular Surgery, ⁹Department of Maxillofacial Surgery, Central Military Hospital, CDMX, Mexico

⁴Department of Anesthesiology, Angeles del Pedregal Hospital, CDMX, Mexico

⁶Department of General Surgery, High Specialty Hospital, Veracruz, Mexico

⁷Laboratory of Experimental Immunotherapy and Tissue Engineering, ⁸Faculty of Medicine, ¹²Department of Physiology, UNAM, CDMX, Mexico

¹⁰Faculty of Medicine, Autonomous University of Queretaro, Mexico

¹¹Department of Radiology and Imaging, Star Medical Hospital, CDMX, Mexico

Received: 13 August 2019

Revised: 24 August 2019

Accepted: 28 August 2019

*Correspondence:

Dr. Baltazar Barrera-Mera,

E-mail: baltazar.barrera.mera@gmail.com

Copyright: © the author(s), publisher and licensee Medip Academy. This is an open-access article distributed under the terms of the Creative Commons Attribution Non-Commercial License, which permits unrestricted non-commercial use, distribution, and reproduction in any medium, provided the original work is properly cited.

ABSTRACT

Complex trauma is defined as the condition secondary to the exchange of kinetic energy of two or more tissues in one limb. This entity is a surgical emergency that can have many sequelae and can even result in limb loss. An 11-year-old female patient presents complex pelvic limb trauma secondary to contuse injury caused by a helicopter's rotor blades. Pelvic limb reconstruction was performed with iliac crest bone graft, the fracture was stabilized with an external fixator and the skin defect was covered with an anterolateral microvascular thigh flap (ALT). There was an adequate integration of the bone graft with adequate skin coverage thanks to the ALT thigh flap. The patient presented discreet limb shortening as consequence. Currently, microsurgery is the only medical option that meets the objectives of limb reconstruction. Microsurgical techniques can be used in pediatric and adult patients. The success of any recovery from complex trauma is vigorous surgical cleaning, avoiding sequential and/or multiple washes.

Keywords: Anterolateral thigh flap, Complex limb trauma, Lower limb, Micro vascular surgery, Pediatric trauma, Reconstruction

INTRODUCTION

Complex trauma is defined as the condition secondary to the exchange of kinetic energy of two or more tissues in

one limb. This entity is a surgical emergency that can have many sequelae or even the limb can be lost. To achieve a successful surgery, timely treatment with a multidisciplinary approach should be given and if tissue

loss is found, necrosectomy, bone stability and microsurgery are the best treatment options. With reconstructive microsurgery, a hand or finger accidentally separated from the body can now be reimplanted and reconstruction of complex defects; such as the ones caused by cancer, trauma or burns, can be performed.¹ Primary amputation was once the fundamental treatment for massive lower extremity injuries. With today's advances in microsurgical techniques, along with a better understanding of soft-tissue, bone anatomy and physiology, surgeons have the ability to salvage traumatized lower extremities after high-energy injuries.²

Motor vehicle crash and falls account for 42% of the traumatic incident in pediatrics, causing a variety of musculoskeletal injuries with extensive soft tissue loss.³ The best available technique for reconstruction is free tissue transfer.⁴

Free tissue transfer using microsurgical techniques has become a valuable method for salvaging lower extremities after trauma.² Many protocols have been described to reconstruct severe lower extremity trauma and all include the same basic principles: wide debridement, primary fracture stabilization, early coverage with well vascularized tissue, and skeletal reconstruction.^{2,5,6}

Free flap reconstruction is a three-dimensional process that requires considerable preoperative planning. The best donor site should be chosen, and the flap precisely designed to meet the needs of the recipient site. These types of surgeries present a challenge because of the presence of two separate surgical fields, both requiring extensive work and the precise coordination of the surgical team to achieve a successful procedure.¹

CASE REPORT

An 11-year-old female patient presents complex pelvic limb trauma secondary to contuse injury caused by a helicopter's rotor blades (Figure 1).

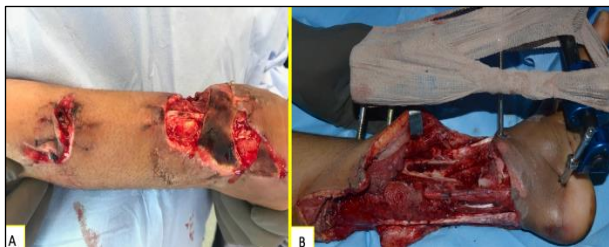


Figure 1: (A) Trauma complex of left pelvic limb, devitalized tissue. (B) Adequate surgical cleaning with necrosectomy after bone stability, by external fixator.

The incident happened in the town of Ixtepec, Oaxaca, Mexico. The helicopter was going to provide help and fell due to a mechanical failure. The patient was treated by the Secretary of National Defense (SEDENA) service

and limb amputation was proposed. However, the health authorities requested support from the National Rehabilitation Institute where the pelvic limb reconstruction was performed with iliac crest bone graft, the fracture was stabilized with an external fixator and the skin defect was covered with an anterolateral microvascular thigh flap (ALT). (Figures 2, 3, 4).

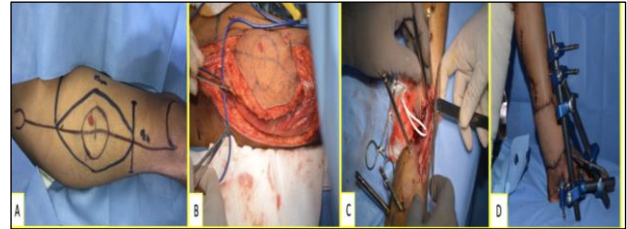


Figure 2: (A): Marking of the anterolateral thigh flap, 9 x 15 cm. (The red dot is the perforator blood vessel). (B) Flap Lift (C) Dissection of the recipient vessels (anterior tibialis) (D) Final result: ALT flap with external fixation device.

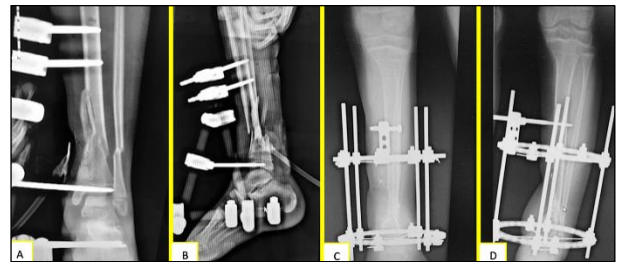


Figure 3: (A) Anteroposterior radiograph, (B) Lateral radiograph of the left leg. (C) Anteroposterior radiography, (D) Lateral radiograph of the left leg after one year. There is alignment of the bone fragments as well as the formation of bone trabeculae through the continuity solution sites, which suggests complete consolidation.

Multifragmented bone tissue is observed at the level of the distal third of the tibial and peroneal diaphysis, slight displacement and angulation of the bone fragments can be appreciated.

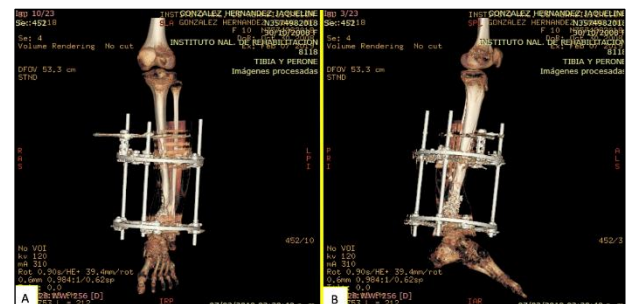

Figure 4: (A) Anteroposterior 3D tomographic reconstruction, (B) Lateral 3D tomographic reconstruction of the left leg. The proper alienation of bone fragments at fracture sites is observed in detail.

There is a slight increase in density at the level of fracture sites which may suggest incipient formation of endoscopic callus. There are radio bale images with density in metallic range in relation to post-surgical material (Figure 3).

DISCUSSION

Currently, anterolateral thigh perforator flap has become the standard for the reconstruction of such complex defects. The flap has two types of feeding perforator: septocutaneous (15%), or musculocutaneous (85%). The availability of sizable perforator ranges between 0-3 perforators, with an average diameter of 1.89-2.04 mm.^{7,8}

For complex ankle defects and distal third open tibial fractures, a free muscle flap is the treatment of choice in a severely comminuted fracture, large volume of tissue deficiency and presence of a deep dead space.^{2,9}

The ultimate goal of reconstructive surgery is to replace like with like to optimally restore not only function but also form and contour of the lower limb. Tissue defects reconstruction has to be planned carefully, contemplating the specific pediatric anatomy and the evolution of children's tissue and skeletal structures.¹⁰

Reconstruction of lower extremity defects in pediatric patients is difficult because the skin around the foot and ankle is thin, and there are several structures in this small area. Debridement of dead tissue is of utmost importance to successfully treat complex tissue defects in this area, as well as the effective repair or reconstruct ligaments, tendons, bones, joints, nerves, and vascular structures, after which early tissue coverage can be achieved.¹¹ As in adult patients, a free ALT flap can be a safe choice for pediatric patients with minimal donor site morbidity to treat defects following trauma around the foot and ankles.¹²

CONCLUSION

Currently, microsurgery is the only medical option that meets the objectives of limb reconstruction: (a) Preservation of the limb's length, (b) adequate skin coverage, (c) bone stability, (d) sensitive reconstruction, (e) cost-effective (f) early discharge within 15 days as well as an easier surgical approach in subsequent surgeries, should they be needed. Microsurgical techniques can be used in pediatric and adult patients. The success of any recovery from complex trauma is vigorous surgical cleaning, avoiding sequential and/or multiple washes.

Funding: No funding sources

Conflict of interest: None declared

Ethical approval: Not Required

REFERENCES

1. Ramírez LE. Microcirugía reconstructiva. Revista Salud UIS. 2004 Sep 8;36(3):166-70.
2. Korompilias AV, Lykissas MG, Vekris MD, Beris AE, Soucacos PN. Microsurgery for lower extremity injuries. Injury. Int. J. Care Injured. 2008; S103-8.
3. Joyce SM, Brown DE, Nelson EA. Epidemiology of pediatric EMS practice: a multistate analysis. Prehospital and disaster medicine. 1996 Sep;11(3):180-7.
4. Gelidan AG. Salvage of planned ALT flap with rectus femoris free flap for pediatric lower extremity reconstruction: A demonstrative case report. International journal of surgery case reports. 2018 Jan 1;51:67-70.
5. Godina M. Early microsurgical reconstruction of complex trauma of the extremities. Plast Reconstr Surg. 1986;78(3):285-92.
6. Lin CH, Lin YT, Yeh JT, Chen CT. Free functioning muscle transfer for lower extremity posttraumatic composite structure and functional defect. Plast Reconstr Surg. 2007;119(7):2118-26.
7. Wong CH, Wei FC, Fu B, Chen YA, Lin JY. Alternative vascular pedicle of the anterolateral thigh flap: the oblique branch of the lateral circumflex femoral artery. Plastic and reconstructive surgery. 2009 Feb 1;123(2):571-7.
8. Yoshihiro K, Klyotaka Y, Satoshi E, Takashi N, Klyonori H. Anatomical variation and technical problems of the ALT flap. A report of 74 cases. Plast. Reconstr. Surg. 1998;102:1517.
9. Yazar S, Lin CH, Lin YT, Ulusal AE, Wei FC. Outcome comparison between free muscle and free fasciocutaneous flaps for reconstruction of distal third and ankle traumatic open tibial fractures. Plastic and reconstructive surgery. 2006 Jun 1;117(7):2468-75.
10. Claes KE, Roche NA, Opsomer D, De Wolf EJ, Sommeling CE, Van Landuyt K. Free flaps for lower limb soft tissue reconstruction in children: Systematic review. J Plastic, Reconstructive and Aesthetic Surgery. 2019; 72: 711-28.
11. Song JW, Ben-Nakhi M, Hong JP. Reconstruction of lower extremity with perforator free flaps by free style approach in pediatric patients. J Reconstr Microsurg. 2012;28(9):589-94.
12. Acar MA, Güleç A, Aydın BK, Erkoçak OF, Yılmaz G, Şenaran H. Reconstruction of Foot and Ankle Defects with a Free Anterolateral Thigh Flap in Pediatric Patients. J Reconstr Microsurg. 2015;31:225-32.

Cite this article as: Banegas-Ruiz R, Loyo Soriano LE, Gómez-Mendoza FF, Mendoza-Aceves RA, Roman-Hernández R, Porrás-Méndez C, et al. Microsurgery in complex trauma of pelvic limb in a pediatric patient: case report. Int J Res Med Sci 2019;7:3895-7.