

## Original Research Article

# Diagnosis of supra-aortic artery stenosis: comparison of magnetic resonance angiography imaging methods with conventional digital subtraction angiography

Hale Aydin<sup>1\*</sup>, Agildere A. Muhtesem<sup>2</sup>

<sup>1</sup>Department of Radiology, Dr. AY Ankara Oncology Research and Training Hospital, Ankara, Turkey

<sup>2</sup>Department of Radiology, Baskent University Medical Faculty Hospital, Ankara, Turkey

**Received:** 13 March 2018

**Accepted:** 07 April 2018

### \*Correspondence:

Dr. Hale Aydin,

E-mail: [halemaydin@gmail.com](mailto:halemaydin@gmail.com)

**Copyright:** © the author(s), publisher and licensee Medip Academy. This is an open-access article distributed under the terms of the Creative Commons Attribution Non-Commercial License, which permits unrestricted non-commercial use, distribution, and reproduction in any medium, provided the original work is properly cited.

### ABSTRACT

**Background:** The aim of this study was to compare conventional digital subtraction angiography (DSA) with the multi-planar reformation (MPR) and maximum intensity projection (MIP) reconstruction of servical magnetic resonance angiography (MRA) in terms of detecting supra-aortic artery stenoses.

**Methods:** In the study, 21 patients who had underwent 3D MRA and conventional DSA were retrospectively assessed. Axial MPR, coronal MIP reconstruction and contrast enhanced 3D MRA subtraction images of a total of 333 artery segments were independently assessed by 2 separate radiologists. Conventional DSA results were accepted as gold standard results. The overall and individual Kappa values of all methods were calculated.

**Results:** Results of the conventional DSA analysis indicated total occlusion in 9 (2.7%), severe stenosis in 16 (4.8%), moderate stenosis in 90 (27.1%), mild stenosis in 105 (31.5%) and no stenosis in 113 (33.9%) arteries. While the  $\kappa$  values of all methods were high which demonstrated strong relationships with the DSA method; the coronal MIP reconstruction method was found to be superior to other methods. The 3D MRA subtraction method did not yield better results in any of the individual comparisons.

**Conclusions:** Our results indicate that the coronal MIP reconstruction method has higher correlation with conventional DSA results compared to the other two methods and may be used as an accurate first-line diagnostic method for supra-aortic artery stenoses.

**Keywords:** Carotid arter stenosis, Carotid arter occlusion, Maximum intensity projection, Supraaortic magnetic resonance angiography

### INTRODUCTION

The most common indication for the imaging of supra-aortic arteries is the evaluation of steno-occlusive diseases, especially carotid artery stenosis due to atherosclerosis.<sup>1</sup> Conventional Digital Subtraction Angiography (DSA) is still accepted as the gold standard for the detection of atherosclerotic lesions of the supraaortic arteries. However, DSA is a time consuming, expensive and invasive technique, besides various risks

such as transient ischemic attack, iodine contrast nephrotoxicity and exposure to ionizing radiation.<sup>2-4</sup>

Recent advances in 3D contrast-enhanced magnetic resonance angiography (MRA) and x-ray computed tomography (CT) angiography have altered diagnostic algorithms in cases of arterial stenosis. As a result, in the diagnosis of extracranial and intracranial steno-occlusive diseases, DSA is now being primarily used as a confirmatory method in cases that are considered to be

'suspicious' with non-invasive techniques.<sup>5</sup> Studies have indicated that contrast-enhanced MRA is superior to other non-invasive or minimally invasive methods such as duplex ultrasonography, color Doppler sonography, and CT angiography.<sup>6-8</sup>

Source images obtained with contrast enhanced MRA imaging can be evaluated with different reconstruction methods, these reconstruction and post-processing operations can directly affect image quality.<sup>9,10</sup> Images obtained after post-processing and reconstruction of MRA may also be compared with conventional DSA images for better evaluation of supraaortic arteries. In previous studies, the accuracy of contrast-enhanced MRA was compared with conventional DSA. In this study, we aimed to compare conventional DSA examinations with the coronal MIP reconstruction, axial MPR and subtraction images of contrast enhanced neck MRA.

## **METHODS**

In the current study, 21 symptomatic patients with contrast-enhanced 3D MRA and conventional DSA imaging were evaluated retrospectively. All patients were clinically evaluated by neurology or neurosurgery specialists who ordered the imaging studies. All patients underwent contrast-enhanced 3D MRA and conventional DSA within a 2-week timeframe. A total of 42 subclavian arteries, 42 main carotid arteries, 42 internal carotid arteries, 42 external carotid arteries and 42 vertebral arteries were examined in these 21 patients. In some of the patients, evaluation of the vertebral artery with the conventional DSA method was not performed because optimal images could not be obtained due to the inability to perform selective catheterization of the vertebral arteries. These segments were excluded from the study. Sites of multiple stenosis were determined in some vessel segments; these sites were considered separately. As a result, a total of 333 vessel segments were included in the study.

### ***Contrast enhanced 3D MRA imaging parameters***

3D MRA images were obtained on a 1.5T magnetic field device (Magnetom Symphony; Siemens Medical Systems) via a CP neck array coil integrated to a CP spine array. The coronal FISP (fast imaging steady-state precession) 3D sequence was used for all patients and all supraaortic arteries from the sternal notch to the base of the skull were evaluated without breath-hold. Following precontrast imaging, contrast material was injected via an autoinjector with the CARE bolus technique (22-gauge venous catheter, 2ml/sec, 0.2ml/kg dose of 0.5 mmol/mL Gadodiamid; Omniscan, Nycomed, Ireland). Following each bolus, an intravenous push of 20ml of 0.9% NaCl was performed. The parameters of the CARE bolus sequence were determined as follows: TR:500 ms, TE: 1.8 ms, flip angle: 20°, FOV:360 mm, matrix:256x128, NEX:2, acquisition time: 60 secs, sections: 60. Scanning time was 1 sec for each image. After an average of 8-10

sections (according to patient's cardiovascular status) at which the concentration of the contrast material reached appropriate levels in the arcus aorta, coronal FISP 3D sequences were started and 3 consecutive images were obtained. Sequence parameters were: TR/TE: 4.47 ms/1.54 ms, NEX: 1, FA: 25°, sections: 52-56, section thickness: 1.6-1.8 mm, distance: 0.2 mm, FOV: 35x35 cm, matrix: 512 x 193, imaging time:18 secs, Voxel volume: 1.6 x 0.7 x 1.7 mm. Breath-holding was not used. Re-format images were prepared using the initial arterial phase images. Firstly, non-contrast images were digitally subtracted from the contrast images; thus, static tissues were removed from vascular structures and subtraction images were obtained. Next, coronal reconstruction images of the supraaortic arteries were obtained via the MIP technique. Finally, axial plane reconstruction images were obtained from subtraction images via the MPR technique. Axial MPR images were produced from coronal subtraction images with the following parameters: section thickness: 1.6mm, intersection distance: 0.016mm. Although final results varied from patient to patient, 130-155 sections were generated for each patient.

### ***Conventional angiography***

Conventional DSA was performed with femoral catheterization and digital subtraction technique (Multistar Top, Siemens Medical Systems). After arcus aorta images were obtained, the catheter was advanced to the arcus aorta with the help of a guidewire. Selective catheterization of the main carotid artery was performed and anteroposterior, lateral and bilateral oblique (+45° and -45°) images of each catheterization were obtained after checking positional correctness with test-injection of contrast (iohexol, Omnipaque 300; Nycomed, Ireland). Conventional DSA was performed with FOV: 33 cm and matrix: 1024x1024. Spatial resolution was 0.32x0.32 mm.

### ***Image analysis***

To evaluate the degree of stenosis, contrast enhanced 3D MRA subtraction images, axial MPR and coronal MIP reconstruction images of all patients were transferred to the computer environment (Leonardo, Siemens Medical Systems). Two separate radiologists independently assessed both subclavian arteries, ½ distal and ½ proximal main carotid arteries, ½ distal and ½ proximal internal carotid arteries, both external carotid arteries and ½ distal and ½ proximal vertebral arteries, without knowledge of conventional DSA results. Conventional DSA was accepted as the gold standard. Stenosis grade was calculated using the formula  $(1-N/D) \times 100$ .<sup>11</sup> According to NASCET criteria and the degree of occlusion was classified as follows: occluded (100%), severe stenosis (70-99%), moderate stenosis (30%-69%) and mild stenosis (between 1% and 29%).<sup>12</sup> Segments in which loss of signal was seen at the level of stenosis but with signs of distal flow, occlusion was accepted to be

99%; while segments which showed total loss of signal throughout the artery were accepted as occluded (100%). Stenoses were evaluated at the same level (of the artery) in both conventional DSA and contrast enhanced 3D MRA.

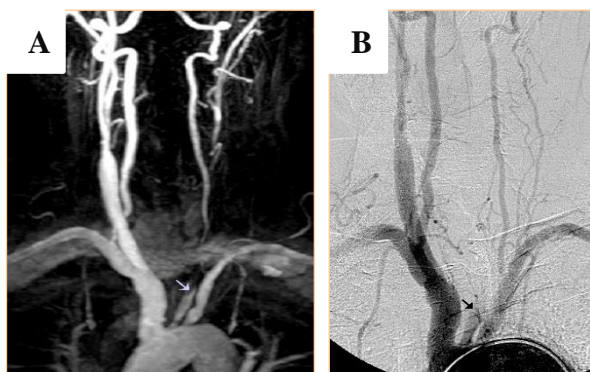
**Statistical analysis**

The data were analyzed using SPSS (v20) statistical package program. The compatibility of all imaging data was analyzed using kappa correlation analysis. Sensitivity, specificity, positive predictive value (PPD), negative predictive value (NPD) were assessed for each segment using conventional 3D DSA as the reference method. P <0.05 was used for statistical significance.

**RESULTS**

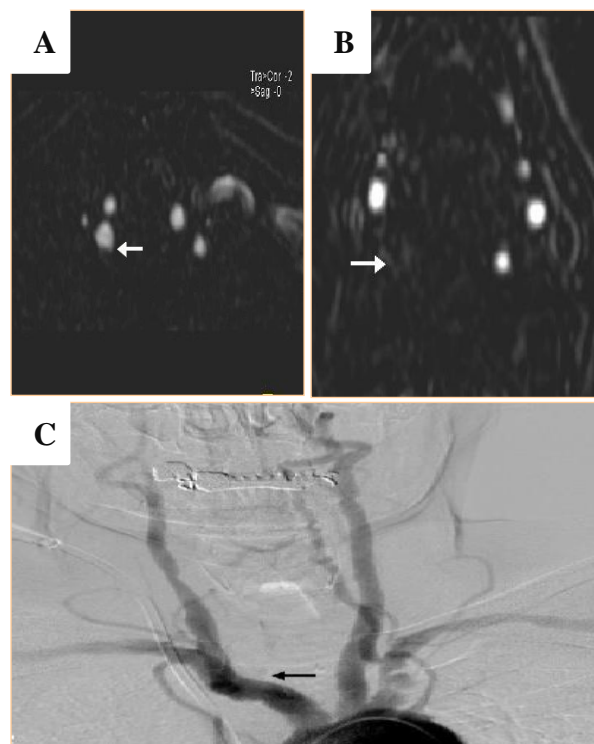
In the current study, 333 arteries of 21 patients (3 females and 18 males, mean age: 71 (range: 48-83)) were evaluated. Results of the conventional DSA analysis indicated total occlusion in 9 (2.7%), severe stenosis in 16 (4.8%), moderate stenosis in 90 (27.1%), mild stenosis in 105 (31.5%) and no stenosis in 113 (33.9%) arteries.

In comparison, with coronal MIP reconstruction of contrast enhanced 3D MRA images, we found 9 (2.7%) total, 25 (7.5%) severe, 78 (23.4%) moderate, 92 (27.6%) mild stenoses while 129 (38.7%) arteries were normal (Figure 1). MIP reconstruction images had a sensitivity of 85%, specificity of 75.6%, accuracy of 81%, PPV of 84%, NPV of 76.7%, false positive ratio of 26.4%, false negative ratio of 15%, and the overall prevalence of stenosis was found to be 59%. In terms of  $\kappa$  coefficients, values were as follows: 0.637 for common carotid, 0.735 for internal carotid, 0.672 for external carotid, 0.729 for subclavian, 0.765 for vertebral arteries, and overall  $\kappa$  (all arteries) was 0.722. When the MIP reconstruction images of 3D MRA were compared with the conventional DSA method according to the Landis and Koch scale, we found a strong relationship between the two methods, demonstrated by high overall and individual  $\kappa$  coefficients.<sup>13</sup>



**Figure 1: Total occlusion of the left common carotid artery on MIP reconstruction (A) and conventional DSA (B).**

With the 3D MRA axial MPR method, 9 arteries were considered as occluded (Figure 2), 8 arteries showed severe, 39 arteries showed moderate, 117 arteries showed mild stenosis; while 160 arteries were considered to be normal. MPR images had a sensitivity of 68%, specificity of 92.4%, accuracy of 76.6%, PPV of 95%, NPV of 60.5%, false positive ratio of 6%, false negative ratio of 33%, and the overall prevalence of stenosis was found to be 64.8%. According to Kappa correlation analysis, the  $\kappa$  values for the MPR method were as follows: 0.705 for common carotid, 0.578 for internal carotid, 0.786 for external carotid, 0.527 for vertebral arteries, with an overall  $\kappa$ = 0.653. Kappa value was not calculated for the subclavian artery, because no significant stenoses were determined with the MPR method. Comparison of the MPR method with the conventional DSA method according to the Landis and Koch scale showed that there existed a significant correlation between the two methods demonstrated by high overall  $\kappa$  coefficients.<sup>13</sup>



**Figure 2: Contrast enhanced 3D MRA axial MPR images of the origin (A) and distal cervical level (B) of the right vertebral artery suggests occlusion. The conventional DSA image (C) of the same case shows occlusion at the origin of the artery.**

Subtraction images of contrast enhanced 3D MRA images detected total occlusion in 13 arteries, severe stenosis in 10 arteries, moderate stenosis in 58 arteries, mild stenosis in 100 arteries, while 152 arteries were considered as normal. Subtraction images demonstrated a sensitivity of 72%, specificity of 82.6%, accuracy of 75.9%, PPV of 87%, NPV of 64.4%, false positive ratio of 17%, false negative ratio of 28%, while the overall prevalence of stenosis was determined as 61.8% with this

method. The Kappa coefficients of subtraction images were determined as: 0.597 for the internal carotid, 0.661 for the external carotid, 0.588 for the subclavian and 0.620 for the vertebral artery. Overall  $\kappa$  was 0.653.

The Kappa correlation analysis showed that the coronal MIP reconstruction method yielded better results compared to the other two methods. While the  $\kappa$  values of all methods were high which demonstrated strong relationships with the DSA method; the  $\kappa$  coefficient, sensitivity and accuracy of the coronal MIP

reconstruction method was higher than that of other methods. When segments were analyzed individually, the coronal MIP reconstruction had the highest kappa values for internal carotid, subclavian and vertebral arteries (0.735, 0.729 and 0.765; respectively); while the axial MPR method had the highest kappa values for common carotid (0.705) and external carotid (0.786) arteries. It was found that the subtraction method did not yield better results in any of the individual comparisons. Overall and individual values of sensitivity, specificity, accuracy, PPV, NPV and the  $\kappa$  coefficients of all methods are depicted in Table 1.

**Table 1: Overall and individual values of sensitivity, specificity, accuracy, PPV, NPV and the  $\kappa$  coefficients of each method.**

	Sens (%)	Spec (%)	PPV (%)	NPV (%)	Accuracy (%)	$\kappa$
<b>Supra-aortic arteries (overall)</b>						
MIP reconstruction	85.0	75.6	84.0	76.7	81.0	0.722
Axial MPR	68.0	92.4	95.0	60.5	76.6	0.653
Subtraction images	72.0	82.6	87.0	64.4	75.9	0.653
<b>Common carotid artery</b>						
MIP reconstruction	74.0	85.0	85.0	74.0	79.0	0.637
Axial MPR	78.0	91.6	93.0	75.0	83.7	0.705
Subtraction images	75.0	91.8	92.5	73.9	82.5	–
<b>Internal carotid artery</b>						
MIP reconstruction	82.5	75.0	89.0	62.0	80.0	0.735
Axial MPR	62.0	90.5	95.0	43.1	68.9	0.578
Subtraction images	65.0	86.4	93.0	45.2	88.4	0.597
<b>External carotid artery</b>						
MIP reconstruction	100	57.0	70.0	100	78.0	0.672
Axial MPR	80.7	93.7	95.4	75.0	52.3	0.786
Subtraction images	83.3	66.6	76.9	75.0	76.1	0.661
<b>Subclavian artery</b>						
MIP reconstruction	84.3	80	93.0	61.5	83.3	0.729
Axial MPR	75.0	100	100	55.0	80.9	–
Subtraction images	76.6	75.0	88.4	56.0	76.1	0.588
<b>Vertebral artery</b>						
MIP reconstruction	94.4	75.0	77.0	93.7	84.0	0.765
Axial MPR	50.0	94.1	91.0	60.4	69.7	0.527
Subtraction images	84.3	81.6	78.8	72.0	75.0	0.620

## DISCUSSION

In recent years, 3D MRA and multi-section CT angiography have become important methods in the diagnosis of supra-aortic artery stenoses.<sup>14,15</sup> Primary advantages of the 3D MRA method may be listed as: good spatial resolution, visualization of a large area from the arcus aorta to the willis polygon, the absence of signal loss due to slow or turbulent flow and also the absence of imaging artifacts caused by patient movements. These advantages ensure accurate determination of the degree of stenosis which is crucial for clinical approach.<sup>16</sup>

Coronal MIP reconstruction is the most frequently used method of evaluating 3D MRA imaging. In the current study, images obtained from artery segments were utilized via a method known as subvolume MIP reconstruction. The inner surface of arteries are revealed to a better degree and vascular superpositioning which prevents accurate analysis of stenotic lesions is prevented by reconstruction with smaller segments from source images.<sup>9</sup> Although contrast enhanced 3D MRA imaging was performed without breath-hold in the current study, the accuracy of results regarding the subclavian and vertebral arteries in which respiratory movements are

expected to cause artifacts were higher than the results of other arteries. Additionally, the Kappa values of these arteries were higher than that of other arteries.

Among supraaortic arteries, the carotid bifurcation and the internal carotid artery are of significant importance due to their association with cerebrovascular events. Contrast enhanced 3D MRA has been shown to have high sensitivity and specificity for the determination of stenoses and occlusions of the internal carotid artery.<sup>17,18</sup> Accurate determination of the degree of stenosis at the carotid bifurcation and/or the internal carotid artery is crucial for treatment approach. Our study has shown that, the coronal subvolume MIP reconstruction method is more successful compared to the axial MPR and subtraction methods.

The higher correlation between coronal MIP reconstruction and DSA results in the current study may be explained by the utilization of subvolume MIP reconstruction for evaluation. In the current study, source images were divided into 6 subsegments and reconstructed, the resulting subvolume MIP reconstruction images were used for evaluation. It is known that this method increases the sensitivity and accuracy of the method by preventing vascular superpositioning which causes difficulties in the evaluation of coronal MIP images. However, with this method, source images have to be evaluated individually which takes time and may be cumbersome for practical use.<sup>19</sup>

With the MIP reconstruction of 3D MRA images, we found 8 moderate and 3 severe stenoses among the 113 segments determined to be normal by conventional DSA. This may be due to the loss of data in MIP reconstruction (compared to source images), which causes over-estimation of stenosis degree.<sup>1,9</sup> This over-estimation was shown in another study; however, the authors also reported that the accuracy of MIP reconstruction could compete with CT angiography and DSA.<sup>20</sup> Another important point is the fact that only pixels with the highest signal intensities are utilized in MIP reconstruction, this may cause the method to be inadequate in terms of evaluating very fine calibrated vascular structures which show relatively low signal intensity, due to partial volume effects.<sup>19,21</sup> According to our results, over-estimation of the degree of stenosis is a rare occurrence in axial MPR and subtraction images, compared to coronal MIP reconstruction.

The results of our study suggest that, in patients with an initial diagnosis of supraaortic artery stenosis, the coronal MIP reconstruction method (due to its higher  $\kappa$ :0.722 value) may be used as the initial diagnostic test, especially when the inherent characteristics of the conventional DSA method are considered. The coronal MIP reconstruction method outperforms the other two methods in the detection of moderate and severe stenoses.

If the degree of stenosis is taken out of the equation, axial MPR images are superior to the other two methods in the evaluation of common carotid and external carotid arteries, which is demonstrated by higher correlation with the conventional DSA method. When the degree of stenosis is included in the evaluation, it may be beneficial to combine coronal MIP reconstruction images with axial MPR images for optimal diagnosis in these arteries. Additionally, in 3D MRA imaging, jugular vein superpositioning due to venous contrast material and tortuosity of supraaortic arteries may complicate evaluation. In the event of such problems, inclusion of axial MPR images may be beneficial for diagnosis. However, a better approach would be to determine imaging requirements on a case-by-case basis.

According to our study, the results obtained from the subtraction images of 3D MRA were significantly correlated with the results of conventional DSA results; however,  $\kappa$  coefficients were lower than the other two methods. Although combining subtraction images with MIP reconstruction may increase diagnostic accuracy, our results suggest that MIP reconstruction images alone may be sufficient for accurate diagnosis.

## CONCLUSION

According to our results, reconstruction and post-processing methods such as coronal MIP reconstruction, axial MPR and MRA subtraction demonstrate high correlations with the conventional DSA method in terms of identifying supra-aortic artery stenoses. However, results of the coronal MIP reconstruction method showed higher correlation with conventional DSA results compared to the other two methods and may be used as an accurate first-line diagnostic method for supra-aortic artery stenoses.

*Funding: No funding sources*

*Conflict of interest: None declared*

*Ethical approval: The study was approved by the Institutional Ethics Committee*

## REFERENCES

1. Wetzel S, Bongartz G. MR angiography: supra-aortic vessels. *European radiology.* 1999;9(7):1277-84.
2. Krings T, Hans F. New developments in MRA: time-resolved MRA. *Neuroradiol.* 2004;46(2):s214-s22.
3. Lee YJ, Laub G, Jung SL, Yoo WJ, Kim YJ, Ahn KJ, et al. Low-dose 3D time-resolved magnetic resonance angiography (MRA) of the supraaortic arteries: Correlation with high spatial resolution 3D contrast-enhanced MRA. *J Magnetic Resonance Imaging.* 2011;33(1):71-6.
4. Lim R, Shapiro M, Wang E, Law M, Babb J, Rueff L, et al. 3D time-resolved MR angiography (MRA) of the carotid arteries with time-resolved imaging

- with stochastic trajectories: comparison with 3D contrast-enhanced Bolus-Chase MRA and 3D time-of-flight MRA. *Am J Neuroradiol.* 2008;29(10):1847-54.
5. Thiex R, Norbash A, Frerichs K. The safety of dedicated-team catheter-based diagnostic cerebral angiography in the era of advanced noninvasive imaging. *Am J Neuroradiol.* 2010;31(2):230-4.
  6. Randoux B, Marro Ba, Koskas F, Duyme M, Sahel M, Zouaoui A, et al. Carotid artery stenosis: prospective comparison of CT, three-dimensional gadolinium-enhanced MR, and conventional angiography. *Radiology.* 2001;220(1):179-85.
  7. Borisch I, Horn M, Butz B, Zorger N, Draganski B, Hoelscher T, et al. Preoperative evaluation of carotid artery stenosis: comparison of contrast-enhanced MR angiography and duplex sonography with digital subtraction angiography. *Am J Neuroradiol.* 2003;24(6):1117-22.
  8. Friese S, Krapf H, Fetter M, Klose U, Skalej M, Küker W. Ultrasonography and contrast-enhanced MRA in ICA-stenosis: is conventional angiography obsolete? *J Neurol.* 2001;248(6):506-13.
  9. Leclerc X, Gauvrit J, Nicol L, Pruvo J. Contrast-enhanced MR angiography of the craniocervical vessels: a review. *Neuroradiol.* 1999;41(12):867-74.
  10. Kim JK, Farb RI, Wright GA. Test bolus examination in the carotid artery at dynamic gadolinium-enhanced MR angiography. *Radiology.* 1998;206(1):283-9.
  11. Staikov IN, Arnold M, Mattle H, Remonda L, Sturzenegger M, Baumgartner RW, et al. Comparison of the ECST, CC, and NASCET grading methods and ultrasound for assessing carotid stenosis. *J Neurology.* 2000;247(9):681-6.
  12. Collaborators NASCET. Beneficial effect of carotid endarterectomy in symptomatic patients with high-grade carotid stenosis. *New England J Medicine.* 1991;325(7):445-53.
  13. Landis JR, Koch GG. The measurement of observer agreement for categorical data. *biometrics.* 1977:159-74.
  14. Balcı Y, Yıldız A, Özgür A, Yılmaz A, Kara E. Ekstrakraniyal Karotis ve Vertebral Arter Darlıklarında 64 Kesitli BT Anjiyografi ile DSA Bulgularının Karşılaştırılması. 2014.
  15. Bak S, Roh H, Moon W-J, Choi J, An H. Appropriate Minimal Dose of Gadobutrol for 3D Time-Resolved MRA of the Supra-Aortic Arteries: Comparison with Conventional Single-Phase High-Resolution 3D Contrast-Enhanced MRA. *Am J Neuroradiol.* 2017;38(7):1383-90.
  16. Remonda L, Senn P, Barth A, Arnold M, Lövblad K-O, Schroth G. Contrast-enhanced 3D MR angiography of the carotid artery: comparison with conventional digital subtraction angiography. *Am J Neuroradiol.* 2002;23(2):213-9.
  17. Weber J, Veith P, Jung B, Ihorst G, Moske-Eick O, Meckel S, et al. MR angiography at 3 Tesla to assess proximal internal carotid artery stenoses: contrast-enhanced or 3D time-of-flight MR angiography? *Clin Neuroradiol.* 2015;25(1):41-8.
  18. Gökçe E. İnternal Karotid Arter Darlıklarında Time-Resolved Kontrastlı Manyetik Rezonans Anjiyografi ve Dijital Substraksiyon Anjiyografinin Karşılaştırılması. *J Contemporary Med.* 2017;7(3):208-16.
  19. Choyke PL, Yim P, Marcos H, Ho VB, Mullick R, Summers RM. Hepatic MR angiography: a multiobserver comparison of visualization methods. *American J Roentgenology.* 2001;176(2):465-70.
  20. Warach S, Baird AE, Dani KA, Wintermark M, Kidwell CS. Magnetic resonance imaging of cerebrovascular diseases. *Stroke: Elsevier Inc.* 2011.
  21. Anderson CM, Saloner D, Tsuruda JS, Shapeero LG, Lee RE. Artifacts in maximum-intensity-projection display of MR angiograms. *AJR Am J Roentgenol.* 1990;154(3):623-9.

**Cite this article as:** Aydin H, Agildere AM. Diagnosis of supra-aortic artery stenosis: comparison of magnetic resonance angiography imaging methods with conventional digital subtraction angiography. *Int J Res Med Sci* 2018;6:1509-14.