

Original Research Article

Anatomical study of nutrient foramen in lower limb dry long bones

Samyog Mahat*, Shamsheer Shrestha, Prabhakar Yadav

Department of Human Anatomy, B. P. Koirala Institute of Health Sciences, Dharan, Nepal

Received: 08 June 2021

Revised: 06 July 2021

Accepted: 07 July 2021

***Correspondence:**

Dr. Samyog Mahat,

E-mail: samyoganatomy@gmail.com

Copyright: © the author(s), publisher and licensee Medip Academy. This is an open-access article distributed under the terms of the Creative Commons Attribution Non-Commercial License, which permits unrestricted non-commercial use, distribution, and reproduction in any medium, provided the original work is properly cited.

ABSTRACT

Background: Nutrient artery gain access through nutrient foramen and provide vascular supply to bone. Number, size and location of nutrient foramen has significant medical as well as surgical importance. Any insult to nutrient artery during surgical procedure or during trauma may lead to devascularization or poor prognosis.

Methods: The present study consist of 50 femurs, 50 tibia and 50 fibula, collected from department of anatomy, BPKIHS. Mean length of bone, number, position and size and foraminal index of nutrient foramen was observed and recorded accordingly.

Results: In femur 62% bone shows single nutrient foramen. Nutrient foramen was commonly located in medial lip of linea aspera and in upper third of bone which was noted in 80% of bone. In tibia 82% of total bone shows single foramen with absent of foramen in 6% bone. Foramen was commonly located above the soleal line and middle third of bone which was noted in 56% of bone. In fibula 6% of total bone shows absent of nutrient foramen and majority of bone shows single nutrient foramen (82%). Foramen was commonly located in lower part of posterior surface (60%) and in middle third of bone.

Conclusions: This study provides details topographic knowledge about nutrient foramen which is important clinically for proper planning of surgery and its outcome.

Keywords: Nutrient foramen, Foraminal index, Lower limb

INTRODUCTION

Growth and repair of bone is dependent on their vascularization.¹ Nutrition to long bone is mainly provided by nutrient artery especially during active growing period and early phase of ossification.² Nutrient artery enter the bone through small cavity in diaphysis called nutrient foramen which follows the rule 'towards the elbow I go, from the knee I flee.'^{2,3} Nutrient foramen in located away from growing end of bone due to differential growth of two ends of long bone.^{4,5} Nutrient foramen carrying nutrient artery leads into canal and opens into marrow cavity.⁶ Within the marrow it divides into sinusoids and forms small vessels that ramifies through cortex supplying spongy bone and bone marrow.⁷ Nutrient foramen has

fixed position for each bone but position and number may vary. In femur nutrient foramen lies in Linea aspera, directed proximally. In tibia present around Soleal line and in fibula foramen is present midpoint of posterior surface, directed distally. The absence of nutrient foramina in long bones is well known.^{8,9}

It was reported that in instances where the nutrient foramen is absent, the bone is likely to be supplied by periosteal arteries.^{9,10} Precise knowledge of nutrient foramen in long bone is essential in some of the operative procedures to prevent intraoperative damage to the nutrient artery.¹¹ The knowledge of location of nutrient foramen is important in differentiating fracture line from nutrient foramen. Nutrient foramen can be confused or mimic the

longitudinal stress fracture on radiography.^{12,13} The nutrient foramen is distinguished from any other foramen by the presence of distinct vascular groove outside the nutrient foramen.¹⁴ In mandibular reconstruction as well as dental implants have been using the vascularized fibular grafts.¹⁵ Therefore anatomical morphology of nutrient foramen is essential for the clinician who is involved in vascular graft procedures.⁹

The aim of the study was to determine the morphology and topographic anatomy of dry adult long bones of lower limbs.

METHODS

The study is descriptive cross-sectional study. Study was carried at department of human anatomy, B.P. Koirala Institute of Health Sciences from June 2020 to December 2020. Study on morphology of nutrient artery was conducted in adult lower limb long bone consisting of femur, tibia and fibula. Bones examined were obtained from osteology section, department of human anatomy, BPKIHS. Sex and age characteristic of the bone were not determined. Clean, dry and fully ossified bone were included in the study. Bone with any sign of fracture and deformities were excluded from the study. Following instruments was used in the study- (a) vernier caliper; (b) 18, 21, 23 and 24 gauge hypodermic needle; (c) magnifying lens; (d) osteometric board; and (e) measuring scale ruler

Following parameters were observed after side determination of all bones-

Total length of bone

With the help of osteometric board and measuring scale the maximal length of bone from proximal aspect to distal end of the bone was measured and was recorded in millimetre. After recording the measurement of bone, mean range of total length was obtained

Total number of nutrient foramen

Nutrient foramen were identified by presence of well-marked groove leading to a well-marked canal and raised edge of foramen. The patency of the foramen was confirmed by passing fine wire through the canal. With the help of hand lens number of nutrient foramen was observed and recorded accordingly by simple counting. Only well-defined canal on diaphysis was observed

Location of nutrient foramen

All the borders and surfaces were thoroughly and closely inspected for presence of nutrient foramen. Location of nutrient foramen was recorded in relation to nearby anatomical structure of bones.

Foramina within 1 mm from any border were considered to be lying on that border of the bone. Location of nutrient foramen in proximal, middle and distal part of shaft of bones were recorded using Hughes formula:

$$FI = \frac{D}{L} \times 100$$

where, FI= foraminal index, L= total length of the bone, D- distance of the foramen from the proximal end.¹⁶ (a) FI less than 33.33mm the nutrient foramen was in the proximal third of the bone (FI I); and (b) FI from 33.33mm to 66.66mm the nutrient foramen was in the middle third of the bone (FI II); and (c) FI greater than 66.66mm the nutrient foramen was in the distal third of the bone (FI III).

Size of the foramen

Hypodermic needle of various size was used to measure the size of foramen. Size of the foramen was considered as large, medium and small sized according to gauge of the hypodermic needle.¹⁷ (a) size of the 18-gauge needle was considered to be between 1.27 mm or more and was considered as large sized foramen; (b) size of the 20-gauge needle was considered to be between 0.90 mm and 1.27 mm; (c) size of the 22-gauge needle was considered to be between 0.71 mm and 0.90 mm; (d) size of the 24-gauge needle was considered to be between 0.55 mm and 0.71mm. If 20-22 gauge needle passes through the foramen, then it was called as medium size. Small sized foramen was considered if 24-gauge needle passes through the foramen satisfactorily.

Both large and medium size foramen was also classified as dominant while small sized foramen as accessory foramen. Prior to the study, ethical permission was taken from Institute Review Committee (IRC), BPKIHS. Statistical Package for Social Science (IBM SPSS Corp.; Armonk, NY, USA) for Windows v.18.0 program was used for statistical evaluation. Descriptive statistical parameters were calculated. Descriptive statistics as number, percentage and mean were used for data analysis and calculated.

RESULTS

In this study, total of 150 dry adult lower limb long bone were examined including 50 femur, 50 tibia and 50 fibula.

Femur

The total length of femur ranged from 385 mm-478 mm and average or mean length of femur was found to be 393.20 mm on right sided and 421 mm on left sided femur (Table 1). Of 50 femur, single nutrient was observed in 62%, double nutrient foramen in 20%, triple nutrient foramen was observed in 12% bone and foramen was absent in 6% of femur (Table 2). Foramen was mostly located on medial lip of Linea aspera (Table 2). The

distribution of size of foramen and foraminal index of femur is represented in Table 5 and Figure 2.

Tibia

In examined tibia, mean length was found to be 343.86 mm on right sided tibia and 350 mm on left sided tibia. 82% tibia shows single nutrient foramen, double nutrient was seen in 12% tibia and foramen was absent in 6% of total tibia. 54% of total foramen was observed above soleal line in posterior surface of tibia (Table 3). The distribution of foraminal size and foraminal index is shown in Table 5 and Figure 2.

Fibula

Out of 50 fibula, single nutrient foramen was observed in 82% of bone, double nutrient foramen observed in 12% and nutrient foramen was absent in 6% of total foramen observed in fibula (Table 4). The average mean length of fibula recorded was 345 mm on right side and 344 mm on left side. 30% of total foramen was located on upper part of posterior surface of fibula (Table 4). Foramen size and foraminal index distribution is represented on Table 5 and Figure 2. The distribution of number of foramen of all lower limb bone is shown in Figure 1.

Table 1: Mean length of lower limb long bones.

Bone	No. of bones		Mean length (mm)		SD	
	Right	Left	Right	Left	Right	Left
Femur	30	20	393.20	421.0	13.91	87.34
Tibia	28	22	343.86	350.0	24.84	22.79
Fibula	35	15	345.0	344.0	8.1	15.2

Table 2: No. of foramen and location of foramen in femur.

No. of foramen	No. of bone				Location of foramen*						
	Right	%	Left	%	2LA	ML	LL	AS	MS	LS	PS
0	3	10	0	0							
1	20	66.7	11	55	7	18	14	04	03	02	02
2	05	16.7	5	25							
3	02	6.7	4	20							
Percentage (%)					14	36	28	08	06	04	04

Note: *2LA: between 2 lips of Linea aspera, ML: Medial lip of Linea aspera, LL: Lateral lip of Linea aspera, AS: Anterior surface, MS: Medial surface, LS: Lateral surface, PS: Popliteal surface.

Table 3: No. of foramen and location of foramen in tibia.

No. of foramen	No. of bone				Location of foramen*					
	Right	%	Left	%	SLA	IB	AB	SLB	MS	
0	02	5.3	01	4.5						
1	23	82.1	18	81.8	27	04	04	13	02	
2	03	10.7	03	13.6						
3	0	0	0	0						
Percentage (%)					54	8	8	26	04	

Note: *SLA: Above Soleal line, IB: Interosseous border, SLB: Below Soleal line, AB: Anterior border, MS: Medial surface.

Table 4: No. of foramen and location of foramen in fibula.

No. of foramen	No. of bone				Location of foramen*				
	Right	%	Left	%	AS	IB	MS	PSU	PSL
0	02	5.71	01	6.6					
1	29	82.5	12	80	-	-	05	15	30
2	04	11.4	02	13.3					
3	-		-						
Percentage (%)							10	30	60

Note: AS: Anterior surface; IB: Interosseous border; MS: Medial surface; PSU: Posterior surface upper part, PSL: Posterior surface lower part.

Table 5: The size of the foramen of lower limb long bones.

Size of foramen (mm)	Femur		Tibia		Fibula	
	Right (%)	Left (%)	Right (%)	Left (%)	Right (%)	Left (%)
≥1.27	7.8	10	3.5	5.8	-	-
≥0.90 to <1.27	7.8	6.7	5.8	1.8	7.1	-
≥0.71 to <0.90	25.5	21.1	10.6	8.2	17.1	15.2
≥0.55 to <0.71	12.2	8.9	37.6	27.1	23.9	27.1

Note: ≥1.27: large sized foramen; ≥0.90 mm and <1.27 mm: medium sized foramen; ≥0.71 mm and <0.90 mm: medium sized foramen; ≥0.55 mm and <0.71mm: small sized foramen.

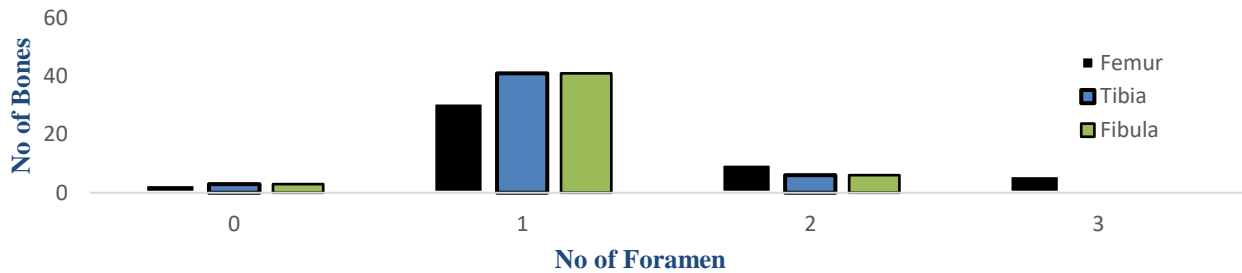


Figure 1: Showing the distribution of no. of foramen in lower limb long bone.

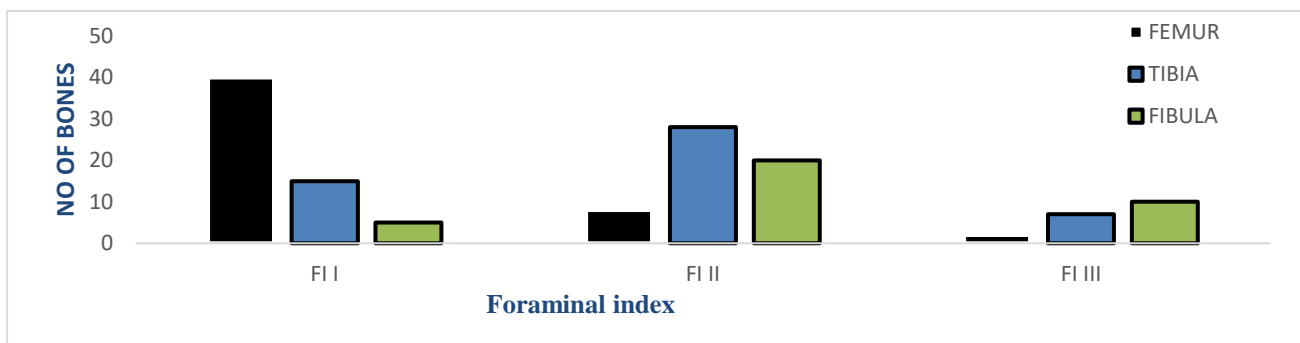


Figure 2: Showing foraminal index of lower limb long bones.

DISCUSSION

Clinical knowledge of the size, number and location of nutrient foramen is important as it may differ in growing and non-growing end of the long bone and procedures such as joint replacement therapy, fracture repair, bone grafts and vascularized bone microsurgery.^{2,18} One of the predisposing factor for malunion or non-union is the accidental manipulation or injury to nutrient artery providing nutrition to long bones. Healing of fracture mainly depends on bone vasculature.¹⁹

Femur

Our study showed that most of the nutrient foramina presented on posterior surfaces of the femur, although other surfaces of femur also shows presence of foramen indicating nutrient foramen can vary with location. Previous research by Sedemir et al shows similar outcome.²⁰ However study done by Shrestha et al, Oyedun et al and Seema et al shows all the foramen located on posterior surface of femur.^{5,6,21} In Present study majority

of the foramen shows foraminal index I (FI I) indicating high percentage of foramen located on upper third of bone. Previous study carried by Poornima et al also shows similar result.²² However study done by Pragya et al and Seema et al shows majority of foramen on middle third of bone.^{6,21} In present study mean total length of femur is 392.2 mm (right) and 421 mm (left) which is similar to the result obtained by Krischner et al and Kizilkanat et al.^{23,24} Present study shows most of the femur having one nutrient which was similar to study conducted by vinay et al and Mazengeny et al.^{25,26} However present study shows 6% of bone with no foramen which was contrast with the study conducted by Pragya et al which shows no absence of foramen.⁶

Tibia

Present study shows majority of bone had single foramen and in 6% foramen was absent which is similar to report of KU Prashant et al (98.6%) and Pereira et al (98.6%).^{9,27} Report from Seema et al and Gumusburun et al shows presence of three foramen and no absence of foramen from

study done by Swapna et al and Seema et al.^{2,21,28} In present study as determined by foraminal index, majority of foramen was present in upper third of bone which was similar to study carried by Mazenganya et al.²⁶ However study done by Kazilkant et al and Mohan et al shows majority of foramen on middle third of bone.^{23,29} Majority of foramen was located above the Soleal line in present study. This result was accordance with Hari et al and Tejwasi et al.^{30,31} However study carried by Seema et al shows majority of foramen under Soleal line.²¹

Fibula

Present study shows majority of bones with single foramen which was similar to study carried by Sharma et al and Seema et al.^{3,21} Multiple foramen was absent in Prashant et al study result whereas present study shows maximum of two foramen.⁹ Present study shows absence of foramen (14.3%) which differs with study done by Singha et al and Pereira et al which shows no absence of foramen.^{27,32} The mean length of fibula on present study shows 345 mm on right and 344 mm on left side which was similar to the study done by Ambekar et al.² Present study shows foramen commonly location on upper part of posterior surface which correspond with the study conducted by Jayprakash et al.³³ However study done by Campos et al and Sendemir et al shows foramen commonly located in medial surface of fibula.^{10,20} Foramen was commonly located at middle third of bone in present study which correspond with study done by Prashanth et al.⁹

CONCLUSION

The knowledge of topographic morphology of the nutrient foramina of long bones of lower limb will guide during any fracture repair surgeries, tumour resection and also during bone grafting surgeries for preserving the nutrition to the bone as any fracture near foramen can cause poor prognosis.

Regarding limitations of study, a greater number of bones could have been included in the study. Sex and age determinations of the bones could have been included in the study.

ACKNOWLEDGEMENTS

I would like to express my gratitude to all the staffs of Department of Human Anatomy for their support.

Funding: No funding sources

Conflict of interest: None declared

Ethical approval: The study was approved by the Institutional Ethics Committee

REFERENCES

1. Krishna SM, Kumar PU. Morphologic and Morphometric Study of the Nutrient Foramina in Dry

- Human Femur Bones of Telangana Region. Int J Anat Res. 2016;4(2):2464-8.
2. Ambekar SA, Sukre SB. Diaphyseal Nutrient Foramen of Lower Limb Long Bones: Variations and Importance. Int J Anat Res. 2016;4(3):2684-8.
3. Sharma M, Prashar R, Sharma T, Wadhwa A, Kaur J. Morphological Variations of Nutrient Foramina in Lower Limb Long Bones. Int J Med Dent Sci. 2015;4(2):802.
4. Mysorekar VR, Nandedkar AN. Diaphysial nutrient foramina in human phalanges. Plast Reconstr Surg. 1980;65(4):542.
5. Oyedun OS. Morphometric study of diaphyseal nutrient foramen in dried Nigerian femurs: Implications for microvascular bone graft. Adv Life Sci Technol. 2014;23:91-7.
6. Shrestha P, Mansur I, Mehta K, Shrestha S. Variations of Nutrient Foramen of Femur and its Clinical Implications. 2019;7(2):5-8.
7. Moore KL, Dalley AF, Agur AMR. Clinically oriented Anatomy: Abdomen. 8th ed. Canada: Wolters Kluwer; 2006: 522-563.
8. Lutken P. Investigation into the position of the nutrient foramina and the direction of the vessel canals in the shafts of the humerus and femur in man. Cells Tissues Organs. 1950;9(1):57-68.
9. Prashanth KU, Murlimanju BV, Prabhu LV, Kumar CG, Pai MM, Dhananjaya KVN. Morphological and topographical anatomy of nutrient foramina in the lower limb long bones and its clinical importance. Australas Med J. 2011;4(10):530-7.
10. Campos FF, Pellico LG, Alias MG, Fernandez VR. A study of the nutrient foramina in human long bones. Surg Radiol Anat. 1987;9(3):251-5.
11. Xue Z, Ding H, Hu C, Xu H, An Z. An anatomical study of the nutrient foramina of the human humeral diaphysis. Med Sci Monit. 2016;22:1637-45.
12. Craig JG, Widman D, Holsbeeck M. Longitudinal stress fracture: Patterns of edema and the importance of the nutrient foramen. Skeletal Radiol. 2003;32(1):22-7.
13. Exhibit S, Saad J, Zrig A, Marrakchi F, Harbi F, Alghamdi S. Longitudinal stress fracture : patterns of edema and the importance of the nutrient foramen in MRI evaluation . Eur Soc Radiol. 2015;1-17.
14. Payton CG. The Position of the Nutrient Foramen and Direction of the Nutrient Canal in the Long Bones of the Madder-Fed Pig. J Anat. 1934;68(4):500-10.
15. Matsuura M, Ohno K, Michi KI, Egawa K. Clinicoanatomic Study on the Craniofacial Bones Used for Cranio- and Maxillofacial Implants. Int J Oral Maxillofac Implant. 2002;17(1):121-9.
16. Hughes H. The factors determining the direction of the canal for the nutrient artery in the long bones of mammals and birds. Acta Anat. 1952;15(3):261-80.
17. Gupta AK, Ambekar MN. Study Of Nutrient Foramina In Adult Human Femur Bones. J Nepalgunj Med Coll. 2018;14(2):44-9.

18. Narasipuram A, Priya KAV, Bindu NH. Morphometric Study of Nutrient Foramen of the Dried Human Tibiae. *Int J Anat Res.* 2019;7(2):6468-73.
19. Chandrasekaran S, Shanthi KC. A study on the nutrient foramina of adult humerii. *J Clin Diagnostic Res.* 2013;7(6):975-7.
20. Sendermir E, Çimen A. Nutrient foramina in the shafts of lower limb long bones: Situation and number. *Surg Radiol Anat.* 1991;13(2):105-8.
21. Seema, Verma P, Mahajan A, Gandhi D. Variation in the Number and Position of Nutrient Foramina of Long Bones of Lower Limb in North Indians. *Int J Anat Res.* 2015;3(4):1505-9.
22. Poornima AA. International Journal of Biomedical Research Epidemiological indicators of Cancer in North Saudi Arabia: A population-based Survey. *Int J Biomed Res.* 2015;6(9):6.
23. Kizilkanat E, Boyan N, Ozsahin ET, Soames R, Oguz O. Location, number and clinical significance of nutrient foramina in human long bones. *Ann Anat.* 2007;189(1):87-95.
24. Kirschner MH, Menck J, Hennerbichler A, Gaber O, Hofmann GO. Importance of arterial blood supply to the femur and tibia for transplantation of vascularized femoral diaphyses and knee joints. *World J Surg.* 1998;22(8):845-52.
25. Vinay G, Gowri SRM. Anatomical study of the nutrient foramen of lower limb long bones in South Indian population. *Indian J Clin Anat Physiol.* 2017;4(2):222-4.
26. Mazenganya P, Fasemore MD. Morphometric studies of the nutrient foramen in lower limb long bones of adult black and white South Africans. *Eur J Anat.* 2015;19(2):155-63.
27. Pereira GAM, Lopes PTC, Santos AMP, Silveira FHS. Nutrient Foramina in the Upper and Lower Limb Long Bones: Morphometric Study in Bones of Southern Brazilian Adults. *Int J Morphol.* 2011;29(2):514-20.
28. Gumusburun E, Yucel F, Ozkan Y, Akgun Z. A study of the nutrient foramina of lower limb long bones. *Surg Radiol Anat.* 1994;16(4):409-12.
29. Mohan K, Devaraj B, Ramanathan S, Rethinasamy M. Morphometric Study of Nutrient Foramen in the Long Bones of Lower Limb. *Int J Anat Res.* 2017;5(2.3):3943-8.
30. Tejaswi HL, Shetty K, Dakshayani KR. Anatomic Study of Nutrient Foramina in the Human Tibiae and Their Clinical Importance. 2014;9(3):334-6.
31. Hari V. Nutrient foramen in tibia- A study in coastal region of Karnataka. *IOSR J Dent Med Sci.* 2013;10(3):75-7.
32. Sinha P, Mishra SR, Kumar P, Gaharwar A, Sushobhana S. Morphology and Topography of Nutrient Foramina in Fibula. *Ann Int Med Dent Res.* 2016;2(6):7-12.
33. Jayaprakash T. Morphologic study of diaphyseal nutrient foramina in dried fibulae and its clinical implications. *Int J Res Med Sci.* 2016;4(9):3887-9

Cite this article as: Mahat S, Shrestha S, Yadav P. Anatomical study of nutrient foramen in lower limb dry long bones. *Int J Res Med Sci* 2021;9:2246-51.