

Case Report

Clinicopathological representation of nonmetastatic Ewing sarcoma of the scapula - a case study

Vinod Kumar A.^{1*}, Ramesh Shankar², Kaviraj Mahadevan³, Susheela M.²

¹Department of Pathology, Cancer institute (W.I.A), Chennai, Tamilnadu- 600036, India

²Department of Cytogenetics, Cancer institute (W.I.A), Chennai, Tamilnadu- 600036, India

³Research Associate, Central Research Lab, Sri Manakula Vinayagar Medical College and Hospital, Pudhucherry, Tamilnadu, India

Received: 29 January 2016

Accepted: 27 February 2016

*Correspondence:

Dr. Vinod Kumar A.,

E-mail: anandhivin@rediffmail.com

Copyright: © the author(s), publisher and licensee Medip Academy. This is an open-access article distributed under the terms of the Creative Commons Attribution Non-Commercial License, which permits unrestricted non-commercial use, distribution, and reproduction in any medium, provided the original work is properly cited.

ABSTRACT

Ewing sarcoma (ES) is a rare type of small cell tumor of the bone and soft tissues. About 50% of ES arise in the femur and pelvis. We present a case of ES of the scapula in a seven year old female child. Because of its similarity with other small cell tumors, the diagnosis of ES is challenging and requires a combination of methods like CT scan, MRI report, histopathological evaluation and IHC, etc. The MRI report of our case has shown a consistent 5×4 cm³ mass on the left scapula. Bone marrow aspiration and biopsy of the tumor has been further analyzed. Small, round and oval cells with densely packed nuclei and scanty cytoplasm, which are characteristic to ES were observed microscopically. A positive reaction to vimentin and CD99 and negative result for the biomarkers meant for other types of tumors, favours the diagnosis of ES. The chromosomes analyzed from the peripheral blood of the patient have shown a normal karyotype. Early diagnosis of ES is very crucial for treatment. Histopathology and IHC are indispensable tools in the diagnosis of ES.

Keywords: ES, Histopathology, IHC, CD99, Karyotype

INTRODUCTION

Ewing sarcoma (ES) is characterized as a small undifferentiated round cell sarcoma which evolves most prominently in bone and rarely occurs in extra skeletal soft tissues.¹ Ewing sarcoma of the bone develops as a primary sarcoma, whereas secondary sarcoma is the one that metastasize to the bone (bone metastases) from other parts of the body. Ewing sarcoma exhibits rapid growth and metastasize on bone and other soft tissues of the body, through blood. Extra skeletal metastasis of ES primarily occurs in lungs.² Ewing sarcoma occurs in children and adults and is most prevalent among people under 30 years with a median age of 20. It occurs predominantly in males than in females.³ The epidemiology of ES has found to be related to race. It is

significantly prevalent in whites and is less among Africans and Asians.⁴ Ewing sarcoma arises as a result of fusion of the oncogene, EWS (Ewing sarcoma) of chromosome 22 with one of the several members of ETS [Ewing tumors] family. The translocation {t (11; 22) (q24; q12)} is the most common which results in the fusion of EWS with FLI1 [friend leukemia intergration 1] of ETS family.⁵ A differential diagnosis with a combination of techniques is required to diagnose ES. Here we present a case featuring non-metastatic primary Ewing sarcoma of the scapula.

CASE REPORT

The patient is a seven year old female with swelling on the left shoulder which gradually increases by time. The

patient doesn't have complaint of pain or pain during shoulder movement. At the time of examination, the patient had no fever, trauma, asthma or epilepsy. The patient was also found to be negative for the clinical conditions, pallor, icterus, clubbing and edema. The patient's appetite, bowel movement, and bladder function was normal with no history of weight loss. Absence of organomegaly and no focal neurological deficit has been reported. Local examination revealed a 5×4 cm mass over the left scapular region. The MRI scan has shown altered signals involving lateral border and body of left scapula.

Histopathology and immunohistochemistry

The bone marrow aspiration and biopsy (1.5 cm) tissue has been processed and examined for malignancy using standard protocols. Typical small round and oval cells with, densely packed nuclei and scanty cytoplasm has been observed microscopically after staining with hemotoxylin and eosin (H&E). The sample has shown positive for CD99, vimentin, and negative for the other biomarkers (Table 1) which concludes the presence of ES.

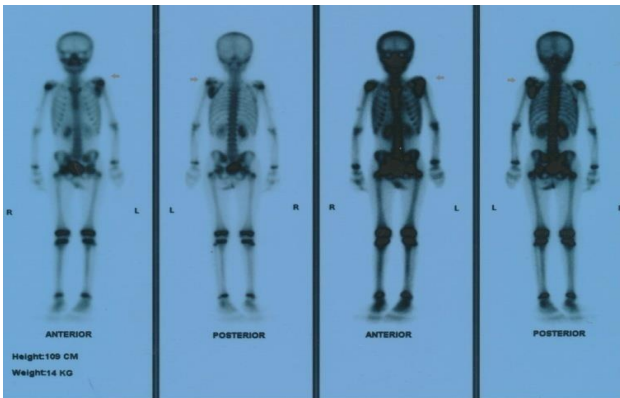

Figure 1: Whole body bone scan showing a mass on the left scapula.

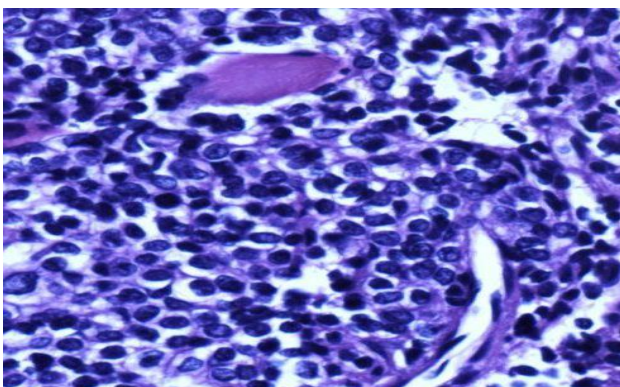


Figure 2: H&E staining- tightly arranged tumor cells with hyperchromatic nuclei and some inconspicuous needle-like osteoid particles magnification X 40.

Table 1: List of biomarkers used.

Biomarker	Result
Keratin	Negative
NSE (neuron specific enolase)	Negative
Synaptophysin	Negative
Chromogranin A	Negative
Vimentin	Positive
CD56	Negative
CD57	Negative
CD 31	Negative
CD 34	Negative
CD99	Positive
KI 67	Negative

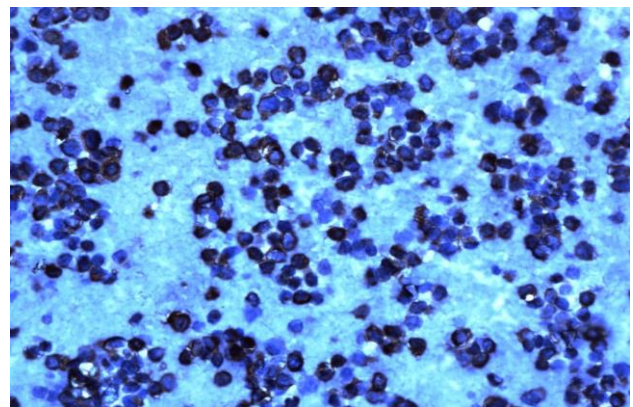


Figure 3: IHC vimentin is more distinct. magnification X 10.

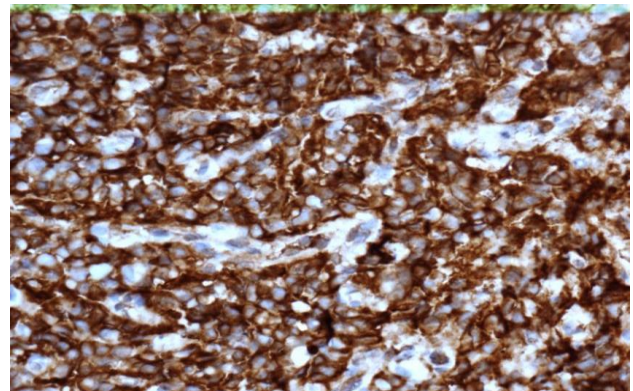


Figure 4: IHC reaction with CD99 is positive. magnification X 40.

Cytogenetics

Peripheral blood sample of the patient was collected and used for chromosomal analysis. The mitotic indices were analysed by G-banding after trypsinization using standard protocol. The peripheral blood of the patient has shown a normal karyotype (Figure 5).

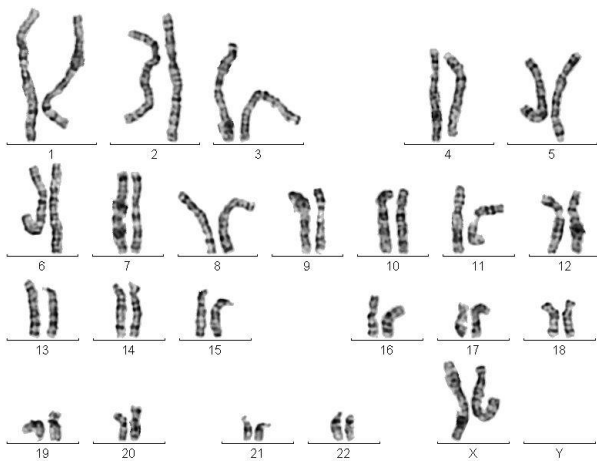


Figure 5: G-banding of the peripheral blood sample showing a normal karyotype.

DISCUSSION

About 50% of ES occurs in the femur and pelvis and ES of scapula is one of the rare cases.⁶ The diagnosis of ES is difficult due to its characteristic similarity with other malignant tumors.⁷ A gradual increase of pain is one of the major symptoms of bone sarcomas.⁸ In the present case, the patient doesn't have a complaint of pain. This may be due to the early stage of the disease condition. A well-defined information of the tumor including its expansion, relation to the adjacent blood vessels, skin, etc., can be obtained by MRI.⁹ Our MRI reports a firm, consistent, non-tender, non-adherent tumor on the left scapula. It has been found that CD99 is expressed on the cell membranes of Ewing sarcoma tumor and is therefore used as an immunohistochemical marker for the diagnosis of Ewing tumors. Vimentin is an intermediate filament (IF) protein which is overexpressed at the time of accelerated tumor growth.¹⁰ In the present study a positive reaction to CD99, vimentin and characteristic small round cell morphology of H&E staining concludes the diagnosis of ES. A negative result to the markers over-expressed by other cancer cells like, CD57 (leukemia, carcinoma etc.), CD56 and chromogranin A (neuroendocrine tumors), keratin (melanoma), neuron specific enolase (NSE) (neuroblastoma, small cell sarcoma of the lung, etc.), CD31 and CD 34 (vascular tumors) Ki67 (breast cancer) synaptophysin (neuroblastoma) is also a diagnostic criteria for ES.⁶ An additional translocation {t (11; 22) (q24; q12)} has been reported in other studies as a supportive data. Due to the non-availability, chromosomal analysis of bone marrow sample is not done in our study. Chromosomal analysis of the peripheral blood is done as a routine process in our institute. A normal karyotype reveals information on the absence of other chromosomal disorders like down syndrome.¹¹

CONCLUSION

Ewing sarcoma is a rare type of bone sarcoma for which a combination of methods are required for clinical diagnosis. Histopathological examination of bone marrow biopsy sample plays a vital role in the definitive diagnosis as it is the quick and reliable method. The limitation of this case study is that the cells of the bone marrow would have been karyotyped as an additional confirmatory test. Early diagnosis of ES and distinguishing it from other small cell tumors facilitates better management of treatment strategies.

ACKNOWLEDGEMENTS

The authors are thankful to the entire faculty and technical staff of department of microbiology and department of surgery, Cancer institute (W.I.A), Chennai, India for their support and co-operation during the entire study.

Funding: No funding sources

Conflict of interest: None declared

Ethical approval: Not required

REFERENCES

1. Gervalmlid L, Enzingemrd FM. Extraskeletal Neoplasm resembling ewing's sarcoma. *Cancer*. 1975;36:240-51.
2. Gopalakrishnan CV, Shrivastava A, Easwer HV, Nair S. Primary Ewing's sarcoma of the spine presenting as acute paraplegia. *J Pediatr Neurosci*. 2012;7(1):64-6.
3. Iwamoto Y. Diagnosis and Treatment of Ewing's Sarcoma. *Jpn J Clin Oncol*. 2007;37(2):79-89.
4. Worch J, Matthay KK, Neuhaus J, Goldsby R, DuBois SG. Ethnic and racial differences in patients with Ewing sarcoma. *Cancer*. 2010;116(4):983-8.
5. Hattinger CM, Potschger U, Tarkkanen M, Squire J, Zielenska M, Kiuru-Kuhlefelt S, et al. Prognostic impact of chromosomal aberrations in Ewing tumours. *British Journal of Cancer*. 2002;86:1763-9.
6. Brazao-Silva MT, Fernandes AV, de Faria PR, Cardoso SV, Loyola AM. Ewing's Sarcoma of the Mandible in a Young Child. *Braz Dent J*. 2010;21(1):74-9.
7. Chakrabarti N, Dewasi N, Das S, Bandyopadhyay A, Bhaduri N. Primary Ewing's Sarcoma/Primitive Neuroectodermal Tumor of Kidney - a Diagnostic Dilemma. *Iran J Cancer Prev*. 2015;2:129-33.
8. Bazzocchi A, Bacci A, Serchi E, Salerno A, Salizzoni E, Leonardi M. Intradural extramedullary Ewing's sarcoma recurrence with acute clinical presentation and literature review. *The Neuroradiology Journal*. 2013;26:476-81.
9. Krishnamani K, Kumar TN, Gandhi LV, Raghunadharao D, Sadashivudu G, Megha U. Primary Ewing's sarcoma of the cranium: Case

series and review of literature. *Journal of Cancer Research and Therapeutics.* 2014;10(2):377-80.

10. Yip C, Hsu S, Chang N, Wang J, Liao W, Chen J, et al. Primary vaginal extrasosseous Ewing sarcoma/primitive neuroectodermal tumor with cranial metastasis. *J Chin Med Assoc.* 2009;72(6):332-5.
11. Casorzo L, Fessia L, Sapino A, Ponzio G, Bussolati G. Extraskeletal Ewing's tumor with translocation t

(11;22) in a patient with down syndrome. *Cancer Genet Cytogenet.* 1989;37:79-84.

Cite this article as: Vinod Kumar A, Shankar R, Mahadevan K, Susheela M. Clinicopathological representation of nonmetastatic Ewing sarcoma of the scapula - a case study. *Int J Res Med Sci* 2016;4:1264-7.