

## Case Report

# An unusual case of malignant mesothelioma mimicking as Fournier's gangrene

Geoffrey E. Sundar<sup>1\*</sup>, Kishan Prasad Hosapatna Laxminarayana<sup>1</sup>,  
Jayaprakash Kubalady Shetty<sup>1</sup>, Lancelot Lobo<sup>2</sup>

<sup>1</sup>Department of Pathology, <sup>2</sup>Department of General Surgery, K. S. Hegde Medical Academy of Nitte, Mangalore, Karnataka, India

**Received:** 30 November 2020

**Accepted:** 06 January 2021

### \*Correspondence:

Dr. Geoffrey E. Sundar,

E-mail: [geoffsundar@gmail.com](mailto:geoffsundar@gmail.com)

**Copyright:** © the author(s), publisher and licensee Medip Academy. This is an open-access article distributed under the terms of the Creative Commons Attribution Non-Commercial License, which permits unrestricted non-commercial use, distribution, and reproduction in any medium, provided the original work is properly cited.

### ABSTRACT

Fournier gangrene is a rare, life-threatening necrotizing fasciitis that usually involves the perineal or genital areas. Malignant mesothelioma in the inguinal and paratesticular region is a very rare entity and manifesting as Fournier's gangrene is still rare. Here we present a case of malignant mesothelioma which presented clinically as Fournier's gangrene.

**Keywords:** Fournier's gangrene, Malignant mesothelioma, Histopathology, Immunohistochemistry

### INTRODUCTION

Fournier's gangrene is an infection with mixture of anaerobic and aerobic microorganisms which results in the necrosis of fascia layers of perineal and genital areas. The incidence rate of Fournier's gangrene is 1.6 cases per 100,000 males/year with a peak incidence at the age of 50 years.<sup>1</sup>

The most common causes of Fournier's gangrene are anorectal infections, genitourinary infections or local injuries to the perineal and genital skin.<sup>2</sup> The pathology of Fournier's gangrene is described as synergistic necrotizing fasciitis resulting in the thrombosis of small subcutaneous vessels of suppurative bacterial infection of the anorectal, perineal, or genitourinary regions, leading to the development of gangrene in the skin.<sup>3</sup>

Malignant mesotheliomas, a rare condition and involvement of the paratesticular region is much rare and the cases usually present without any specific findings, making the diagnosis more complex.<sup>4</sup> Rarely cases with

paratesticular mesothelioma presented with hydrocele which has been reported as a predisposing factor.<sup>5</sup>

Paratesticular mesothelioma accounts for around 0.3–1.4% of all malignant mesotheliomas.<sup>6</sup> Apart from asbestos exposure, possible association between radiation therapy and subsequent development of malignant mesothelioma is also suggested.

These two conditions were entirely different in its risk factors, presenting symptoms and diagnosing techniques but in this case, they occurred in an unusual site (inguinal region) and made the diagnosis, a challenge.

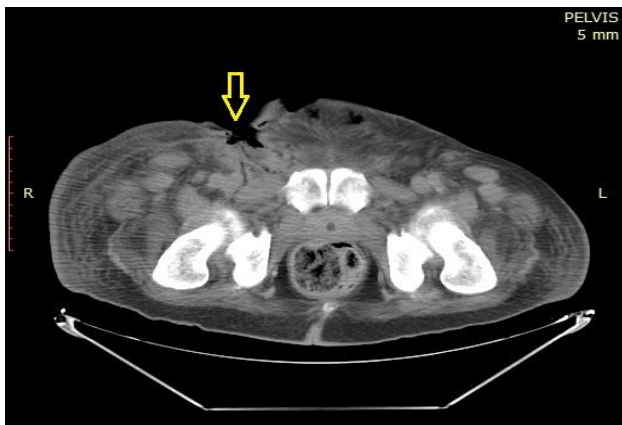### CASE REPORT

A 63 years old male, presented to casualty with history of wound over right inguinal region and right scrotum with multiple discharging sinuses for the past 15 days. He underwent incision and drainage, and wound debridement elsewhere and referred to our hospital because the wound was not healing.

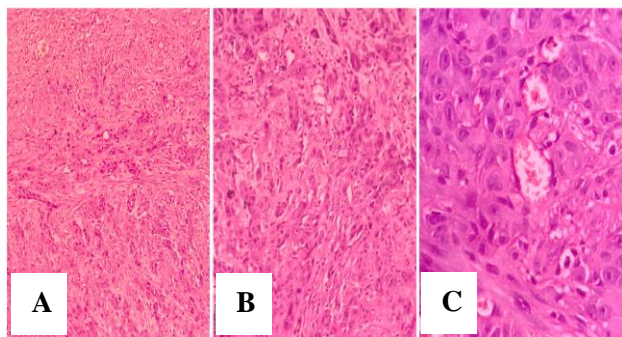
On examination, a wound measuring 6×4 cm over the right inguinal region and second wound measuring 4×3 cm over the right scrotum with pus discharge and multiple discharging sinuses in the surrounding skin was seen. He was clinically diagnosed to have Fournier's gangrene.

His routine hematological investigation showed Hb-8.9 g/dL, Total count-16,700 cells/mm<sup>3</sup>, Differential leucocyte count showed neutrophil predominance, Serum Beta HCG-8.34 mIU/mL, AFP-1.01 ng/mL and LDH-296 U/L.

Computed tomography (CT) scan revealed large ulceroproliferative lesion in the right half of scrotum with heterogeneously enhancing margins and floor of the lesion infiltrating into the underlying muscles, shown in Figure 1.



**Figure 1: Ulceroproliferative lesion in the right inguinal region (arrow) infiltrating into the underlying muscles.**

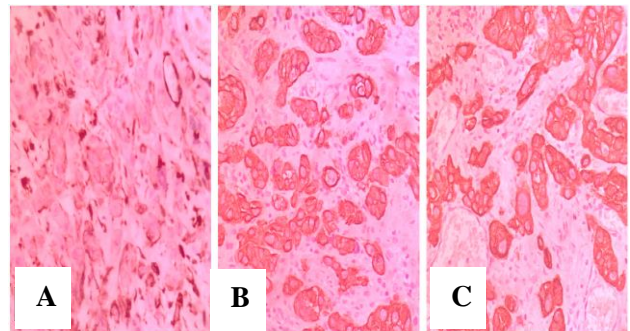


**Figure 2: (A, B) Tumour cells arranged in cords and clusters. (C) Tumour cells showing abundant eosinophilic cytoplasm and prominent nucleoli.**

Multiple heterogenous nodules in the subcutaneous planes of bilateral inguinoscrotal region (right side more than left side) was noted. Also, multiple enlarged and enhancing necrotic lymph nodes in the bilateral inguinal region and along the external iliac vessels (right side more than left side) was noted. Patient was admitted and

treated conservatively for 3 days with IV antibiotics and IV fluids. Later, patient underwent wound debridement and right orchidectomy under local anaesthesia.

Histopathological microscopic examination of the debrided tissue and the right orchidectomy specimen showed tumour cells arranged in cords and clusters with abundant eosinophilic cytoplasm and prominent nucleoli suggestive of poorly differentiated carcinoma of para testicular region with tumour invasion into spermatic cord (Figure 2).



**Figure 3: Tumour cells showing positivity for (A) Vimentin (B) PanCK (C) CK5/6.**

Immunohistochemistry (IHC) study was done and showed positive for Vimentin, PanCK, CK5/6 and WT1 whereas IHC was negative for PLAP, CD117, Calretinin and CD34 and a diagnosis of Malignant Mesothelioma was made. The patient was planned for chemotherapy and radiotherapy but succumbed to death within 15 days of diagnosis (Figure 3).

## DISCUSSION

In 1883, Parisian venereologist, Jean Alfred Fournier described a fulminant gangrene of idiopathic nature which is sudden in onset involving scrotum and penis, in a series of five young males.<sup>7</sup>

Malignant mesothelioma is a rare tumor, usually occur in the pleura or peritoneum usually following asbestos exposure and depends upon duration of exposure. Though this case was initially manifested as Fournier's gangrene later the diagnosis was made as malignant mesothelioma. Those originating in the tunica vaginalis of testis are much rarer conditions, representing less than 5% of all mesothelioma.<sup>8</sup>

Most of the cases with malignant mesothelioma were more than 50 years. Only about 10% of diagnosed males were younger than 25 years and less than 7% under the age of 20.7 In the paratesticular region, mesotheliomas are rare. When they arise in the tunica vaginalis, mesotheliomas are more often malignant than benign.<sup>9</sup> A history of asbestos exposure is reported approximately in one third of cases, although the significance of this

finding is unclear.<sup>10</sup> The clinical presentation is, generally, unilateral, persistent inguinal swelling.<sup>11</sup>

Computed tomography (CT) and Magnetic resonance imaging (MRI) can help to discover lymph node involvement (predominantly paraaortal or pelvic) and distant metastases.<sup>7</sup> Aspiration of hydrocele fluid can reveal malignant cells and ultrasound guided FNA of visible masses is more accurate.<sup>12</sup> There were cases of preoperative diagnosis based on fine needle aspiration of the retroperitoneal lymph node metastasis.<sup>7</sup> Histopathological features of paratesticular mesotheliomas are similar to pleural or peritoneal.<sup>13</sup>

On histopathology, malignant mesotheliomas have been sub classified into epithelial type, mesenchymal or sarcomatous type and the biphasic or mixed type.<sup>14</sup> Epithelial type commonly reported in the peritoneal cavity and the tunica vaginalis and the second sarcomatous type, commonly found in the pleural cavity whereas the mixed type occurs in serosal membranes.<sup>14</sup> For definitive diagnosis, the best positive immune histochemical (IHC) markers are calretinin, cytokeratin 5/6 and WT1, whereas the best negative IHC markers are CEA, MOC-31, Ber-EP4, BG-8 and B72.3 and Vimentin can provide variable results on IHC for Malignant Mesothelioma.<sup>15</sup>

Differential diagnosis of Fournier's gangrene in the setting of an underlying malignancy on histopathological examination includes rectal adenocarcinoma, colonic adenocarcinoma, prostatic adenocarcinoma, scrotal pleomorphic sarcoma, urethral squamous cell carcinoma and scrotal squamous cell carcinoma.<sup>16</sup>

Most patients are initially treated conservatively for a suspected benign entity and the diagnosis of malignancy is often made postoperatively. On subjecting the specimen to immunohistochemical assay, calretinin staining is positive in malignant mesothelioma. The treatment of choice is surgical excision.

## CONCLUSION

In this case, the diagnosis of malignant mesothelioma was made by immunohistochemistry from a suspected case of Fournier's gangrene. Hence, we encourage the histopathological study of debrided tissues of Fournier's gangrene to rule out the rare possibility of malignancy.

*Funding: No funding sources*

*Conflict of interest: None declared*

*Ethical approval: Not required*

## REFERENCES

1. Sorensen MD, Krieger JN, Rivara FP, Broghammer JA, Klein MB, Mack CD, et al. Fournier's

- Gangrene: population based epidemiology and outcomes. J Urol. 2009;181(5):2120-6.
2. Morpurgo E, Galandiuk S. Fournier's gangrene. Surg Clin North Am. 2002;82:1213-24.
  3. Eke N. Fournier's gangrene: a review of 1726 cases. Br J Surg. 2000;87:718-28.
  4. Murai Y: Malignant mesothelioma in Japan: analysis of registered autopsy cases. Arch Environ Health 2001;56(1):84-8.
  5. Gurdal M, Erol A. Malignant mesothelioma of tunica vaginalis testis associated with long-lasting hydrocele: could hydrocele be an etiological factor? Int Urol Nephrol. 2001;32(4):687-9.
  6. Bisceglia M, Dor DB, Carosi I. Paratesticular mesothelioma. Report of a case with comprehensive review of literature. Adv Anat Pathol 2010;17(1): 53-70.
  7. Fournier JA, Jean-Alfred Fournier 1832-1914. Gangrene foudroyante de la verge (overwhelming gangrene). Sem Med 1883. Dis Colon Rectum. 1988;31:984-8.
  8. Shimada S, Ono K, Suzuki Y, Mori N: Malignant mesothelioma of the tunica vaginalis testis: a case with a predominant sarcomatous component. Pathol Int 2004;54(12):930-4.
  9. Gaudin PB, Epstein JI. Diseases of the spermatic cord and paratesticular tissue. In: Murphy WM, editor. Urological pathology. 2nd ed. Philadelphia, Pa: WB Saunders Co. 1997:242-76.
  10. Plas E, Riedl CR, Pfluger E. Malignant mesothelioma of the tunica vaginalis testis. Review of the literature and assessment of prognostic parameters. Cancer. 1998;83:2437-46.
  11. Khoubehi B, Mishra V, Ali M, Motiwala H, Karim O: Adult paratesticular tumours. BJU Int 2002;90:707-13.
  12. Bruno C, Minniti S, Procacci C. Diagnosis of malignant mesothelioma of the tunica vaginalis testis by ultrasound- guided fine-needle aspiration. J Clin Ultrasound. 2002;30(3):181-3.
  13. Lloreta-Trull J. Extrathoracic mesothelial proliferations and their mimics. Ultrastruct Pathol 2006;30(1):37-51.
  14. Eimoto T, Inoue I. Malignant fibrous mesothelioma of the tunica vaginalis: a histologic and ultrastructural study. Cancer. 1977;39:2059-66.
  15. Ordóñez NG. The immunohistochemical diagnosis of mesothelioma: a comparative study of epithelioid mesothelioma and lung adenocarcinoma. Am J Surg Pathol 2003;27:1031-51.
  16. Mann AJ, Reinoso DB, Genuit T, Jimenez J. Fournier's Gangrene in the Setting of Underlying Carcinoma: A Case Report and Review of the Literature. Cureus 2020;12(9):e10317.

**Cite this article as:** Sundar GE, Laxminarayana KPH, Shetty JK, Lobo L. An unusual case of malignant mesothelioma mimicking as Fournier's gangrene. Int J Res Med Sci 2021;9:620-2.