

Original Research Article

The diagnostic utility of ancillary CD117 immunomarker compared with cell block cytology of thyroid lesions based on Bethesda grading system

Muhammad Yousif Khoso, Amin Fahim*, Aneela Qureshi, Syed Naqeeb Ali

Department of Pathology, Al-Tibri Medical College, Karachi, Pakistan

Received: 17 August 2018

Accepted: 26 September 2018

***Correspondence:**

Dr. Amin Fahim,

E-mail: draminfahim@gmail.com

Copyright: © the author(s), publisher and licensee Medip Academy. This is an open-access article distributed under the terms of the Creative Commons Attribution Non-Commercial License, which permits unrestricted non-commercial use, distribution, and reproduction in any medium, provided the original work is properly cited.

ABSTRACT

Background: This is a cross sectional multicenter study carried out from July 2017 to December 2017. The aim of the present study is to evaluate the fine needle aspiration cytology and cell block of thyroid lesions on the basis of Bethesda grading system. Also, expression of CD117 immunostaining in thyroid lesions was evaluated. Finally, the results of cell block were compared with expression of CD117 immunomarker for diagnostic confirmation of different thyroid lesions.

Methods: Total one hundred (100) patients presenting with thyroid swelling underwent fine needle aspiration, cell block preparation to diagnose and categorize thyroid lesion on the basis of Bethesda grading system and finally immunostaining with CD117 was carried out.

Results: FNAC results showed 71% patients with benign thyroid morphology and about 23% cases were categorized as atypical to fairly malignant. In cell block study benign lesions diagnosed were 77%, 17% cases as suspicious and 6% were malignant thyroid nodules. Whereas expression of ancillary CD117 immunomarker, confirmed 83% as benign lesions and 17% cases as malignant. Overall ancillary CD117 immunomarker established the better diagnosis to manage and differentiate thyroid lesions.

Conclusions: Cell block results are more accurate than FNAC in thyroid patients. The CD117 immunomarkers can be used as better diagnostic tool for confirmation of thyroid lesions and thus it can reduce unnecessary surgical intervention.

Keywords: Bethesda grading system, Cell block, CD117 immunomarker, Fine needle aspiration cytology, Haematoxyline and eosin, Thyroid nodule

INTRODUCTION

Thyroid diseases are prevalent in areas where food iodine is deficient, that leads to swellings of thyroid called goiter and hypothyroidism.¹ Thyroid nodular disorders are more common. Over all incidence is approximately is 4-7%. Most of these nodules are benign hyperplastic, but 5-20% are true neoplasms.² To evaluate any thyroid lesion routine steps considered are; physical examination, neck ultrasound, thyroid functioning tests, thyroid scan, MRI

and FNA Biopsy.³ Fine-needle aspiration cytology (FNAC) has become an extremely popular technique for evaluation of thyroid lesions. It is quick, inexpensive and can be carried out in outpatient department.⁴ It is recommended as initial test for evaluation of thyroid swellings to reduce the rate of unnecessary thyroid surgeries.⁵⁻⁸ Only about 14% of the surgically resected thyroid nodules were reported to be malignant before the introduction of FNA in practice, however it has raised to 50% with the effective use of FNA.⁹ National cancer

society (NCI) conference participants (2007) acknowledged the importance of a uniform terminology for reporting thyroid FNAC, which led to framework the Bethesda system for reporting of thyroid cytopathology.¹⁰

The diagnostic accuracy of FNAC of thyroid nodules on basis of Bethesda grading system is less decisive. So, cell blocks are used for better diagnosis as compared to FNAC. Cell blocks are prepared from centrifugation of FNAC fluid. The thick sediment material is embedded in liquid paraffin and cut by microtome and stained by Hematoxylin & Eosin.¹¹ Arif et al, reported about 82% to 94% cell block results were comparable to tissue histopathology results.¹²

CD117 is an ancillary immunomarker, 145-160 kDa cell membrane protein produced by type-III tyrosine kinase. Moreover, it is expressed on epithelial cells of breast, sweat glands, salivary glands, thyroid follicular cells and show weaker cytoplasmic reaction.¹³ CD117 marker is over expressed in gastrointestinal stromal tumors whereas it shows reduced expression in papillary thyroid cancer.¹⁴

CD117 is economic and more accurate to categorize and confirm inflammatory, benign and malignant thyroid lesions. Therefore, the present study was designed to compare the CD117 immunomarker expression with cell block results based on Bethesda grades in order to categorize, differentiate and confirm the diagnosis.

METHODS

This cross-sectional study was conducted from January 2017 to June 2017 through purposive sampling technique. Sample size for the study was calculated with incidence of the thyroid disease at 7% probability and was approximately 100 patients. The Patients with diffuse, nodular and multinodular thyroid swellings with or without pain were included in the study. The non-cooperative patients and patients with blood diathesis were excluded. The ethical approval of the study was obtained from Institutional Research and Ethical committee. An informed consent was obtained either from the patient or her guardian. The FNAC and cell block reporting and diagnostic procedure was applied on all the aspirates followed by grading on the basis of Bethesda grading system. The CD117 immunostaining (IHC) was applied on all the slides prepared from paraffin embedded tissue blocks.

For immunohistochemistry monoclonal antibody CD117 (clone YR 145 which is already diluted; cell marque, Rocklin, Calif) was done on Leica Microsystems bond III automated tissue staining systems, as Leica Microsystems, Buffalo Grove using polymer refine detection kit.¹⁴

Scoring was measured by coloration extent of follicular cells. Staining of less than 5% cells were counted as negative and more than 5% were counted as positive and

severity of mast cells were visualized as evidence of positive control. Score 1 or weak positive was counted if 5-50% cells were stained. Score 2 or moderately positive was counted when more than 50% cells were stained. Score 3 showed the strong staining pattern.¹⁴

The score was determined by immunohistochemical analyses (Hercep Test™). Score 0 means that no staining or membrane staining that is incomplete and faint in <10% of the tumor cells. Score 1+ is also negative and indicates a faint/barely perceptible membrane staining is detected in >10% of tumor cells. The cells exhibit incomplete membrane staining. A score 2+ is equivocal or weakly positive that indicates a weak-to-moderate complete membrane staining in >10% of the tumor cells. A score of 3+ by IHC was considered as positive and it shows circumferential homogenous dark staining in >10% of the tumor cells.¹⁵

RESULTS

In present study 100 cases of thyroid fine needle aspiration (FNA) cytology and cell block made from every aspirate were studied and were categorized according to Bethesda grading system. The results of CD117 immunomarker and cell block made from each aspirate were compared.

The mean±SD age of patients in 100 selected cases was 38.4±12.2(SD) years with age range 11-70 years. The youngest patient in our series was 11 years old female with Bethesda grade III. The female to male ratio was 7.3:1. On physical examination 67 cases (67%) had firm consistency, 20 cases (20%) cases with soft and 13 cases (13%) were with hard consistency. The majority of thyroid swellings were 2-5cm size in 67 cases (67%), in 23 cases (23%) the size noted was >5cm and in 10 cases (10%) it was <2cm.

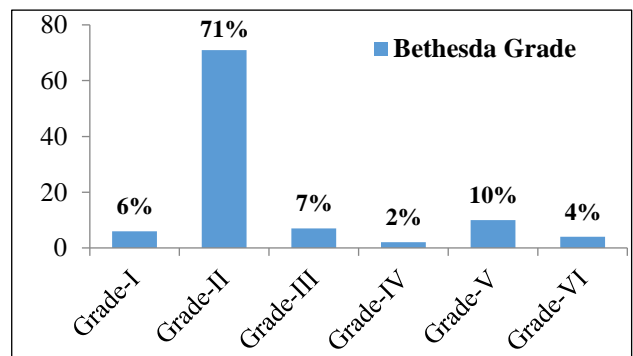


Figure 1: Bethesda grading of thyroid FNAC patients.

According to the Bethesda system reporting of thyroid FNAC, 100 cases were diagnosed and categorized in six grades. The grade-I comprised of 6 cases with cytology showing minimum cellularity with plenty of foamy macrophages. The highest number of cases on FNAC was of grade-II with 71 (71%) cases. The grade-III comprised

of 7 cases with smears showing follicular and lymphoid cells with architectural atypia. In grade-IV; alteration in follicular cell architecture characterized by cell crowding, microfollicles, dispersed isolated cells and scanty colloid was seen in 2 cases. The number of cases on FNAC in grade-V was 10 cases. In grade-VI follicular cells arranged in papillae or syncytial or monolayered epithelial cells exhibiting characteristic nuclear features were seen in 4 cases as shown in Figure 1.

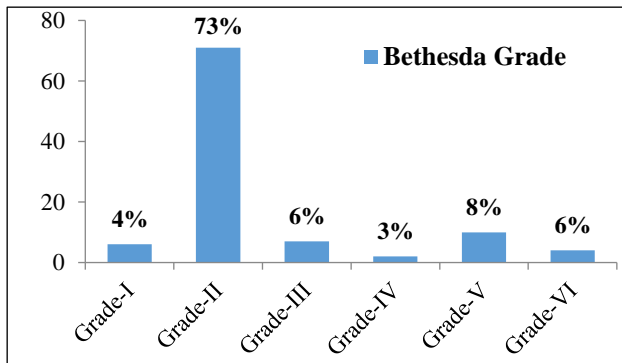


Figure 2: Bethesda grading of thyroid lesions on cell block.

The Bethesda grading of cell block cases revealed, highest 73% cases in grade-II, 4%, 6%, 3%, 8% and 6% cases in grade-I, grade-III, grade-IV, grade-V and grade-VI respectively as showed in Figure 2. Out of 100 cases 17% cases expressed negative immuno expression and 83% cases were positive with CD117 signifying their benign status.

The results of cell block and CD117 immunostaining were compared statistically. In grade-II all 73% cases on cell block, stained positive with CD117 immunomarker, while in grade-VI all 6% cases on cell block showed negative expression of CD117 immunomarker with highly significant p-value 0.001.

Whereas out of total 6 and 8 cases diagnosed in grade-III and grade-V on cell block, revealed only five and two cases as positive on CD117 immunomarker, with p-value of 0.02 and 0.04 respectively as shown in Table 1, Figure 3 and Figure 4.

Table 1: Comparison of CD117 with Bethesda grades on cell block.

Bethesda grade on cell block	CD117 (100 cases)		P value
	Negative (17)	Positive (83)	
Grade-I	4	2	0.10
Grade-II	73	73	0.001
Grade-III	6	5	0.02
Grade-IV	3	1	0.08
Grade-V	8	2	0.04
Grade-VI	6	0	0.001

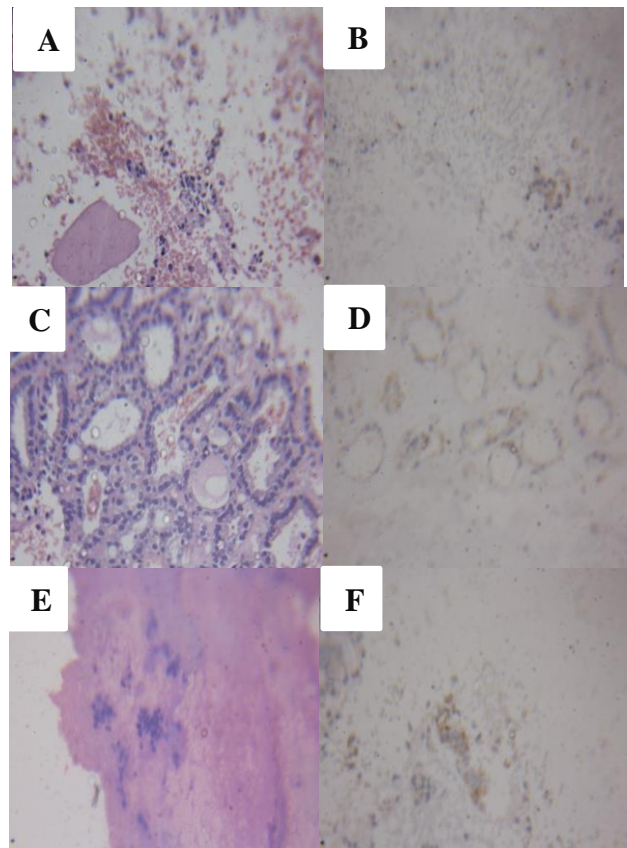
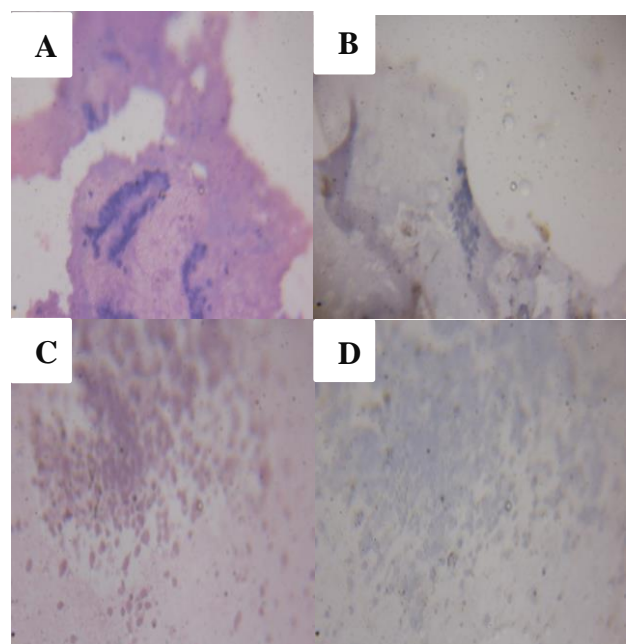


Figure 3: (A): Cell block Grade-I. Few cells in center and colloid patch, H&E x 400, (B): CD117 Grade-I. Few CD117 positive benign cells, CD117 x 400, (C): Cell block Grade-II. Benign follicles, H&E x 400, (D): CD117 Grade-II. Few CD117 positive benign follicular cells, CD117 x 400, (E): Cell block Grade-III. Atypical cells of undetermined significance, H&E x 400, (F): CD117 Grade-III. Faint CD117 positive Atypical cells of undetermined significance, CD117 x 400.



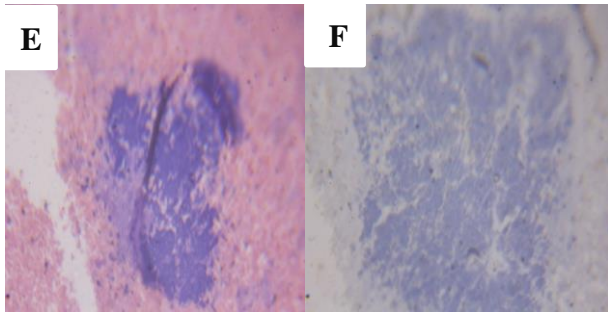


Figure 4 (A): Cell block Grade-IV. Hyperchromic follicular cells, H&E x 400, (B): CD117 Grade-IV. CD117 negative malignant cells, CD117 x 400, (C): Cell block Grade-V. Diffuse clusters of suspected malignant cells, H&E x 400, (D): CD117 Grade-V. Diffuse clusters of suspected malignant cells with absent CD117 x 400, (E): Cell block Grade-VI. Sheets of malignant cells, H&E x 400, (F): CD117 Grade-VI. Diffuse sheets of malignant cells with absent CD117 x 400.

DISCUSSION

FNAC of thyroid was very easy procedure for swelling in neck in surgical outpatient department. This lessens the stress such as for admission in hospital or any surgical excision of thyroid swellings. FNAC thyroid did not need any preparation and can be done in OPD on examination table. The reports are also given within hours.¹² Although FNAC thyroid is safe method for diagnosing thyroid nodules but pain, hematoma, false positive or false negative reports and at times insufficient material results in failure to diagnose hidden malignant lesions.¹²

The mean age in the present study was 38.4±12.2 years. Similar results are reported by Renuka IV et al, and Wahid et al, with 34 years and 42 years mean age respectively.¹⁶⁻¹⁷ However dissimilar findings are noted in Siddegowda et al and Medici et al, study with 18.5 years and 52.5 years respectively.^{4,18} Siddegowda et al, conducted study only on children, while Medici et al, conducted a study on large cohort in 10 years duration, which may be a reason of variation in the mean age of the patients when compared with the findings of present study.^{4,18} In this study female dominance was observed. In a study by Morgan JL et al, and Renuka IV et al, reported female dominance with female to male ratio of 6:1 and 9:1 respectively.^{16,19} This is in favor of findings of the present study.

In present study 67% of the patients presented with firm consistency of thyroid swelling followed by 20% patient with soft thyroid nodules. In a study by Khan et al, reported similar results with 65% cases having firm thyroid nodules.²⁰ In contrast to the present study Chetan et al, reported 90% patients having firm consistency which is much higher than present study. However, sample size was smaller in his study which may be the reason for different consistency of thyroid nodules.²¹

According to Bethesda grading of FNAC cases 71% patient were of grade-II in present study. Similar findings with 71% cases in grade-II are reported by Renuka et al.¹⁶ In grade-V and grade-VI, 8% and 6% cases were seen in present study. Similarly, Morgan et al also reported 13% and 9% cases respectively in favor of our findings.¹⁹

Cell block is helpful in better diagnosis when compared with FNAC. Cell block involve the centrifugation of thyroid aspirates followed by paraffin embedding. After H&E staining, diagnosis is also made according to Bethesda grades.¹¹ According to Bethesda grading of cell block, 73% cases were in grade-II in present study. Similar findings with 76.6% cases diagnosed in grade-II are reported by Ahmed et al.²² In grade-V and grade-VI, 8% and 6% cases respectively were seen in present study. In a study Basnet et al have reported the significance of cell blocks against the FNAC smears, with diagnostic accuracy of 100% in tumors of thyroid.²³

CD117 is expressed on normal lining epithelial cells of thyroid follicles and also positive over all epithelial cells of all benign nodules. But is negative or faint expression is seen in malignant cells of thyroid follicular cells.²⁴ CD117 membrane reactivity does not relate with size of any tumors and also CD117 membrane immunoreactivity can predict the short survival in lung adenocarcinoma.²⁵

In present study CD117 immunostaining in all the cases with benign morphology showed positive expression. Similar results are reported by Pusztaszeri et al, with 100% positive CD117 in benign thyroid nodules. In our study 15 out of 23 cases were negative with CD117 marker indicating their suspicious and malignant morphology.¹⁴ Similarly regarding malignant tumors Pusztaszeri et al, reported 26 out of 35 cases with negative CD117 staining compared with cell block.¹⁴

CONCLUSION

The findings of CD117 proved more sensitive and specific for differentiating and confirming the diagnosis of thyroid swellings. The data acquired and analyzed showed that; In cell block study benign lesions diagnosed were 77%, 17% cases as suspicious and 6% were malignant thyroid nodules. Whereas expression of ancillary CD117 immunomarker, confirmed 83% as benign lesions and 17% cases as malignant.

Funding: No funding sources

Conflict of interest: None declared

Ethical approval: The study was approved by the Institutional Ethics Committee

REFERENCES

- Vanderpump MP. The epidemiology of thyroid disease. *Br Med Bull.* 2011 Sep 1;99(1).

2. Papini E, Guglielmi R, Bianchini A, Crescenzi A, Taccogna S, Nardi F, et al. Risk of malignancy in nonpalpable thyroid nodules: predictive value of ultrasound and color-Doppler features. *J Clin Endocrinol Metabolism*. 2002 May 1;87(5):1941-6.
3. Levis E, David S, Werner and Ingbar, The Thyroid: A fundamental and clinical text. 9th ed, Philadelphia: Lippincott Williams and Wilkins (LLW). 2005.
4. Siddegowda MS, Nayaka M, Shivakumar S. Evaluation of thyroid lesions by FNAC among youth and children: a hospital based observational study. *Int Arch Integrated Med*. 2015;2(4):39-51.
5. Amrikachi M, Ramzy I, Rubenfeld S, Wheeler TM. Accuracy of fine-needle aspiration of thyroid. *Arch Pathol Lab Med*. 2001;125:484-8.
6. Cramer H. Fine-needle aspiration cytology of the thyroid: an appraisal. *Cancer Cytopathol*. 2000 Dec 25;90(6):325-9.
7. Giard RW, Hermans J. Use and accuracy of fine-needle aspiration cytology in histologically proven thyroid carcinoma: an audit using a national pathology database. *Cancer Cytopathol*. 2000 Dec 25;90(6):330-4.
8. Ravetto C, Colombo L, Dottorini ME. Usefulness of fine-needle aspiration in the diagnosis of thyroid carcinoma: a retrospective study in 37,895 patients. *Cancer Cytopathol*. 2000 Dec 25;90(6):357-63.
9. Sclabas GM, Staerkel GA, Shapiro SE, Fornage BD, Sherman SI, Vassilopoulou-Sellin R, et al. Fine-needle aspiration of the thyroid and correlation with histopathology in a contemporary series of 240 patients. *Am J Surg*. 2003 Dec 1;186(6):702-10.
10. Faquin WC, Wong LQ, Afrogheh AH, Ali SZ, Bishop JA, Bongiovanni M, et al. Impact of reclassifying noninvasive follicular variant of papillary thyroid carcinoma on the risk of malignancy in the Bethesda system for reporting thyroid cytopathology. *Cancer Cytopathol*. 2016 Mar;124(3):181-7.
11. Gümüş M, Çay N, Algin O, İpek A, Ersoy RÜ, Belenli O, et al. Comparison of 21 and 27 gauge needles for determining sample adequacy in the aspiration biopsy of thyroid nodules. *Diagn Interv Radiol*. 2012 Jan 1;18(1):102-5.
12. Arif M, Sunil H. Research Article Benefits and limitations of FNAC in thyroid diseases: our institutional experience. *Int J Res Med Sci*. 2013 Oct;1(4):435-40.
13. Oguz A, Yildiz L, Kefili M, Kanemir B. CD117 expression in normal, inflammatory, and reactive lesion of the thyroid. *Pathol Res Pract*. 2008;204(6): 359-65.
14. Puztaszeri MP, Sadow PM, Faquin WC. CD117: a novel ancillary marker for papillary thyroid carcinoma in fine-needle aspiration biopsies. *Cancer Cytopathol*. 2014 Aug;122(8):596-603.
15. Baloch ZW, Cibas ES, Clark DP, Layfield LJ, Ljung BM, Pitman MB, et al. The national cancer institute thyroid fine needle aspiration state of the science conference: a summation. *Cyto J*. 2008;5:6.
16. Renuka IV, SailaBala G, Apama C, Kumari R, Sumalatha K. The Bethesda grading system for thyroid cytopathology. *Indian J Otolaryngol Head Neck Surg*. 2012;64(4):305-11.
17. Wahid FI, Khan SF, Rehman HU, Khan IA. Role of fine needle aspiration cytology in diagnosis of solitary thyroid nodules. *Iranian J Otorhinolaryngol*. 2011;23(65):111-8.
18. Medici M, Liu X, Kwong N, Angell TE, Marqusee E, Kim MI, et al. Long-versus short-interval follow-up of cytologically benign thyroid nodules: a prospective cohort study. *BMC Med*. 2016;(1):11-3.
19. Morgan JL, Serpell JW, Cheng MS. Fine-needle aspiration cytology of thyroid nodules: how useful is it?. *ANZ J Surgery*. 2003 Jul;73(7):480-3.
20. Khan I, ul Rasool M, Khan I, Hamid S, Angmoo P, Koul KK. Clinical presentation of various thyroid lesions in a study population attending a teaching hospital in North India. *Int J Advances Med*. 2017 Feb 11;1(2):145-8.
21. Veeresalingam B, Durbesula PT, Rao PS. A study on the clinical manifestations and the incidence of benign and malignant tumors in a solitary thyroid nodule. *Int J Res Med Sci*. 2017 Jan 28;1(4):429-34.
22. Ahmed Z, Medhi P, Das D. Diagnostic utility of cell blocks in thyroid aspirates. *J Evolution Med Dental Sci*. 2015 Sep 21;4(76):13221-32.
23. Basnet S, Talwar OP. Role of cell block preparation in neoplastic lesions. *J Pathol Nepal*. 2012 Jan 1;2(4):272-6.
24. Puztaszeri MP, Krane JF, Cibas ES, Daniels G, Faquin WC. FNAB of benign thyroid nodules with papillary hyperplasia: a cytological and histological evaluation. *Cancer Cytopathol*. 2014 Sep;122(9):666-77.
25. Iyoda A, Hiroshima K, Nakatani Y, Fujisawa T. Pulmonary large cell neuroendocrine carcinoma: its place in the spectrum of pulmonary carcinoma. *Ann Thoracic Surg*. 2007 Aug 1;84(2):702-7.

Cite this article as: Khoso MY, Fahim A, Qureshi A, Ali SN. The diagnostic utility of ancillary CD117 immunomarker compared with cell block cytology of thyroid lesions based on Bethesda grading system. *Int J Res Med Sci* 2018;6:3634-38.