

## Case Report

# Epidermolytic hyperkeratosis: a rare case

Koushik Pan<sup>1\*</sup>, Subrata Chakrabarti<sup>1</sup>, Rajdip Choudhury<sup>1</sup>,  
Anup Sarkar<sup>1</sup>, Ritabrata Mitra<sup>2</sup>

<sup>1</sup>Department of General Medicine, SSKM, IPGME & R, Kolkata, West Bengal, India

<sup>2</sup>Department of Chest Medicine, SSKM, IPGME & R, Kolkata, West Bengal, India

**Received:** 3 October 2013

**Accepted:** 16 October 2013

**\*Correspondence:**

Dr. Koushik Pan,

E-mail: panjoy86@gmail.com

© 2014 Pan K et al. This is an open-access article distributed under the terms of the Creative Commons Attribution Non-Commercial License, which permits unrestricted non-commercial use, distribution, and reproduction in any medium, provided the original work is properly cited.

### ABSTRACT

A 6 month old girl presented with generalized hyperkeratosis, most marked over the flexures since birth. On the basis of the clinical & histopathologic findings, she was diagnosed as a case of epidermolytic hyperkeratosis. She was treated with retinoid therapy. Epidermolytic hyperkeratosis (EHK) is an uncommon form childhood keratinizing disorder. Early in life it is associated with generalized blistering and erythroderma. Later on, it produces rippled type of hyperkeratosis. The purpose of this report is to highlight the features of this rare case.

**Keywords:** Epidermolytic hyperkeratosis, Acanthosis, Blistering

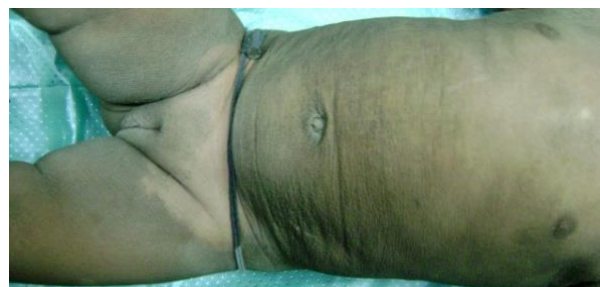### INTRODUCTION

Epidermolytic hyperkeratosis (EHK) was first introduced in 1966<sup>1</sup> & found in a number of congenital & acquired skin disorders. Epidermolytic hyperkeratosis (EHK), also known as bullous congenital ichthyosiform erythroderma, is an autosomal dominant trait with a prevalence of approximately 1 in 200,000 to 300,000 persons.<sup>2</sup> The disease is named for the distinctive histopathologic feature of vacuolar degeneration and associated hyperkeratosis of the epidermis. It usually presents at birth with blistering and redness.

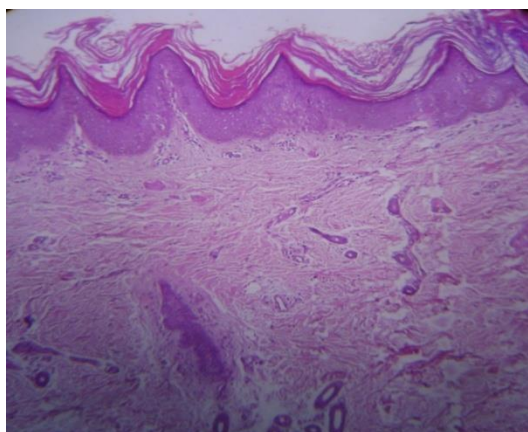
### CASE REPORT

A 6month old female child came to our OPD with hyperkeratosis all over the body, mostly over the anterior side of the neck, all flexors, in fragluteal fold, abdominal wall since birth (Figure 1). Palm, sole & face is spared. Nails are also not involved. She did not have any neurological abnormality & has a normal height as per his age. She has a history of superficial erosion at the sites of minor trauma after birth and bullous lesions over

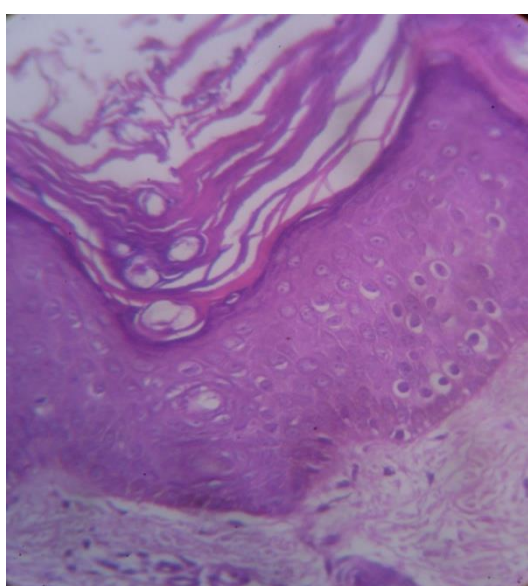
soles. Superficial erosions ceased few months after her birth & followed by hyperkeratosis. Other sibling and parents are not affected. No family history of such diseases. Parents had consanguineous marriage. Careful examination of histopathology (Figure 2 & Figure 3) of hyperkeratotic lesion of skin shows hyperkeratosis, acanthosis with keratohyalinegranules in granular cell layer, sparse lymphocytic cells are seen around blood vessels. But there is no cleft noted in suprabasal layer. On the basis of clinical & histopathological feature epidermolytic hyperkeratosis was diagnosed.



**Figure 1: Child with hyperkeratosis all over the body.**



**Figure 2: Histology 10X view.**



**Figure 3: Histology 40X view.**

## DISCUSSION

Epidermolytic hyperkeratosis is an autosomal dominant disorder of keratinization. The disease is named for the distinctive histopathological features of vacuolar degeneration of the epidermis (i.e. epidermolysis) and associated hyperkeratosis. There is a high frequency of spontaneous mutations and as many as half the cases have no family history and they represent new mutational events.<sup>3</sup> The disease usually presents at birth with blistering, redness and peeling. With time, generalized hyperkeratosis may develop, which may or may not be associated with erythroderma. An underlying genetic defect of keratin synthesis or degradation involving keratin 1 and/or keratin 10 has been suggested.<sup>4</sup> Interestingly keratin 1 mutation is associated with severe palmoplantar hyperkeratosis while keratin 10 mutations are not.<sup>5</sup> Family studies have confirmed an autosomal dominant inheritance and linked it to keratin gene clusters on chromosome 12q and 17q<sup>6-8</sup> Six clinical phenotypes of EHK have been distinguished depending on the presence

of severe palmar/plantar hyperkeratosis: three subgroups with palm/sole (PS type) hyperkeratosis and the other three subgroups with no palm/sole (NPS type) hyperkeratosis. At birth the infant may show marked hyperkeratosis, erythroderma or even present as a collodion baby. The scales are soon lost, leaving a generalized moist, tender erythroderma followed by development of widespread blistering which heals without scarring. As the patient becomes older, erythema and blistering becomes less apparent and later the disease is complicated by the development of verrucous hyperkeratosis, especially in the flexures. Nail dystrophy may be a feature. Some cases are complicated by sepsis, fluid loss and electrolyte imbalance.<sup>9</sup> Severely affected children may be of short stature, although many catch up in adolescence. The condition is associated with markedly increased epidermopoiesis.<sup>10</sup> The histopathological features known as epidermolytic hyperkeratosis (EH) are very striking.<sup>11</sup> Most characteristically it is associated with, (1) massive hyperkeratosis, papillomatosis and acanthosis, (2) greatly thickened and abnormal granular cell layer, (3) intensely eosinophilic intracytoplasmic inclusions in granular layer, (4) intragranular split due to extreme intracellular edema (cytolysis) and (5) intraepidermal blister formation (following cytolysis).

The patients are managed conservatively with the use of topical emollients, appropriate antibiotics and antiseptic creams when required, topical calcipotriol helps in some cases but may induce irritation. Oral retinoids may be required in severe cases. It reduces scaling but may induce skin fragility and blistering.<sup>12</sup> A mildly affected parent may have severely affected child or patient may develop lesion without family history due to de novo mutation. In case of positive family history, prenatal diagnosis can be done with foetal skin at 20 weeks of gestation with ultrasound guided foetoscopy or earlier by direct DNA sequencing chorionic villous sampling. Treatment is mainly symptomatic. Ammonium lactate 12% lotion reduced hyperkeratosis to some extent. Regular wash with antiseptic cleansing lotion is advised. It has been noted that patient with k10 mutation without palmoplantar hyperkeratosis response better with retinoid therapy, so presently retinoid therapy being considered

*Funding: No funding sources*

*Conflict of interest: None declared*

*Ethical approval: Not required*

## REFERENCE

1. Frost P, Scott EJ. Ichthyosiform dermatosis. Arch Dermatol 1966;94:113-26.
2. Nayak S, Behera SK, Acharjya B et al. Epidermolytic hyperkeratosis with rickets. Indian J Dermatol Venereol Leprol 2006;72:139-42.
3. Simpson JR. Congenital ichthyosiform erythroderma. Trans St John's Hosp Derm Soc 1964;50:93.

4. Di Giovanna JJ, Bale SJ. Epidermolytic hyperkeratosis: Applied molecular genetics. *J Invest Dermatol* 1994;102:390.
5. DiCiovanna JJ, Bale SJ. Clinical heterogeneity in epidermolytic hyperkeratosis. *Arch Dermatol* 1994;130:1026-35.
6. Bonifas JM, Bare JW, Chen MA et al. Linkage of epidermolytic hyperkeratosis, phenotype and region of type II keratin cluster on chromosome 12. *J Invest Dermatol* 1992;99:524-7.
7. Compton JG, Di Giovanna JJ, Santucci SK. Linkage of epidermolytic hyperkeratosis to type II keratin gene cluster on chromosome 12q. *Nature Genet* 1992;1:301.
8. Rothangel JA, Dominey AM, Dempsey MD. Mutation in rod domains of keratins 1 and 10 in epidermolytic hyperkeratosis. *Science* 1992;257:1128-30.
9. Shwayder T. All about ichthyosis. *Pediatr Clin North* 1991;38:835-57.
10. Frost P, Weinstein GD, Van Scott EJ. The ichthyosiform dermatoses II. Autoradiographic studies of epidermal proliferation. *J Invest Dermatol* 1996;47:561-7.
11. Holbrook KA, Dale BA, Sybert VP. Epidermolytic hyperkeratosis: ultra-structure and biochemistry of skin and amniotic fluid cells from two affected fetus and new born infants. *J Invest Dermatol* 1983;80:222-7.
12. Blanchet-Bardon C, Nazarro V, Rognin C et al. Acitretin in the treatment of severe disorders of keratinization. *J Am Acad Dermatol* 1991;24:982-6.

DOI: 10.5455/2320-6012.ijrms20140269

**Cite this article as:** Pan K, Chakrabarti S, Choudhury R, Sarkar A, Mitra R. Epidermolytic hyperkeratosis: a rare case. *Int J Res Med Sci* 2014;2:347-9.