

## Case Report

# Rhabdomyolysis and myopericarditis with renal failure in a patient of status epilepticus

Santosh Kumar Pandey\*, Rajnish Avasthi

Department of Medicine, UCMS and GTB Hospital, Delhi, India

**Received:** 04 January 2021

**Revised:** 05 February 2021

**Accepted:** 06 February 2021

### \*Correspondence:

Dr. Santosh Kumar Pandey,

E-mail: santoshkpandey86@gmail.com

**Copyright:** © the author(s), publisher and licensee Medip Academy. This is an open-access article distributed under the terms of the Creative Commons Attribution Non-Commercial License, which permits unrestricted non-commercial use, distribution, and reproduction in any medium, provided the original work is properly cited.

### ABSTRACT

Rhabdomyolysis is characterized by the destruction and leakage of muscle cell components into the circulation. Sustained and prolonged muscle activity is an important factor causing the same. Most of the reported cases in the literature were due to status epilepticus. We report the case of a 25-year-old male who developed acute renal failure and myopericarditis in association with non-traumatic rhabdomyolysis following status epilepticus.

**Keywords:** Rhabdomyolysis, Myopericarditis, Status epilepticus, Acute kidney injury

### INTRODUCTION

Rhabdomyolysis is characterized by the destruction and leakage of components of muscle cell including electrolytes, myoglobin and other myocytic proteins into the circulation.<sup>1</sup> This muscle cell destruction with necrosis, manifesting as myalgia, swelling, and gross pigmenturia is common manifestation of both traumatic and nontraumatic rhabdomyolysis.<sup>2,3</sup>

Acute kidney injury is a worrisome complication of severe rhabdomyolysis, regardless of whether the rhabdomyolysis is the result of trauma or some other cause and the prognosis is significantly detrimental if renal failure develops.<sup>4</sup>

It has various etiology and includes muscle trauma, prolonged and sustained muscle activity, insufficient vascular perfusion, electrolyte imbalances, inborn metabolic errors, infections and ingestion of drugs and toxins.<sup>5</sup>

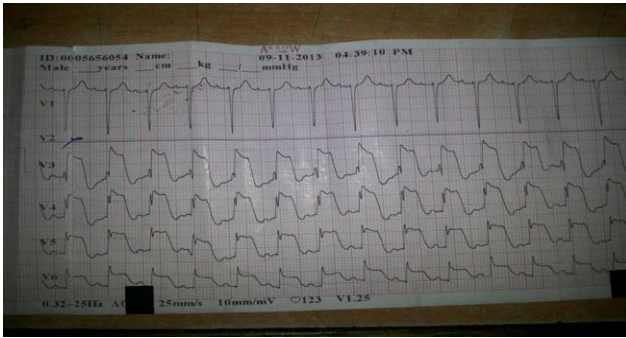
The diagnosis requires clinical suspicion as it can be asymptomatic. A single seizure episode generally is not associated with rhabdomyolysis.

Most of the reported cases in the literature were due to status epilepticus, with dehydration contributing to the process. We report the case of a 25-year-old male who developed acute renal failure and myopericarditis in association with non-traumatic rhabdomyolysis following status epilepticus.

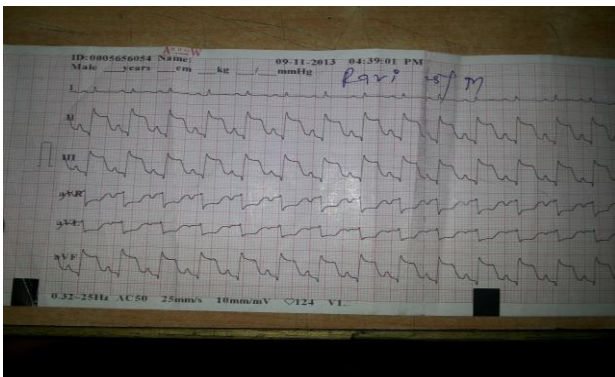
### CASE REPORT

A 25-year-old male presented with history of 4-5 hours of GTCS with no recovery in between. The patient was already a known case of mental retardation and seizure disorder for 10 years and was on regular medication since past 3 years. The relatives of the patient reported that the patient left medication for one week before presentation. There was no history of HTN, DM, fever, decreased urine output, trauma, ingestion of toxic substance or illicit drug, or alcohol abuse. On presentation, the patient was unconscious and responding partially to deep painful stimulus. He was afebrile with a pulse rate of 84/min, blood pressure 105/74 mmHg, and respiratory rate 16/min. Fundus examination was normal and there were no signs of meningeal irritation or focal neurological deficit. Examination of abdomen, cardiovascular, and respiratory systems was unremarkable.

The initial laboratory tests showed a TLC of 17,800/mm<sup>3</sup>, blood urea 90 mg/dl and serum creatinine 2.9 mg/dl. ECG was suggestive of diffuse ST segment elevation in leads II/III/aVF and V2-V6 with PR segment depression in the same leads (Figure 1 and 2). Muscle enzymes CPK were raised (CPK NAC>14000). ABG was s/o hypoxemia. Urine for myoglobin was positive. Serum uric acid levels were raised. Other investigations, including haemoglobin, ESR, RBS, LFT, electrolytes, and ultrasound examination of the abdomen, were all within normal limits. NCCT head and MRI brain were normal. HBsAg, HCV, and HIV serology was negative. Serum levels of phenytoin and valproate were normal.



**Figure 1: Antero lateral leads of ST segment elevation with PR segment depression.**



**Figure 2: Inferolateral leads of ST segment elevation with PR segment depression.**

He was managed with antiepileptic drugs and adequate hydration. During the course of 1 week, the sensorium improved, KFTs settled but ECG changes were the same. However, when he became ambulatory there was weakness over left half of body for which NCCT head was done and was suggestive of acute infarct in right parietal region (hypoxic).

After 1 week ECG changes also settled and weakness also improved. MRI brain was done and it showed few hypodensities in b/l frontal lobe (non-specific). The general condition of the patient improved, ECG changes settled, left sided weakness improved and finally the patient was discharged after nearly one month of admission.

A diagnosis of acute oliguric renal failure with myopericarditis due to seizure-induced rhabdomyolysis was made.

## DISCUSSION

Muscle activity generated during tonic-clonic seizures can cause severe muscular injury leading to rhabdomyolysis. The risk of renal failure due to the same increases with co-morbid conditions such as sepsis, dehydration, and acidosis.<sup>6</sup>

Rhabdomyolysis occurs frequently but is usually asymptomatic. However, in more severe cases, electrolyte imbalances and acute renal failure may occur, leading to life-threatening situations. The increased levels of creatine kinase are the most sensitive laboratory finding for rhabdomyolysis. The risk of renal failure increases above values of 5,000 to 6,000 IU/L.

In our patient, typical clinical features and raised creatine kinase strongly suggested the diagnosis of rhabdomyolysis. The striking feature of this case was the development of acute renal failure and myopericarditis after status epilepticus.

Also, the involvement of heart in the form of myopericarditis as confirmed by ECG changes is considered as a consequence of rhabdomyolysis as the common causes of the same were ruled out in our patient.

The mechanism of renal tubular damage in rhabdomyolysis is the generation of free radicals which induces lipid peroxidation. Other causes of rhabdomyolysis, such as drugs, toxins, inflammatory myopathies and hereditary metabolic myopathies, were excluded by detailed history, examination and biochemical investigations.

## CONCLUSION

Our report highlights the importance of considering rhabdomyolysis in a patient with unexplained renal failure and myopericarditis (considering ECG changes) following status epilepticus. A high index of suspicion of rhabdomyolysis is necessary for early diagnosis and prompt management.

*Funding: No funding sources*

*Conflict of interest: None declared*

*Ethical approval: Not required*

## REFERENCES

1. Bosch X, Poch E, Grau JM. Rhabdomyolysis and acute kidney injury. *N Engl J Med.* 2009;361:62-72.
2. Tein I, DiMauro S, Rowland LP. Myoglobinuria. In: Rowland LP, DiMauro S, eds. *Myopathies. Handbook of clinical neurology.* Vol. 62.

- Amsterdam: Elsevier Science Publishers. 1992;553-93.
3. Warren JD, Blumbergs PC, Thompson PD. Rhabdomyolysis: a review. *Muscle Nerve.* 2002;25:332-47.
  4. Mishra A, Dave N. Acute renal failure due to rhabdomyolysis following a seizure. *J of Family Med Primary Care* 2013;2:86-7.
  5. Larbi EB. Drug induced rhabdomyolysis. *Ann Saudi Med.* 1998;18:525-30.
  6. Grossman RA, Hamilton RW, Morse BM, Penn AS, Goldberg M. Nontraumatic rhabdomyolysis and Acute renal failure. *N Engl J Med.* 1974;291:807-11.

**Cite this article as:** Pandey SK, Avasthi R. Rhabdomyolysis and myopericarditis with renal failure in a patient of status epilepticus. *Int J Res Med Sci* 2021;9:885-7.