

## Original Research Article

# Calcaneal fractures: a management dilemma-minimally invasive approach for intra and extra articular calcaneal fractures

Kawade M. S.<sup>1</sup>, Madan H. S.<sup>2</sup>, Shailesh Khachane<sup>3</sup>, Manjeet Singh Dhanda<sup>2\*</sup>

<sup>1</sup>Department of Orthopaedics, GMC Nagpur, Maharashtra, India

<sup>2</sup>Department of Orthopaedics, SHKM GMC Nalhar, Nuh, Haryana, India

<sup>3</sup>Consultant Orthopaedic Surgeon, Ashirwad Accident Hospital, Maharashtra, India

**Received:** 29 January 2019

**Accepted:** 05 February 2019

### \*Correspondence:

Dr. Manjeet Singh Dhanda,

E-mail: [dr.manjeetdhanda@yahoo.com](mailto:dr.manjeetdhanda@yahoo.com)

**Copyright:** © the author(s), publisher and licensee Medip Academy. This is an open-access article distributed under the terms of the Creative Commons Attribution Non-Commercial License, which permits unrestricted non-commercial use, distribution, and reproduction in any medium, provided the original work is properly cited.

## ABSTRACT

**Background:** Calcaneal fractures which constitutes 2% of total fractures are frequent and very debilitating if not treated properly. Calcaneal fractures generally affect younger population leading to significant man-days loss (around 2-5 years<sup>3</sup>) and in-turn leading significant economic burden on the society. The goal of treatment for calcaneal fractures is elimination of pain and restoration of normal foot shape, biomechanics, and walking ability. Wound related complications are common with open surgeries. After open reduction internal fixation with perimeter plates for displaced calcaneal fractures, wound edge necrosis is commonly observed with the extended lateral approach. Because of such high incidence of wound complications in open reduction of calcaneum fractures, minimally invasive approach takes priority over open reduction of these fractures.

**Methods:** The study aimed to evaluate the results of minimally invasive approach for calcaneal fractures. To reduce the operative complications, 30 patients were treated with minimally invasive methods in both extra articular and intra-articular calcaneal fractures and the results were evaluated. All patients were evaluated clinically, functionally and radiologically 3D- CT reconstruction images.

**Results:** All cases were followed up for 2 years at specified intervals. The outcome measures were evaluated by AOFAS scores<sup>10</sup> with excellent result in 13 cases and good to fair results in the rest. Operated patients had no wound infection, no skin necrosis, 5 patients had mild subtalar arthrosis and 3 patients complained slight difficulty in wearing shoes. None of them have any gait abnormalities.

**Conclusions:** Our study suggests that the minimally invasive methods will reduce the operative complication rates. The minimally invasive surgical intervention in an expert hand can yield better results with less complication rates.

**Keywords:** Calcaneal fractures, Foot-disability, Kashiwagi syndrome, Minimally invasive calcaneal surgeries, Sanders classification, Wound- dehiscence

## INTRODUCTION

Calcaneal fractures are very common and frequently encountered in emergency medical services on daily basis. Calcaneal fractures constitute approximately 2 percent of all fractures.<sup>1</sup> Calcaneal fractures represent

almost 60% of all tarsal fractures.<sup>2</sup> Calcaneal fractures generally affect younger population leading to significant man-days loss (around 2-5 years) and in-turn leading significant economic burden on the society.<sup>3</sup> Etiology in most cases is either a motor vehicle accident or fall from height.<sup>3</sup> Diagnosis of a calcaneal fracture is usually clinical one, but it may be missed very often in cases of

polytrauma and in cases where patient did not complain of pain.<sup>3</sup> Around 20% of patients with calcaneal fractures have associated lumbar spine fractures.<sup>4</sup> Oxford Sign of Bohler (1930) is a sign indicative of calcaneal fracture where there is appearance of hematoma at the medial side of heel after 24 hours of the injury. A fracture of the calcaneum which is allowed to heal conservatively in an improper anatomical position leads to static and dynamic malfunctions of the whole foot, with consequent limited load-bearing capacity and resultant walking disability. The goal of treatment for calcaneal fractures is elimination of pain and restoration of normal foot shape, biomechanics, and walking ability. The soft-tissue envelope around the calcaneus is particularly thin and vulnerable over the lateral wall, which is exposed during surgery in most cases.<sup>5</sup> After open reduction internal fixation with perimeter plates for displaced calcaneal fractures, wound edge necrosis is commonly observed with the extended lateral approach. Because of such high incidence of wound complications in open reduction of calcaneum fractures, minimally invasive approach takes priority over open reduction of these fractures.<sup>6</sup> This study aims to evaluate the clinical, functional and radiographic results of our minimally invasive surgical treatment of intra and extra articular fractures of the calcaneum.

## METHODS

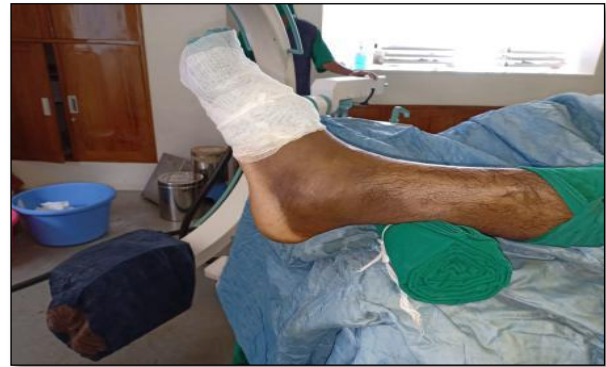A prospective study was conducted in 30 patients who reported to the emergency department. Minimally Invasive surgical intervention done in all these patients. All age groups were included in the study without any gender discrimination. All patients were evaluated radiologically and with 3D- CT reconstruction images. Bohler's angle and crucial angle of Gissane's were calculated pre-operatively in all patients.<sup>7,8</sup>

### *Surgical technique*

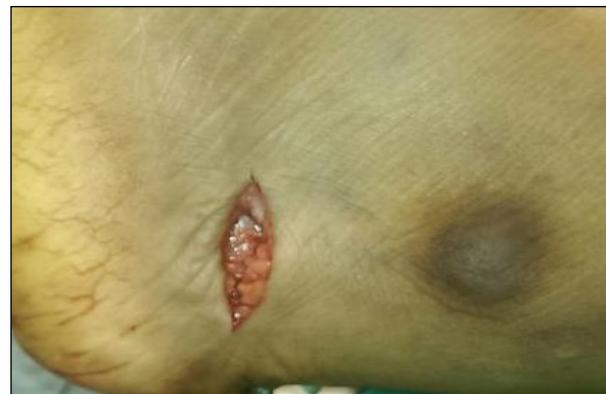Patient was placed supine on operating table with foot end projecting out. C arm free movement is allowed (Figure 1) for easy projections of both views and 360 degree views. After painting and draping small 1.5cm to 2cm incision (Figure 2) was given 2cm below tip of lateral malleolus which goes directly bone deep without elevation of skin and fascial layers so as to prevent wound healing problems.

After reaching lateral cortical wall, a small cortical window of size 1.5cm X1.5cm is made with straight 10mm osteotome under C-arm control. After that, a small strong lamina spreader (Figure 3) was pushed under the posterior facet to lift the impacted facetal fragment with considerable force but with due care so as to avoid breaking through into the subtalar joint. The articular surface was visualized and reduced under c arm and checked in both lateral and axial views. Articular surface was fixed primarily with 1.8mm K- wires. One by one all depressed calcaneal facets are elevated with L shaped

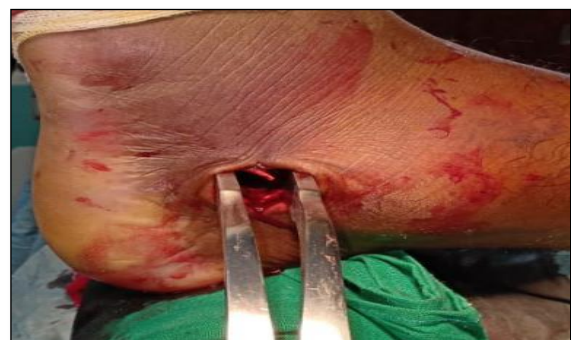punch and mallet and provisionally fixed with multiple 1.8mm K-wires.



**Figure 1: patient positioning.**



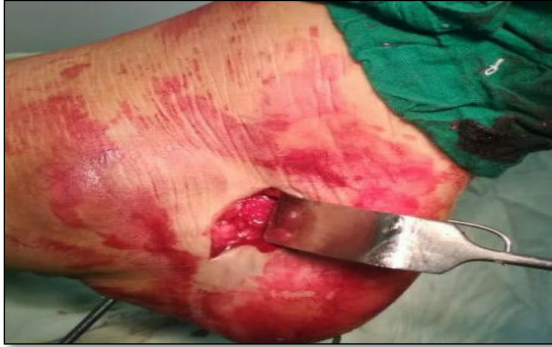**Figure 2: Incision.**



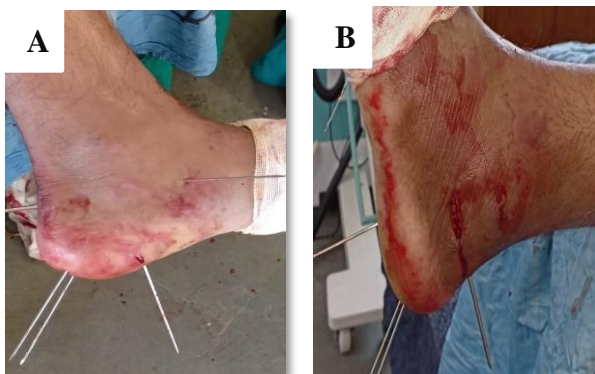**Figure 3: Lamina spreader.**

After achieving articular elevation of calcaneum, size of bony window in lateral calcaneal cortex was measured and same size of tricortical iliac autologous bone graft was harvested from ipsilateral side. Lamina spreader was removed and graft was punched lateral to medially within the created window (Figure 4) in lateral calcaneal wall so that it supports all elevated facetal fragments. Manual pressure was applied medially and laterally below the sustentaculum to reduce the width of calcaneum and

prevent future “kashiwagi” syndrome.<sup>9</sup> After insertion of iliac crest bone graft and confirming articular reduction under c arm in lateral and axial views it was fixed with 1.8mm k wire or 2mm Steinman pin was inserted from calcaneal tubercle passing through the graft and distally fixing within the cuboid bone (Figure 4).



**Figure 4: Impacted bone iliac crest tricortical bone graft.**



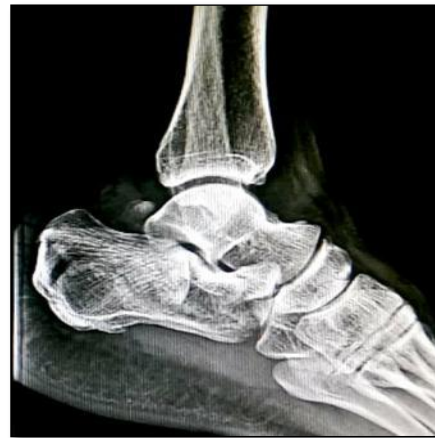**Figure 5: Intraoperative images. A): Medial, B): Lateral.**

A second 1.8mm k wire was inserted from plantar surface of calcaneum passing again through the graft pointing towards the calcaneal Bohler’s angle. Few more K-wires are inserted for additional fixation and maintenance of elevated articular fragments. One 2mm k wire was passed from lateral to medial side just below the sustentaculum tali so as to support it additionally (Figure 5A,5B).

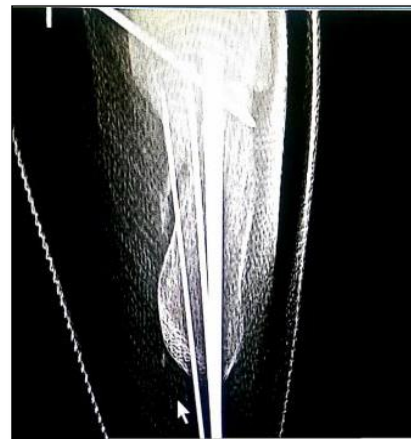
Wound was closed with Allgower-Donati mattress sutures using Ethilon 3-0. Below knee Plaster slab was given for 2 weeks (Figure 6-9).<sup>9</sup> After suture removal slab was removed and mobilization started.

Early mobilization started to prevent post operative joint stiffness. K-wires were removed after 4 weeks. Patient was kept strict non weight bearing for 8 weeks. Toe touch walking allowed after 8 weeks. Partial weight bearing allowed after 3 months and full weight bearing with squatting was allowed after 6 months.

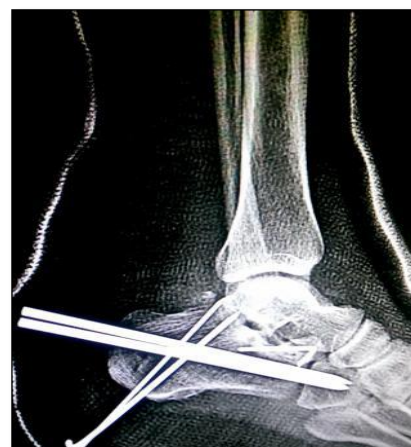Functional outcome of patients was evaluated using American Orthopaedic Foot and Ankle Score<sup>10</sup> (AOFAS) which was calculated at 2 weeks, 6 weeks, 3 months and 6 months post op and at 2 years.<sup>10</sup>



**Figure 6: Pre-op.**



**Figure 7: Immediate post-operative axial view.**



**Figure 8: Immediate post-operative lateral view.**

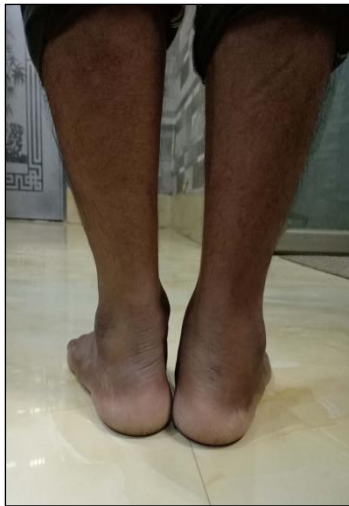

Figure 9: Clinical picture.

## RESULTS

All cases were followed up for 2 years at specified intervals. The outcome measures were evaluated by AOFAS scores (Table 1) with excellent result in 13 cases (score>80) and good to fair results in rest of 20 patients.<sup>10</sup> Operated patients had no wound infection, no skin necrosis, 5 patients had mild subtalar arthrosis and 3 patients complained slight difficulty in wearing shoes. None of them have any gait abnormalities. Out of 30 patients, one patient died due to other comorbidities and cannot be followed for 2 year. Three patients who complained of difficulties in wearing shoes gradually improved with one side higher shoe-size and avoidance of hard sole shoes. 13 patients with excellent result had initial swelling episodes on long standing which gradually subsided on final follow up at 2 years. Physiotherapy was continued for excellent results throughout the period of follow up.

Table-1: AOFAS scores pre-operative and post-operative.

No. of Patients	Pre-op AOFAS Score	Grade	Follow Up Period	Post-op AOFAS Score	Grade
1-13	29-36	Poor	6 Months	74-82	Excellent
14-26	24-28	Poor	6 Months	68-73	Good
27-30	20-23	Poor	6 Months	52-67	Fair

## DISCUSSION

Various meta-analysis showed that operative intervention of typical closed displaced intra-articular calcaneal fractures improves the functional outcome when compared to conservative management but leads to increase in complication rate. Calcaneal fractures are treated as per their classifications.<sup>11-13</sup>

Following are the various classifications mostly used during treatment of calcaneal fractures.

### Fracture classifications

Extra-articular fractures: fracture of the anterior process, tuberosity fracture, and fracture of sustentaculum tali- caused by low- energy trauma, foot inversion, tendon or muscle avulsions.

Intra-articular fractures: caused by high- energy trauma. Most commonly used classifications of intraarticular fractures, classified by native radiography or CT scans are the followings:

- Essex-Lopresti Classification<sup>11</sup>
- Crosby-Fitzgibbon's Classification<sup>12</sup>
- Sander's Classification<sup>13</sup>

There are still controversies about the optimal kind of treatment of the calcaneal fractures, however, non-operative and operative remain the two main stays.<sup>14</sup>

Many complications are associated with the treatment of calcaneal fractures like, early complications of skin necrosis and infection, compartment syndrome, calcaneofibular impingement, instability, subtalar arthrosis, nerve entrapment and nerve injuries, heel pad syndrome and exostosis, tarsal tunnel syndrome etc. Various scoring systems are used to analyse the results which include AOFAS-American Orthopaedic Foot and Ankle society scale<sup>10</sup>, FFI- foot function index, CFS-calcaneal fracture score, OM-Olerud Mollander score and VAS- Visual analogue scale and SF-36 form.

Our study showed that minimally invasive fixation of these fractures prevent skin and wound related complication. In addition to that, this technique helps in early recovery and reducing the disability post operatively.

## CONCLUSION

Various RCTs and meta-analyses published till date have approximately similar functional outcome in both conservative and operative treatment, however, literature

supports better functional outcome in operative patients in settings where the orthopaedic surgeon is well trained, and hospital has the adequate facilities. The minimally invasive surgical intervention in an expert hand can yield better results with less complication rates. Though, further need of large randomized trials cannot be overlooked, nonetheless, our study suggests that the minimally invasive methods will somewhat reduce the operative complication rates and will add on to the success rates of the operative methods. However, more studies are required to consolidate a concrete outcome of such a method.

*Funding: No funding sources*

*Conflict of interest: None declared*

*Ethical approval: The study was approved by the Institutional Ethics Committee*

## REFERENCES

1. Cohen Z, Volpin G, Shatkar H. Surgical treatment of displaced calcaneal fractures. European Instructional lectures, EFFORT. 2011;11:199-214.
2. Juliano PJ, Mayerson MS. Fractures of the hindfoot. In Foot and Ankle Disorders Mayerson MS (ed) WB Saunders Co. Philadelphia, London. Toronto, Sydney. 2000;1297-1340.
3. Kelikian AS, Jimenez ML. Fractures of calcaneus in Operative treatment of the Foot and Ankle, Kelikian AS (ed), Appleton and Lange, Stamford, Connecticut. 1999:389-416.
4. Bohler L, Diagnosis, pathology, and treatment of fractures of the os calcis, J Bone Joint Surg Am. 1931;13(1):75-89.
5. Rammelt S, Barthel S, Biewener A, Gavlik JM, Zwipp H. Calcaneus fractures: Open reduction and internal fixation. Zentrabl Chir. 2003;128:517-28.
6. Tennent TD, Calder PR, Salisbury RD, Allen PW, Eastwood DM. The operative management of displaced intraarticular fractures of the calcaneum: A two-center study using a defined protocol. Injury. 2001;32:491-6.
7. Bohler L, Diagnosis, pathology, and treatment of fractures of the os calcis, J Bone Joint Surg Am. 1931;13(1):75-89.
8. Gissane W. Discussion on Fractures of the os calcis. J Bone Joint Surg Am. 1947;29:254-55.
9. O'Farell DA, O'Byrne JM, McCabe JP, Stephens MM. Fractures of the os calcis: improved results with internal fixation. Injury. 1993;24(4):263-5.
10. Kitaoka HB, Alexander IJ, Adelaar RS, Nunley JA, Myerson MS, Sanders M. Clinical rating system for the ankle-hindfoot, midfoot, hallux, and lesser toes. Foot Ankle Int. 1994;15:349-53.
11. Essex-Lopresti P. The mechanism, reduction technique, and results in fractures of the os calcis. Br J Surg. 1952;39:395-419.
12. Crosby LA, Fitzgibbons T. Computerized tomography scanning of acute intra-articular fractures of the calcaneus: a new classification System. J Bone Joint Surg. 1990;72(6):852-9.
13. Sanders R. Displaced intra-articular fractures of the calcaneus. J Bone Joint Surg Am. 2000;82:225-50.
14. Buckley RE, Tough S, McCormack R. Operative compared with non-operative treatment of displaced intraarticular calcaneal fractures. A prospective, randomized, controlled multicentre trial. J Bone Joint Surg. 2002;84:1733-44.

**Cite this article as:** Kawade MS, Madan HS, Khachane S, Dhanda MS. Calcaneal fractures: a management dilemma-minimally invasive approach for intra and extra articular calcaneal fractures. Int J Res Med Sci 2019;7:756-60.