

## Case Report

# Listeria monocytogenes brain abscess in an immunocompromised patient: a case report

Vinit Suri<sup>1\*</sup>, S. Chatterjee<sup>2</sup>, Rohini Handa<sup>3</sup>, Swapnil Jain<sup>1</sup>, Mohit Kalangi Venkata Naga<sup>1</sup>, Kanika Suri<sup>4</sup>

<sup>1</sup>Department of Neurology, <sup>2</sup>Consultant Internal Medicine, <sup>3</sup>Consultant Rheumatology, <sup>4</sup>Department of Internal Medicine, Indraprastha Apollo Hospitals, New Delhi, India

**Received:** 24 May 2020

**Accepted:** 16 June 2020

### \*Correspondence:

Dr. Vinit Suri,

E-mail: [vinituri@hotmail.com](mailto:vinituri@hotmail.com)

**Copyright:** © the author(s), publisher and licensee Medip Academy. This is an open-access article distributed under the terms of the Creative Commons Attribution Non-Commercial License, which permits unrestricted non-commercial use, distribution, and reproduction in any medium, provided the original work is properly cited.

## ABSTRACT

*Listeria monocytogenes* is a facultative intracellular gram-positive bacillus which usually infects immunocompromised patients, though it can infrequently infect immunocompetent individuals, neonates and pregnant women as well. Neurological manifestations include meningitis and cerebritis. Brain Abscess is an extremely rare presentation with approximately 80 reported cases. Authors report a patient with a brain abscess identified on an MRI scan with positive blood culture for *Listeria monocytogenes*. Patient was managed conservatively with intravenous followed by oral antibiotics with resolution of the abscess.

**Keywords:** Abscess, Brain, *Listeria*

## INTRODUCTION

*Listeria monocytogenes* is a facultative intracellular gram-positive bacillus which was first reported as a blood stream infection in a 17-year-old boy in 1945.<sup>1</sup> It usually affects immunocompromised patients especially those with weakened cellular mediated immunity.

It may also affect immunocompetent individuals, pregnant women and patients with extremes of age. It is usually caused by ingestion of infected food, e.g. raw salads, inadequately cooked meat and unpasteurized dairy products.

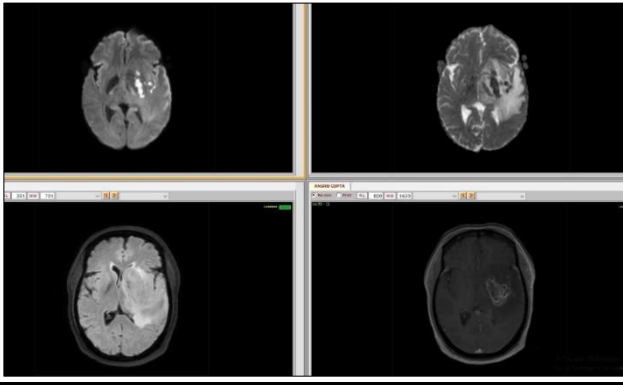
It can cause three types of clinical syndromes-bacteremia, neuro-listeriosis or maternal-neonatal infection. Meningitis and Meningoencephalitis account for the majority of *Listeria monocytogenes* CNS infections. Brain abscess is a rare manifestation of

*Listeria monocytogenes* and accounts for less than 10% of CNS infections.

## CASE REPORT

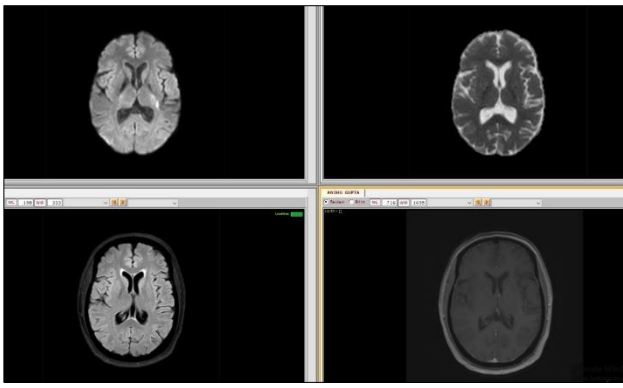
A 47-year-old Chartered Accountant, who had been hypertensive and hypothyroid since the past 5 years and was on Azathioprine and low dose steroids for more than 2 years for cryoglobulinemic vasculitis was admitted with a 3-day history of holocranial, non-throbbing, moderately severe headache, with low grade fever and two-day history of non-fluent speech. On admission, patient was conscious, though lethargic, was febrile with expressive aphasia and right hemiparesis (4/5) with extensor right plantar. Meningeal signs were not elicitable. MRI Brain (Figure 1) revealed multiple 8 -10mm size, coalescing ring enhancing lesions with moderate peri-lesional edema (contrast T1-image) in left fronto-parietal and adjoining basal ganglia regions, with heterogenous bright signal on

FLAIR with restricted diffusion within the lesion and loss of signal on ADC, with a midline shift to left of 5mm.



**Figure 1: Confluent ring enhancing lesions with perilesional edema, heterogenous bright signal on FLAIR, restricted diffusion within the lesion, loss of signal on ADC, midline shift to left of 5mm.**

Routine hematological and biochemistry work-up did not reveal any significant abnormality. Serum procalcitonin was  $<0.09$  and CRP was positive. Blood culture grew *Listeria monocytogenes* with sensitivity to ampicillin, gentamycin and vancomycin. Lumbar puncture revealed protein of 123.2 mg/dL, sugar level of 70mg/dL (corresponding blood sugar 132mg/dL) with cell count of 100 cells (20% lymphocytes and 80% neutrophils). Rapid meningitis molecular assay panel in CSF detected *Listeria monocytogenes*.



**Figure 2: Significant resolution of peripheral enhancing confluent nodular lesions, central FLAIR hyperintensity, central diffusion restriction, reversal on ADC.**

Patient was managed with intravenous ampicillin, vancomycin and IV gentamycin with settling of fever and gradual improvement of neurological deficit. Serial MRI's revealed gradual reduction in the size of abscess and edema. Patient was treated with IV antibiotics for 12 weeks following which there was near complete recovery of neurological deficit and marked resolution of the abscess and edema with repeat MRI revealing few peripheral enhancing confluent nodular lesions in left

medial and inferior temporal and left basal ganglia regions, showing central FLAIR hyperintensity, central diffusion restriction with reversal on ADC with significant regression in size and enhancement of lesions and mass effect (Figure 2).

## DISCUSSION

*Listeria monocytogenes* can invade the central nervous system or gravid uterus and fetus. The usual source of infection is infected food, e.g. salads, inadequately cooked meat or non-pasteurized dairy products. The bacillus penetrates the Peyer's patches of the small intestine and enters the blood stream via the mesenteric nodes.<sup>2</sup> It can cause bacteremia with endocarditis, arthritis, pneumonia, endophthalmitis or osteomyelitis or neuroinfection including meningitis, cerebritis and rarely cerebral abscess or maternal-neonatal infections.

*Listeria monocytogenes* usually affects immunocompromised patients especially those with impaired cell-mediated immunity including extremes of age, cancer, HIV infection, diabetes mellitus, cirrhosis, alcoholism, and those receiving immunosuppressive therapies especially agents like Azathioprine or prednisolone. Central nervous system infection may result from bacteremia and hematogenous spread or via retrograde axonal migration along the axons of the cranial nerves.<sup>3</sup> The commonest manifestation in the CNS is meningitis followed by cerebritis, meningoencephalitis and rhombencephalitis. Brain abscess is a rare manifestation of *Listeria monocytogenes* with approximately 80 cases described in literature.<sup>4-6</sup>

*Listeria* brain abscesses are characteristically located in the sub-cortical grey matter especially in basal ganglia, thalamus or pons.<sup>4,7</sup> Apart from its sub-cortical location, the diagnosis is usually based on a positive blood culture yielding *Listeria monocytogenes* which may be positive in up to 85% of cases.<sup>8</sup> This blood culture positivity is unusual in other patients with brain abscess. Lumbar puncture is less helpful in the diagnosis and a positive blood culture occurs more often than CSF isolation of *Listeria monocytogenes*. A subcortical location of abscess with positive blood culture with or without positive CSF PCR is sufficient enough to start empirical medical therapy for *Listeria monocytogenes* brain abscess and hence negating the necessity for a histological/microbiological diagnosis by a biopsy.

Treatment options are unresolved due to only a limited number of cases with uncertainty on various issues including surgical vs medical treatments, optimal antibiotic regime and optimal duration of treatment. Conservative antibiotic trial with a close clinic-radiological follow-up is usually the first line of management. Surgical intervention is required in patients with poor response to medical treatment, large abscess to start with and to confirm the infectious agent in patients with negative blood culture and negative CSF studies.

Treatment options for *Listeria monocytogenes* includes Ampicillin or sulfamethoxazole in penicillin allergic patients. Addition of an aminoglycoside, preferably gentamycin or adding vancomycin may be considered for synergy.<sup>9</sup> Antibiotics are continued for 3 weeks for meningitis and for 6-8 weeks or even longer as indicated by the patient's clinical and radiological response to the therapy in patients with brain abscess.

## CONCLUSION

*Listeria monocytogenes* cerebral abscess are rare and usually observed in patients with impaired cell-mediated immunity. They are usually sub-cortical in location and 85% patients have positive blood cultures which is sufficient to confirm the diagnosis. CSF PCR positivity is seen less often. Medical treatment with ampicillin and aminoglycoside for 6-8 weeks with close watch on clinical and radiological status is the corner stone of therapy and surgery is reserved for non-responders.

*Funding: No funding sources*

*Conflict of interest: None declared*

*Ethical approval: Not required*

## REFERENCES

1. Kaplan MM. Listerellosis. N Engl J Med. 1945;232:755-9.
2. Cone LA, Leung MM, Byrd RG, Annunziata GM, Lam RY, Herman BK. Multiple cerebral abscesses because of *Listeria monocytogenes*: three case reports and a literature review of supratentorial
3. Disson O, Lecuit M. Targeting of the central nervous system by *Listeria monocytogenes*. Virulence. 2012;3(2):213-21.
4. Tiri B, Priante G, Saraca LM, Martella LA, Cappanera S, Francisci D. *Listeria monocytogenes* Brain Abscess: Controversial Issues for the Treatment-Two Cases and Literature Review. Case Reports Infect Dis. 2018;65:494-96.
5. Frade HC, Pingili C, Nattanamai P. Multiple *Listeria* Abscesses in an Immunocompetent Patient. Cureus. 2020 Jan;12(1).
6. Flores-Perez RO, Villarreal-Villarreal CD, Cardenas-de La Garza JA, Galarza-Delgado DA. Supratentorial *Listeria monocytogenes* Brain Abscess in a Patient with Liver Cirrhosis. Ann Indian Acad Neurol. 2020 Jan;23(1):107.
7. Lorber B. Listeriosis. Clinical Infect Dis. 1997;24:1-11.
8. Coste JF, Duval V. Unusual location of a brain abscess due to *Listeria monocytogenes*. Pathol Biol (Paris). 2012 Oct;60(5):e45-8.
9. Al-Khatti AA, Al-Tawfiq JA. *Listeria monocytogenes* brain abscess in a patient with multiple myeloma. J Infect Dev Ctries. 4:849-51.

**Cite this article as:** Suri V, Chatterjee S, Handa R, Jain S, Naga MKV, Suri K. *Listeria monocytogenes* brain abscess in an immunocompromised patient: a case report. Int J Res Med Sci 2020;8:2663-5.