

Case Report

Thoracic outlet syndrome due to compression of subclavian artery at first rib

Akshay Hemant Shah*, Sudhanshu R. Vyas, Amit Dhond,
Ravindra G. Khedekar, Sunil H. Shetty

Department of Orthopaedics, D.Y. Patil University School of Medicine, Nerul, Navi Mumbai, Maharashtra, India

Received: 11 November 2014, **Revised:** 16 December 2014

Accepted: 17 December 2014

*Correspondence:

Dr. Akshay Hemant Shah,
E-mail: aki1986@gmail.com

Copyright: © the author(s), publisher and licensee Medip Academy. This is an open-access article distributed under the terms of the Creative Commons Attribution Non-Commercial License, which permits unrestricted non-commercial use, distribution, and reproduction in any medium, provided the original work is properly cited.

ABSTRACT

Thoracic Outlet Syndrome (TOS) refers to a constellation of signs and symptoms that arise from compression of the neurovascular bundle within the confined space of the thoracic outlet. Neurogenic (nTOS) from brachial plexus compression (95%), venous (vTOS) from subclavian vein compression (3%), & arterial (aTOS) from subclavian artery compression (1%). Most common clinical presentation of aTOS patients is distal upper extremity arterial emboli in otherwise healthy patient. Presenting a case report of arterial thoracic outlet syndrome.

Keywords: Thoracic outlet syndrome, Arterial thoracic outlet syndrome, aTOS, Compression of subclavian artery

INTRODUCTION

Thoracic Outlet Syndrome (TOS) refers to a constellation of signs and symptoms that arise from compression of the neurovascular bundle within the confined space of the thoracic outlet.

Neurogenic (nTOS) from brachial plexus compression (95%), venous (vTOS) from subclavian vein compression (3%), & arterial (aTOS) from subclavian artery compression (1%).

Most common clinical presentation of aTOS patients is distal upper extremity arterial emboli in otherwise healthy patient.

Same pathology involving the thoracic outlet, can be described under several headings, including cervical rib syndrome, scalene anticus syndrome, costoclavicular syndrome, and hyperabduction syndrome. The term "thoracic outlet syndrome" was coined to collectively

encompass the spectrum of syndromes related to thoracic outlet.

The clinical manifestations of thoracic outlet syndrome are mainly neurological. Although arterial complications are rare, they are potentially severe. Among these are aneurysms associated with embolism and thrombosis.

The expression "Thoracic Outlet Syndrome" (TOS) was first used by Peet to describe patients with neurovascular symptoms relative to possible sites of compression of the neurovascular bundle, which are basically three: interscalene triangle, costoclavicular space and retropectoralis minor space.

CASE REPORT

We report the case of a 21-year-old male patient with arterial thoracic outlet syndrome.

Patient presented with pain, bluish discoloration (cyanosis), pallor and decreased sensation (paraesthesia)

and numbness of distal part of right thumb since 15 days (Figure 1). He had no complaints of previous paraesthesia in the upper limb. He had no comorbidity, was not a smoker.

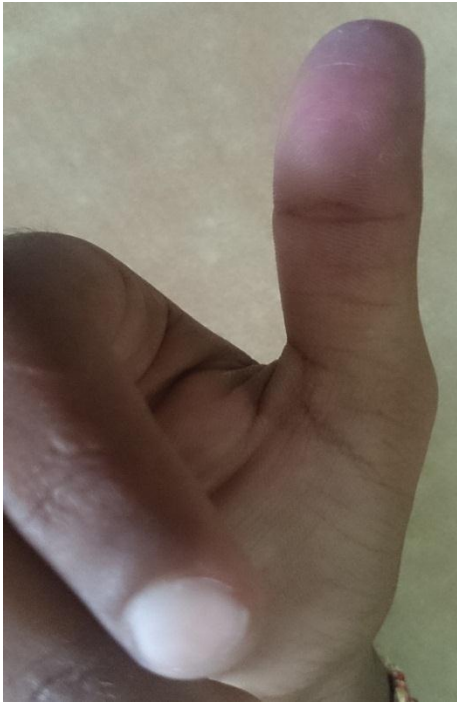

Figure 1: Pre-operative.

On physical examination, patient had tenderness, cyanosis, pallor, paraesthesia and numbness over pulp of right thumb. Adson's test and hyper abduction manoeuvre were found to be positive. Allen's Test was negative.

X-ray chest (Figure 2) and cervical spine (Figure 3) were found to be normal.

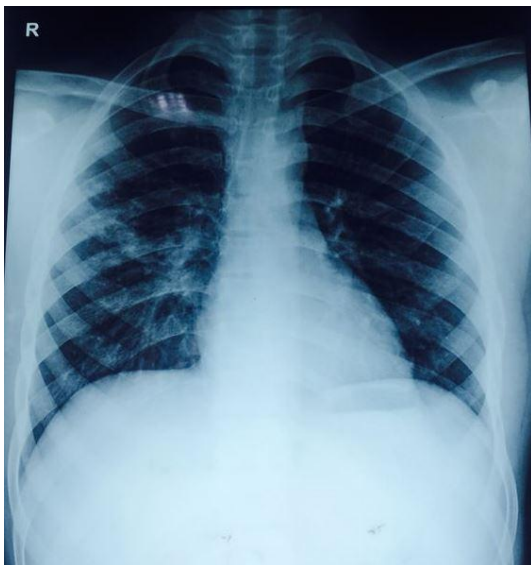


Figure 2: Chest X-ray.

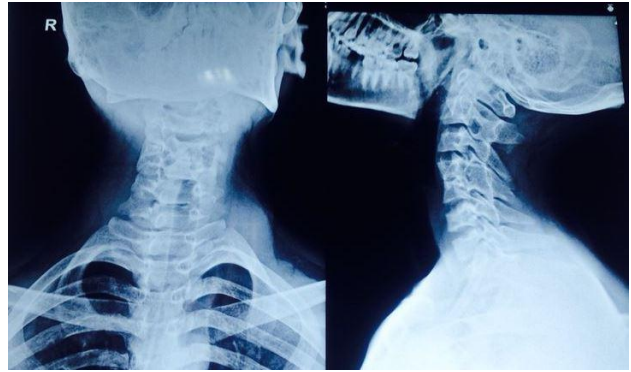


Figure 3: Cervical spine X-ray.

Right upper limb arterial Doppler was not contributory. It showed normal study i.e. normal flow in all major vessels.

CT contrast angiogram of bilateral upper limb showed the superior cortex of right 1st rib is indenting the 3rd part of subclavian artery causing focal short segment narrowing of the subclavian artery (Figure 4 and 5).

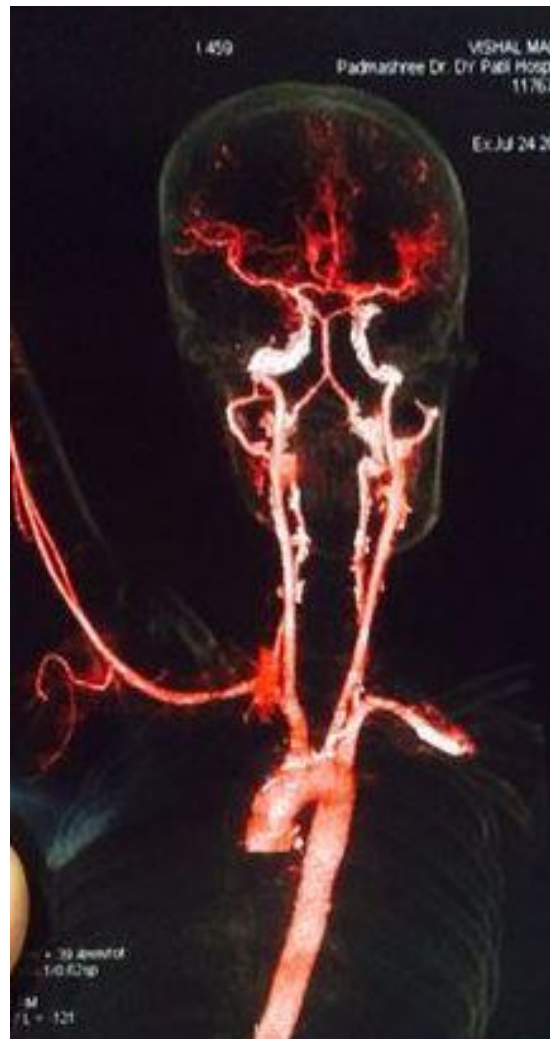


Figure 4: CT angiography.

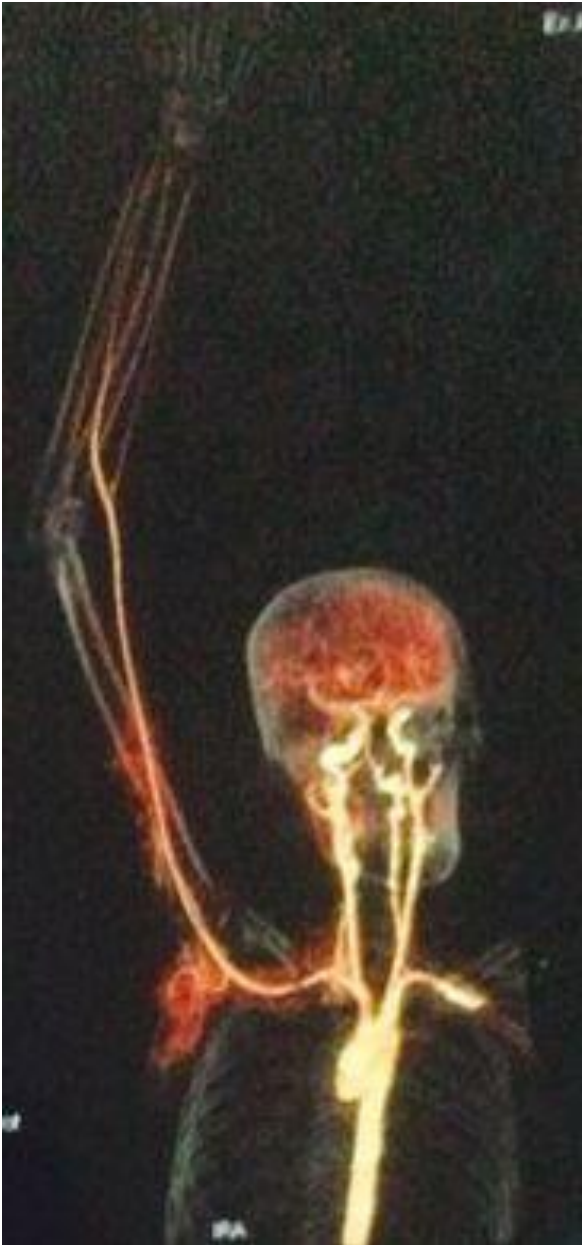

Figure 5: CT angiography.

Surgery

We did resection of right 1st rib by trans-axillary approach. The patient's course was satisfactory and uneventful in the postoperative period (Figure 6 and 7).

Follow up at 1 month post-surgery showed relief from symptoms.

On follow up patient had no pain or numbness in the distal part of right thumb, sensations and colour of the skin had returned back to normal.

Arterial Thoracic Outlet Syndrome (aTOS) although difficult to diagnose due to its rare presentation should be diagnosed and treated as early as possible.

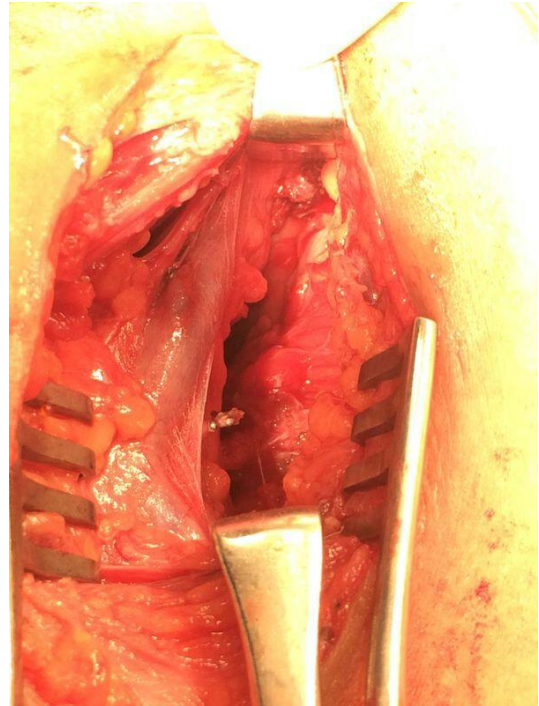


Figure 6: Intra operative.

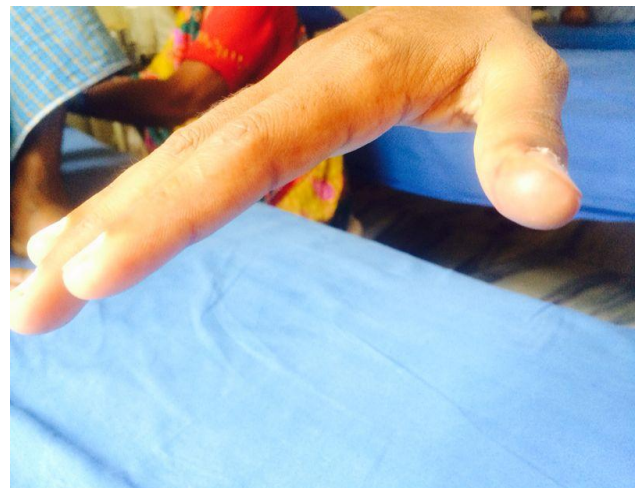

Figure 7: Post-operative.

DISCUSSION

Cervical ribs and the first anomalous rib are rare conditions, present in approximately 1% of the population and in 4.5% of patients with TOS. They are usually findings of imaging examinations, such as chest X-rays. Most are completely asymptomatic, and rarely require treatment.

Clinical manifestations comprehend a wide range of symptoms, and not all are necessarily present in the clinical status of each patient.

Arterial lesions in TOS are usually due to bone abnormalities.

Presence of anomalous first rib and muscle changes increases probability of arterial lesion and embolic phenomena.

The need of early detection of lesions caused by emboli at an early stage is extremely important, and all patients with first rib abnormalities or with cervical rib should be regularly followed using Doppler ultrasound of the subclavian-axillary segment.

Chest and cervical spine X-rays are extremely important to reveal bone changes.

Computed tomography can be useful in the TOS diagnosis, especially in patients in whom X-rays are normal. Magnetic resonance has proved to be efficient in showing fibrotic bands and deviation of the brachial plexus in patients without cervical rib.

The treatment of this disease can be conserved through physical therapy, rest of the activity that caused the symptoms and analgesia.

Surgical treatment should be indicated in cases of failure in clinical treatment (after 6 months without improvement or symptom recurrence), uncontrolled pain and paraesthesia, in addition to vascular impairment (pallor, reduced pulses, cyanosis, Raynaud's phenomenon, limb claudication or pain at rest or ulcers).

There are two surgical techniques for correction: supraclavicular and transaxillary approach.

One of the main complications of the surgery has been the phrenic nerve lesion, subclavian artery and vein lesions. Pneumothorax has also been reported.

TOS is a common disease that has complex anatomy and a large anatomical variation of structures, which should be managed by a specialized team and vascular surgeon experienced in this type of surgery.

Funding: No funding sources

Conflict of interest: None declared

Ethical approval: Not required

REFERENCES

1. Peet RM, Hendriksen JD, Anderson TP, Martin GM. Thoracic-outlet syndrome: evaluation of therapeutic exercise program. Proc Staff Meet Mayo Clin. 1956;31:281-7.
2. Sanders RJ, Roos DB. The surgical anatomy of the scalene triangle. Contemp Surg. 1989;35:11-6.
3. Short DW. The subclavian artery in 16 patients with complete cervical ribs. J Cardiovasc Surg (Torino). 1975;16:135-41.
4. Sanders RJ, Hammond SL. Management of cervical ribs and anomalous first ribs causing neurogenic thoracic outlet syndrome. J Vasc Surg. 2002;36:51-6.
5. Sanders RJ, Pearce WH. The treatment of thoracic outlet syndrome: a comparison of different operations. J Vasc Surg. 1989;10:626-34.
6. Durham JR, Yao JS, Pearce WH, Nuber GM, McCarthy WJ 3rd. Arterial injuries in the thoracic outlet syndrome. J Vasc Surg. 1995;21:57-70.
7. Cormier JM, Amrane M, Ward A, Laurian C, Gigou F. Arterial complications of the thoracic outlet syndrome: fifty-five operative cases. J Vasc Surg. 1989;9:778-87.
8. Mackinnon SE, Novak CB. Evaluation of the patient with thoracic outlet syndrome. Semin Thorac Cardiovasc Surg. 1996;8:190-200.
9. Komanetsky RM, Novak CB, Mackinnon SE, Russo MH, Padberg AM, Louis S. Somatosensory evoked potentials fail to diagnose thoracic outlet syndrome. J Hand Surg [Am]. 1996;21:662-6.
10. Reilly LM, Stoney RJ. Supraclavicular approach for thoracic outlet decompression. J Vasc Surg. 1988;8:329-34.

DOI: 10.5455/2320-6012.ijrms20150166

Cite this article as: Shah AH, Vyas SR, Dhond A, Khedekar RG, Shetty SH. Thoracic outlet syndrome due to compression of subclavian artery at first rib. Int J Res Med Sci 2015;3:338-41.