

Research Article

High division of sciatic nerve

Tripti Shrivastava*, Lalit Garg, B. K. Mishra, Neeta Chhabra

Department of Anatomy, Army College of Medical Sciences (ACMS), New Delhi, India

Received: 8 March 2014

Accepted: 5 April 2014

***Correspondence:**

Dr. Tripti Shrivastava,

E-mail: drtriptishrivastava@gmail.com

© 2014 Shrivastava T et al. This is an open-access article distributed under the terms of the Creative Commons Attribution Non-Commercial License, which permits unrestricted non-commercial use, distribution, and reproduction in any medium, provided the original work is properly cited.

ABSTRACT

Background: The Sciatic nerve is the largest and thickest nerve in the human body with a long course in the inferior extremity. It divides into tibial and common peroneal nerves which can occur at any level from the sacral plexus to the inferior part of the popliteal space. Sciatic nerve variations are relatively common. These variations may contribute to clinical conditions ex sciatica, coccygodynia and piriformis syndrome and have important clinical implications in anaesthesiology, neurology, sports medicine and surgery.

Methods: 10 cadavers were dissected with no previous history of trauma/surgery to study the anatomical variations of sciatic nerve.

Results: In all except two cadavers, the nerve divided at the apex of the popliteal fossa. In two cadavers the sciatic nerve divided bilaterally in the upper part of thigh.

Conclusion: The high division presented in this study can make popliteal nerve blocks partially ineffective. The high division of sciatic nerve must always be borne in mind as they have important clinical implications.

Keywords: Sciatic nerve, Tibial nerve, Common peroneal nerve

INTRODUCTION

Sciatic nerve is the longest and thickest nerve in the human body. It is often approached in clinical settings in the context of trauma, tumors, vascular lesions in neighbouring structures, entrapment syndromes, hip or femur surgery or percutaneously for lower limb anaesthetic block.¹⁻⁴ Due to potential anatomical variants, the study of sciatic nerve variations on cadavers is important esp. for clinicians planning intervention around the sciatic nerve and its division in the lower extremity.

Par⁵ described in detail about the sciatic nerve as early as in the 16th century but it was in the 19th century that Cruveilhier recognized that sciatic nerve could divide anywhere from sacral plexus to the popliteal fossa.⁶

METHODS

10 cadavers (08 males & 02 females) embalmed and formalin fixed were carefully dissected from gluteal region to the leg in the Anatomy Department of Army College Of Medical Sciences, Delhi Cantt. None had a prior history of lower limb trauma or surgery.

In two cadavers the sciatic nerve divided bilaterally into its two terminal branches - the tibial and common peroneal nerve in the upper part of the posterior compartment of the thigh (Figure 1A & 1B). Anatomical variations were observed and photographed (Figure 2A & 2B). No significant difference was observed in the level where the nerve divided between male and female cadavers.

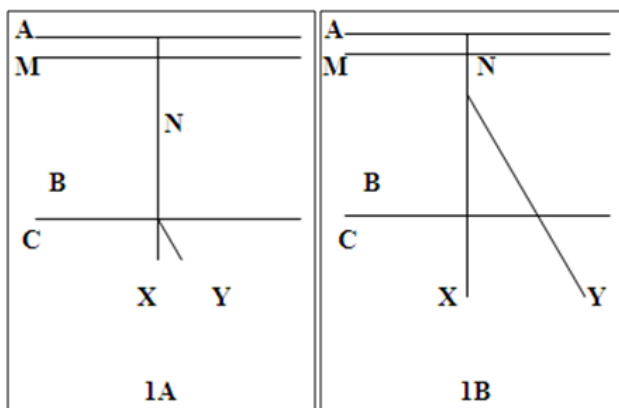


Figure 1A & 1B: Showing illustration of sciatic nerve as in standard text books (1A) and as in the present case (1B).

A - Gluteal region, B - Back of thigh, C - Popliteal fossa,

M - Piriformis muscle, N - Sciatic nerve, X - Tibial nerve,

Y - Common peroneal nerve



Figure 2A & 2B: Showing dissection of the gluteal region, back of thigh and popliteal fossa.

1 - Sciatic nerve, 2 - Tibial nerve, 3 - Common peroneal nerve,

4 - Piriformis, 5 - Obturator internus & gemelli,

6 - Gluteus maximus, 7 - Biceps femoris

RESULTS

In two out of ten cadavers (n=20) the nerve divided into its terminal branches in the upper part of posterior compartment of the thigh. The muscles of the posterior compartment of the thigh derived their nerve supply from tibial nerve while the short head of the biceps femoris was innervated by the common peroneal nerve.

DISCUSSION

Sciatic nerve may divide in its terminal branches from its origin in the pelvic region until the popliteal fossa. There are numerous reports in the literature of terminal division of sciatic nerve in almost every point between these two anatomical regions.^{2,4}

There is enough reference in the literature that the numerous variants of the sciatic nerve most likely result from a stochastic process of separation of the primitive elements of the sciatic nerve.^{2,7-9,10} The lower limb is initially associated with the primitive lumbar and sacral plexuses.¹⁰ Later as the elements from each of these plexuses grow out into the limb, they are subdivided into dorsal and ventral components for the dorsal and ventral musculatures.¹¹ The sciatic nerve is formed when the large dorsal component of the sacral plexus (common peroneal nerve) and the ventral component (tibial nerve) move down close together.¹¹ It is possible however that the two components separate from each other at different levels from their origins; in the gluteal region, the posterior compartment of the thigh as observed in this study or the popliteal fossa. An important consequence of the high division of sciatic nerve is that it leads to the failure of popliteal block anaesthesia.¹²⁻¹³ Additionally in high division of sciatic nerve there may be involvement of only one of the two terminal branches of the nerve in sciatic neuropathy giving rise to atypical sciatic compressive syndromes.¹

CONCLUSION

The anatomical variants associated with division of sciatic nerve must always be borne in mind as they are relatively prevalent and have important clinical implications in anaesthesiology, neurology, sports medicine and surgery.

Funding: No funding sources

Conflict of interest: None declared

Ethical approval: Not required

REFERENCES

1. Prakash, Bhardwaj AK, Devi MN, Sridevi NS, Rao PK, Singh G. Sciatic nerve division: a cadaver study in the Indian population and review of the literature. Singapore Med J. 2010;51:721-3.
2. Pokomy D, Jahoda D, Veigl D, Pinskerova V, Sosna A. Topographic variations of the relationship of the Sciatic nerve and the piriformis muscle and its relevance to palsy after total hip arthroplasty. Surg Radiol Anat. 2006;28:88-91.
3. Schwemmer U, Markus CK, Greim CA, Brederlau J, Trautner H, Roewer N. Sonographic imaging of the sciatic nerve and its division in the popliteal fossa in children. Paediatr Anaesth. 2004;14:1005-8.
4. Schwemmer U, Markus CK, Greim CA, Brederlau J, Kredel M, Roewer N. Sonographic imaging of the sciatic nerve division in the popliteal fossa. Ultraschall Med. 2005;26:496-500.
5. Diogo Pais et al. Sciatic nerve high division: two different anatomical variants. Acta Med Port. 2013;26(3):208-11.
6. Cruveilhier J. Traite. The anatomy descriptive. In: Cruveilhier J. Traite, eds. Angelogie et Neurologie. 4th ed. Paris: Asselin et Labe; 1871: 652.

7. Pecina M. Contribution to the etiological explanation of the piriformis syndrome. *Acta Anat.* 1979;105(2):181-7.
8. Beaton LE. The relation of the sciatic nerve and its subdivisions to the piriformis muscle. *Anat Rec.* 1937;70:1-5.
9. Mouret J. Rapports des muscles pyramidaux avec le nerf sciatique. *Montpe L Med.* 1893;2:230-3.
10. Davut O, Yakup G, Sevgi B, Senoglu M, Kalender AM, Calik M. The topographical features and variations of nervus ischiadicus in human fetuses. *Bratisl Lek Listy.* 2011;112:475-8.
11. Demiyurek D, Bayramoglu A, Erbil M, Aldur MM, Mustafa ES. Bilat divided piriformis muscle together with the high division of the sciatic nerve. *Gazi Med J.* 2002;13:41-4.
12. Vloka JD, Hadzic A, April E, Thys DM. The division of the sciatic nerve in the popliteal fossa: anatomical implications for popliteal nerve blockade. *Anaesth Analg.* 2001;92:215-7.
13. Nayak S. An unusual case of trifurcation of the sciatic nerve. *Neuroanat.* 2008;5:6-7.

DOI: 10.5455/2320-6012.ijrms20140559

Cite this article as: Shrivastava T, Garg L, Mishra BK, Chhabra N. High division of sciatic nerve. *Int J Res Med Sci* 2014;2:686-8.