

## Case Report

# Indian common krait envenomation presenting as fulminant myocarditis and coma: a case report

Vijay Kumar Verma<sup>1\*</sup>, Vijender Maurya<sup>2</sup>, Rajesh Verma<sup>3</sup>

<sup>1</sup>Department of Medicine, UPRIMS&R, Saifai, Etawah, U.P., India

<sup>2</sup>Department of Neurosurgery, UPRIMS&R, Saifai, Etawah, U.P., India

<sup>3</sup>Department of Microbiology, UPRIMS&R, Saifai, Etawah, U.P., India

**Received:** 3 August 2014

**Accepted:** 19 August 2014

**\*Correspondence:**

Dr. Vijay Kumar Verma,

E-mail: vermavk79@gmail.com

**Copyright:** © the author(s), publisher and licensee Medip Academy. This is an open-access article distributed under the terms of the Creative Commons Attribution Non-Commercial License, which permits unrestricted non-commercial use, distribution, and reproduction in any medium, provided the original work is properly cited.

### ABSTRACT

Fulminant myocarditis is an unusual manifestation of cardiotoxicity with severe elapid snake envenoming and is meagrely reported with snake bite due to Indian common krait. We report a 12-year-old boy who was admitted in complete locked-in state and hemodynamic instability after severe neurotoxic snake envenoming by *Bungarus caeruleus* (Indian common krait). His hospital course was complicated with recurrent episodes of sustained ventricular tachycardia requiring defibrillation; and cardiogenic shock requiring inotropes, vasopressors and intraaortic balloon counterpulsation. Severe heart failure features secondary to fulminant toxic myocarditis persisted even after full neurological recovery requiring prolonged standard medical heart failure therapy. Patient subsequently achieved full clinical recovery and regained normal left ventricular systolic function. We also reviewed the literature on cardiac manifestations, possible mechanisms and treatment of patients with cardiotoxicity due to elapid snake bites. The importance of anticipating severe cardiovascular complications is highlighted to help formulate appropriate therapeutic strategy.

**Keywords:** *Bungarus caeruleus*, Cardiotoxicity, Cardiogenic shock, Envenoming, Fulminant myocarditis, Heart failure, Indian common krait, Neurotoxicity, Neuroparalysis, Ophthalmoplegia, Snake antivenin

### INTRODUCTION

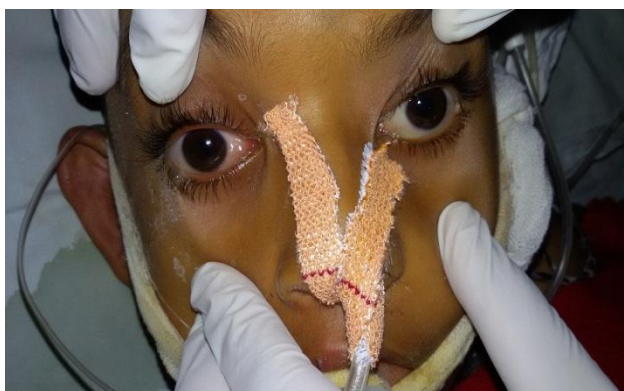Snake bite envenomation is a common, acute life-threatening medical emergency in India. An estimated 40900-50900 people die of snake bite every year in India.<sup>1</sup> Neurotoxic snake envenoming is the most important cause of snake bite fatality and is mainly due to the Elapidae family, which includes the genera *Naja* and *Bungarus* commonly referred to as the cobras and the kraits respectively.<sup>2</sup> Factors contributing to a fatal outcome include improper use of antivenin therapy, delayed transportation, loss of valuable times with traditional local healers ("baighis"), inadequate artificial ventilation, failure to treat hypovolemia in shocked patients, airway obstruction, complicating secondary

infections, and inadequate hemodynamic monitoring.<sup>3</sup> Indian common krait (*Bungarus caeruleus*), the most poisonous snake with its venom being ten times more poisonous than cobras venom,<sup>4</sup> is well known for inflicting bites on sleeping people inside their homes and causing long-lasting severe neuromuscular paralysis with high mortality in the absence of signs of significant local envenoming.<sup>5</sup> Though severe neurotoxic snake envenoming may mimic brain death or a locked-in state with absent reflexes and total ophthalmoplegia, patients who receive antivenin therapy and ventilator support in time may recover completely.<sup>6</sup> Cardiac involvement is an infrequently recognized manifestation of snake bite; seen mainly with viperine bites and has been uncommonly reported with elapid bites. Moreover, it has been reported

to occur only with cobra bites.<sup>7</sup> Here, we report the clinical details of a case of severe envenoming as a result of Indian common krait bite with unusual complications such as fulminant myocarditis and locked-in state with total ophthalmoplegia.

## CASE REPORT

A twelve-year-old previously healthy boy was admitted to the emergency department of our institute on 17<sup>th</sup> of May 2014 at 3:08 AM in unconscious state six hours after being bitten by a snake at multiple sites: right forearm, back and scalp, in the middle of night while sleeping on a cot at home. On arrival, patient was in complete locked-in state with Glasgow Coma Scale (GCS) of three. He was cyanosed, tachypneic and diaphoretic with pulse rate of 150/min, respiratory rate of 36/min and systolic blood pressure of 80 mmHg. He was promptly intubated and put on mechanical ventilation with an ambu bag and measures to stabilize the patient instituted. Patient was immediately shifted to the medical ICU after resuscitation. Thorough clinical evaluation revealed features of shock in form of diaphoresis, cold clammy extremities and hypotension; features of congestive cardiac failure in form of distended neck veins, S3 gallop rhythm and bilateral basilar rales. Neurological examination revealed total ophthalmoplegia with absent papillary, vestibulo-ocular and corneal reflexes; features of bulbar palsy and flaccid quadriplegia (Figure 1). Local examination revealed clearly-defined fang marks on right forearm, back and head near right ear without any feature of local envenomation.



**Figure 1: Photograph of patient showing total ophthalmoplegia.**

The diagnosis of severe krait envenoming was secured based on the clinical syndrome of snake bite with neurotoxicity in the absence of features of local envenoming and was confirmed with inspection of genus-specific external features<sup>8</sup> of the dead snake brought by patient's relatives. As per the national snake bite protocol, 100 ml of polyvalent antivenin (Biologicals E limited, Hyderabad) diluted in 200 ml of normal saline was intravenously infused over one hour without any immediate complications. In view of deteriorating

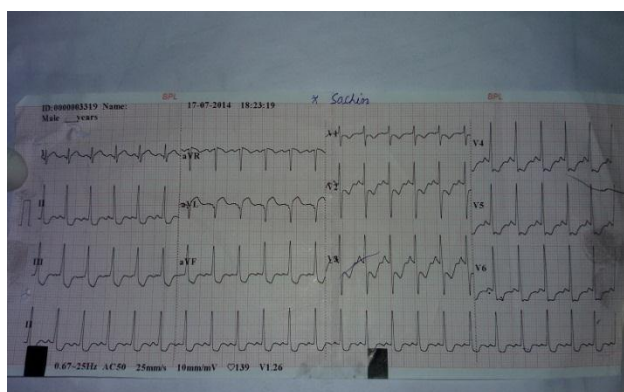
neurotoxicity, additional dose of 100 ml of polyvalent antivenin was repeated after one hour without any signs of adverse reaction. Atropine (0.6 mg i.v.) was given followed 10 minutes later by neostigmine (0.04 mg/kg i.m.). Three additional doses of atropine and neostigmine were given at half-hour intervals without any improvement in neurological status.

In medical ICU, patient continued to receive mechanical ventilation with the assist control mode (tidal volume 320 ml, respiratory frequency of 15/min, FiO<sub>2</sub> 100%, positive end-expiratory pressure (PEEP) of 5, peak and plateau pressure of 18 cm and 12 cm of water respectively. Hypotension was managed with escalating doses of vasopressors and judicious use of intravenous fluids with close monitoring of Pulmonary Capillary Wedge Pressure (PCWP) through a centrally placed PA catheter advanced to the "wedge position" via antecubital vein. On achieving hemodynamic stabilization, patient received small doses of loop diuretics (furosemide 20 mg i.v. q 8h) to relieve pulmonary congestion. Patient also received stress ulcer and deep venous thrombosis prophylaxis along with other supportive care. Baseline biochemistry, hematological, arterial blood-gas analysis and other relevant investigations are presented in Table 1 and were within normal limits except elevated cardiac specific troponin I and creatine kinase-MB as an evidence of myocardial damage and mild metabolic acidosis. Baseline ECG revealed diffuse ST segment depression and T wave changes (Figure 2). Baseline screening 2-dimensional echocardiography performed in view of cardiogenic shock revealed normal Left Ventricular End Diastolic Dimension (LVEDD, 43 mm); increased Inter Ventricular Septal thickness in Diastole (IVSD, 13 mm); severe left ventricular global hypokinesia with LVEF of 22% using biplane modified Simpsons method and no evidence of valvular abnormalities or pulmonary hypertension.

**Table 1: Hematological and biochemical data on admission.**

Parameter	Value	Parameter	Value
WBC	14200/cmm	S. Cr	0.7 mg/dl
RBC	539*(10) <sup>4</sup> /cmm	BUN	17.7 mg/dl
Hb	14.5 gm/dl	Na	136 mmol/L
PLT	29.8*(10) <sup>4</sup> /cmm	K	4.8 mmol/L
AST	84 IU/L	Mg	2.86 mg/dl
ALT	36 IU/L	CRP	1.97 mg/dl
LDH	682 IU/L	S. pH	7.31
CK-MB	147 IU/L	S.HCO <sub>3</sub>	15 meq/l
Troponin-I	80 ng/ml	PaCO <sub>2</sub>	32 mmHg

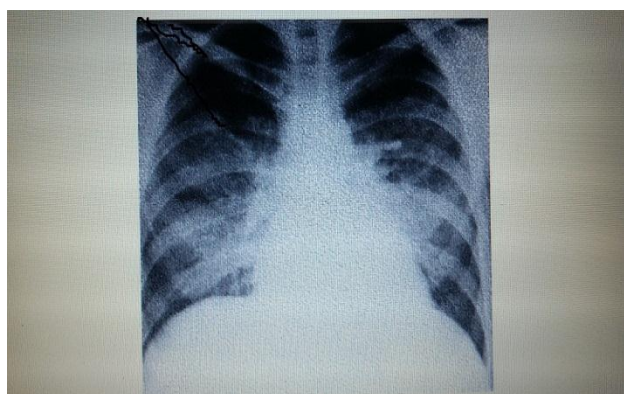
WBC - White cell count; RBC - Red blood cell counts; Hb - Hemoglobin; PLT - Platelet count; AST - Aspartate transaminase; ALT - Alanine transaminase; CK-MB - Creatine kinase MB; Cr - Creatinine; BUN - Blood urea nitrogen; Na - Sodium; K - Potassium; Mg - Magnesium; CRP - C-reactive protein; HCO<sub>3</sub> - Bicarbonate.



**Figure 2: ECG of the patient showing diffuse ST-T wave changes.**

Patient continued to be unresponsive to the above mentioned treatment. On third day of hospitalization, patient had recurrent episodes of sustained ventricular tachycardia. Patient was immediately given direct current biphasic shock thrice (200J, 360J, 360J) without any result; 150 mg of amiodarone was given as an i.v. bolus over 10 minutes after which a fourth DC shock (360J) was required before reversion to sinus rhythm which was maintained with continuous intravenous infusion of amiodarone over next 24 hours (1 mg/min for 6 hours, then 0.5 mg/min for next 18 hours).

Patient's general condition and hemodynamics worsened following episodes of ventricular tachycardia; and he developed pulmonary edema diagnosed by excessive frothy secretions from the endotracheal tube, sudden increase in peak inspiratory pressure, fall in paO<sub>2</sub> and confirmed with consistent chest X-ray findings (Figure 3); developed metabolic acidosis requiring bicarbonate therapy and again became hypotensive requiring re-institution of inotropic therapy. Intra-Aortic Balloon Pump (IABP) was also temporarily required to support hemodynamics. On achieving hemodynamic stabilization and adequate urine output, pulmonary edema was treated with small doses of loop diuretics (furosemide 20 mg i.v. q 8h).



**Figure 3: Chest radiograph shows bilateral alveolar opacities suggestive of pulmonary oedema.**

Patient remained comatose for next 7 days and showed no signs of improvement in neurological status. On 8<sup>th</sup> day of hospitalization, we noticed slight papillary constriction to bright light. Subsequently, over the next four days, patient had gradual improvement in ophthalmoplegia with vertical movements recovering before horizontal movements. Simultaneous recovery of muscle power of the extremities was also noted with the patient being able to move the fingers of his right hand voluntarily. Higher mental functions appeared to be intact as the patient responded to commands by blinking his eyes and moving his fingers. Mechanical ventilation was continued for another five days due to persistent respiratory muscle weakness complicated with ventilator associated pneumonia which was managed with appropriate broad spectrum antibiotics. After a lengthy period of hospitalization for 17 days, we were successful in weaning off the mechanical ventilation.

Though patient achieved full neurologic recovery, he continued to have features of congestive heart failure in form of exertional dyspnea and signs of systemic as well as pulmonary congestion despite ongoing optimal standard heart failure medical therapy. We continued anti congestive measures for next fifteen days with serial 2D-ECHO assessment of left ventricular systolic function. Patient markedly improved clinically in another seven days with pre-discharge 2D-ECHO revealing substantial improvement of LV systolic function with no regional or global hypokinesia and almost normal LV systolic function (LVEF: 54%). Patient remained asymptomatic on subsequent follow-up visit after one month and heart failure therapy was discontinued.

## DISCUSSION

The patient was categorized to have severe neurotoxic snake envenoming because of the presence of acute neuromuscular respiratory failure.<sup>9</sup> The clinical profile of distinct onset of severe and acute heart failure with cardiogenic shock; severe left ventricular systolic dysfunction in form of severely depressed LV Ejection-Fraction (LVEF) on echocardiography; temporal relation to elapid (Bungarus) bite; absence of other possible causes of acute cardiovascular compromise such as illicit drug abuse and other underlying cardiovascular disorders such as valvular heart disease or family history of cardiomyopathy; and complete recovery following successful treatment of the snake bite; suggested myocardial involvement consequent to krait envenoming. The presence of diffuse, non-specific ST-T wave changes; elevated biomarkers of myocardial necrosis; global LV hypokinesia and recurrent episodes of sustained ventricular tachycardia requiring defibrillation; further suggested that all these manifestations were secondary to venom-induced toxic myocarditis.

While the post-defibrillation elevation of CK-MB and Troponin-I values largely reflect this intervention, we had got samples for assessment of biomarkers of myocardial



necrosis much before the occurrence of episodes of VT. Therefore, elevated values of these biomarkers indicated that myocardial damage had already existed. In view of the age of patient, absence of atherosclerotic risk factors, static ST-T wave changes in serial ECG tracings, global rather than regional LV wall motion abnormality revealed by the 2D-echocardiography and near normalization of pre-discharge LV systolic function (LVEF 54%), we ruled out the possibility of acute coronary syndrome secondary to hypoxia and hemodynamic stress.

Other possible causes which could explain the clinical syndrome include non-cardiogenic pulmonary edema secondary to antivenin therapy. However, this entity generally occurs within six hours of antivenin therapy and could be safely excluded as features of pulmonary congestion were present since the time of admission. The use of cardiodepressive drugs such as benzodiazepines during mechanical ventilation could also trigger pulmonary congestion. Other contributory factors to the clinical syndrome include aspiration and/or mucous plugging with consequent poor ventilation; severe sepsis; acute pituitary or adrenal insufficiency and pulmonary embolism in the setting of prolonged immobilization.

Though cardiotoxicity has been recognized as a feature of snake envenoming, it is the neuromuscular paralysis and respiratory failure with elapid bites, and coagulation abnormalities with viperine bites, which dominate the clinical picture. Nayak et al. have documented a range of cardiac manifestations in patients with snake bite. Infact, 30% of the patient population studied had evidence of cardiac toxicity in form of disturbances in heart rate (47%); rhythm abnormalities (6.7%); hypertension (6.7%) and hypotension (6.7%). Electrocardiographic abnormalities documented included sinus tachycardia, sinus bradycardia, wide range of arrhythmias, tall T-waves, non-specific ST-T wave changes and atrio-ventricular blocks. However, only one patient of total 30 patients studied had features of pulmonary congestion. Moreover, the study was dominated by viperine bites (93%).<sup>10</sup> Clinically significant cardiac abnormalities have been rarely reported in patients with elapid bites. In a retrospective series of 67 patients in our institute and elsewhere in India, with severe neurotoxic envenoming secondary to elapid snake bites, we found no clinically significant cardiac involvement. To the best of our knowledge, there are very few case-reports in English literature on cardiotoxicity in form of fulminant myocarditis leading to severe acute heart failure and cardiogenic shock requiring prolonged inotropic and temporary IABP support.

Early myocardial damage in a young krait-bite victim with no previous heart disease suggests the possibilities that Bungarus caeruleus venom may contain a myriad of myotoxic and/or cardiotoxic factors, which can cause morphological changes; enzyme alterations; ultra-structural disturbances and genetic alterations of the myocardial tissue.<sup>11</sup> Thus, it is possible that krait

envenoming may cause a variable degree of muscle damage including cardiac myocytes that remains unnoticed in most cases because of the predominant syndrome of severe neuromuscular paralysis and the relative rarity with which creatine kinase and Troponin assays are performed in such patients.

There are no specific therapeutic guidelines regarding management of venom-induced fulminant toxic myocarditis in patients with severe snake envenoming. Though we did not use any specific therapy in form of corticosteroids or immunoglobulins for myocarditis, our patient achieved excellent clinical recovery with antivenin therapy along with standard medical therapy for heart failure and adopting appropriate ventilator strategy.

The observed lack of response to acetylcholinesterase inhibitor (neostigmine) therapy in patients with krait-bite could be explained by the mechanism of action of their most lethal venom-component, beta-bungarotoxins which cause acute denervation of muscle fibres by destruction of motor nerve terminals.<sup>12</sup> However, there have been cases of severe krait envenoming where patients apparently benefitted from neostigmine treatment. Such differences in response to this therapy may be explained by the variability in the venom composition, in particular by variable proportions of pre-synaptically acting beta-bungarotoxins and post-synaptically acting alpha-bungarotoxins in the krait venom.<sup>13</sup> Thus a single test dose of anticholinesterase inhibitor drug is recommended preferably using a short-acting drug (e.g. edrophonium chloride), if available.<sup>14</sup>

## CONCLUSION

In conclusion, our case serves to underscore the fact that the cardiac involvement in form of fulminant toxic myocarditis leading to the syndrome of distinct onset of severe and acute heart failure and cardiogenic shock can be the presentation of severe krait envenoming along with features of severe neurotoxicity. Such patients usually improve with standard therapy alone with excellent long-term prognosis. Every emergency physician and intensivist should be cautious enough to anticipate this potentially fatal complication of severe krait envenoming and routinely monitor the patient with serial ECG, cardiac biomarkers and screening 2D-echocardiography to assess left ventricular function especially in case of hemodynamic compromise so that appropriate therapeutic measures can be instituted in time to improve clinical outcomes.

*Funding: No funding sources*

*Conflict of interest: None declared*

*Ethical approval: Not required*

## REFERENCES

1. Mohapatra B, Warrell DA, Suraweera W, Bhatia P, Dhingra N, Jotkar RM, et al. Snake bite mortality in

- India: a nationally representative mortality survey. *PLoS Negl Trop Dis.* 2011;5:e1018.
2. Agarwal R, Singh N, Gupta D. Is the patient brain-dead? *Emerg Med J.* 2006;23:e5.
3. Warrell DA. WHO/SEARO Guidelines for the clinical management of snake bites in the Southeast Asian region. *Southeast Asian J Trop Med Public Health.* 1999;30(Suppl 1):1-85.
4. Lalitha V. Pillai, Dhananjay Ambike, Saifuddin Husainy, Anil khair, Ashok Captain, Ulrich Kuch. Severe neurotoxic envenoming and cardiac complications after the bite of a 'Sind Krait' (*Bungarus cf. sindanus*) in Maharashtra, India. *Trop Med Health.* 2012;40(3):103-8.
5. Agrawal PN, Aggarwal AN, Gupta D, Behera D, Prabhakar S, Jindal SK. Management of respiratory failure in severe neuroparalytic snake envenomation. *Neurol India.* 2001;49:25-8.
6. Singh G, Pannu HS, Chawla PS, Malhotra S. Neuromuscular transmission failure due to common krait (*Bungarus caeruleus*) envenomation. *Muscle Nerve.* 1999;22:1637-43.
7. Barrington PL, Soons KR, Rosenberg P. Cardiotoxicity of *Naja nigricollis* phospholipase A<sub>2</sub> is not due to alterations in prostaglandin synthesis. *Toxicon.* 1986;24:1107-16.
8. Ariaratnam CA, Sheriff MH, Theakston RD, Warrell DA. Distinctive epidemiologic and clinical features of common krait (*Bungarus caeruleus*) bites in Sri Lanka. *Am J Trop Med Hyg.* 2008;79:458-62.
9. Agarwal R, Aggarwal AN, Gupta D, Behera D, Jindal SK. Low dose of snake antivenom is as effective as high dose in patients with severe neurotoxic snake envenoming. *Emerg Med J.* 2005;22:397-9.
10. Nayak KC, Jain AK, Sharda DP, Mishra SN. Profile of cardiac complications of snake bite. *Indian Heart J.* 1990;42:185-8.
11. Cher CD, Armugam A, Zhu YZ, Jeyaseelan K. Molecular basis of cardiotoxicity upon cobra envenomation. *Cell Mol Life Sci.* 2005;62:105-18.
12. Prasarnpun S, Walsh J, Harris JB. Beta-bungarotoxin induced depletion of synaptic vesicles at the mammalian neuromuscular junction. *Neuropharmacology.* 2004;47:304-14.
13. Prasarnpun S, Walsh J, Awad SS, Harris JB. Envenoming bites by kraits: the biological basis of treatment-resistant neuromuscular paralysis. *Brain.* 2005;128:2987-96.
14. Warrell DA, Looareesuwan S, White NJ, Theakston RDG, Warrell MJ, Kosakarn W, et al. Severe neurotoxic envenoming by the Malayan krait *Bungarus candidus* (Linnaeus): response to antivenom and anticholinesterase. *Br Med J.* 1983;286:678-80.

DOI: 10.5455/2320-6012.ijrms20141190

**Cite this article as:** Verma VK, Maurya V, Verma R. Indian common krait envenomation presenting as fulminant myocarditis and coma: a case report. *Int J Res Med Sci* 2014;2:1713-7.