

Case Report

Spontaneous pneumothorax as a complication in COVID-19 recovered male patient: a case report from a tertiary care centre in Central India

Sheikh Wajid¹, Manoj Kela^{1*}, Abhishek Bawa¹, Rohit Harchandani¹, Ashish Vora¹,
Vinod Bhandari¹, Rajesh Sharma¹, Ravi Dosi²

¹Department of Surgery, SAMC & PGI, SAIMS university, Indore, Madhya Pradesh, India

²Department of Respiratory Medicine, SAMC & PGI, SAIMS university, Indore, Madhya Pradesh, India

Received: 21 February 2021

Revised: 28 March 2021

Accepted: 06 May 2021

*Correspondence:

Dr. Manoj Kela,

E-mail: drmpkela@yahoo.com

Copyright: © the author(s), publisher and licensee Medip Academy. This is an open-access article distributed under the terms of the Creative Commons Attribution Non-Commercial License, which permits unrestricted non-commercial use, distribution, and reproduction in any medium, provided the original work is properly cited.

ABSTRACT

As the number of COVID-19 cases emerge new complications associated with the disease are recognised. This report records a case of pneumothorax in a COVID-19 patient. Our report justifies that pneumothorax can occur during different phases of disease in patients without any history of pulmonary comorbidity and is not necessarily associated to positive pressure ventilation or a severity of COVID-19. However debatable might be the exact mechanism of the process be, this observation might imply that extensive alveolar destruction due to COVID-19 may lead to bulla formation resulting in subsequent pneumothorax.

Keywords: COVID-19, Pneumothorax, Pulmonary comorbidity, Cough, Middle east respiratory syndrome

INTRODUCTION

Cononavirus is a single stranded RNA virus with positive sense. It belongs to the family coronaviridae which derives its name from corona i.e. the latin translation of word crown. This owes to small bulbar projections formed by viral spike S peplomers that appear like a crown on electron microscopy. The same S protiens which generate neutralising antibodies play a pivotal role in protective immunity.

Pneumothorax is defined as the presence of air in pleural space. It can occur either because of air leakage outside in or inside out. In cases of outside in, it can be classified as traumatic pneumothorax that results from penetrating or blunt traumatic chest injuries. Cases that justify inside out, also named as Spontaneous pneumothorax, are pathologies of the lung parenchyma which can be infectious (secondary spontaneous pneumothorax) or non-infectious (primary spontaneous pneumothorax).

Several recent autopsy studies published showed that vascular disease diffuse alveolar damage and lymphocyte infiltration are present in lungs of patient that come to COVID-19 disease. We hypothesize that those pathological findings associated with COVID-19 pneumonitis may lead to bulla formation and thereby predispose to spontaneous pneumothorax. Here, we present one subsequent case of respiratory deterioration caused by primary spontaneous pneumothorax in COVID-19 patients.

CASE REPORT

A 65-year-old male COVID-19 suffered complains of cough and fever on 9 August 2020. The patient took antibiotics tablet azithromycin and other supportive treatment till 12 August 2020. The patient gave his nasopharyngeal sample for COVID-19 on 12 August. The patient came to tertiary medical care centre Indore on 14 August. Meanwhile the patient was reported positive for

COVID-19. Patient received remdesivir for 5 days and managed on NRBM O2 supplementation (Figure 1).

He became COVID-19 negative after 1 week and on 2 September 2020 was discharged. The patient was asymptomatic till 5 September 2020 when he developed severe breathlessness and his SpO₂ was measured to be 74% on room air. The patient was brought to emergency department SAIMS Hospital Indore where appropriate investigations and examinations were done and the patient was found to have left sided pneumothorax and advised ICD insertion (Figure 2). The ICD insertion was done on 5 September 2020 (Figure 3-6).

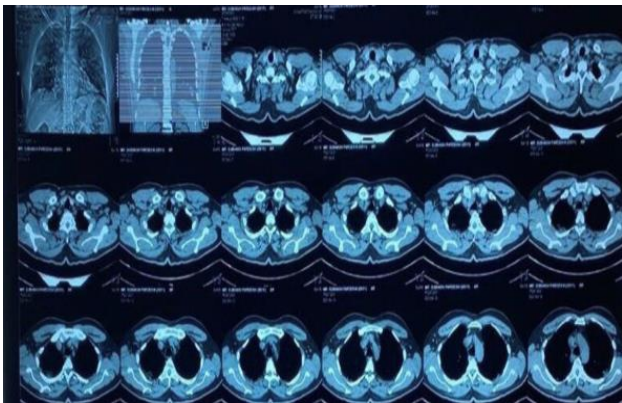


Figure 1: CT scan of chest showing features of active COVID-19 infection.

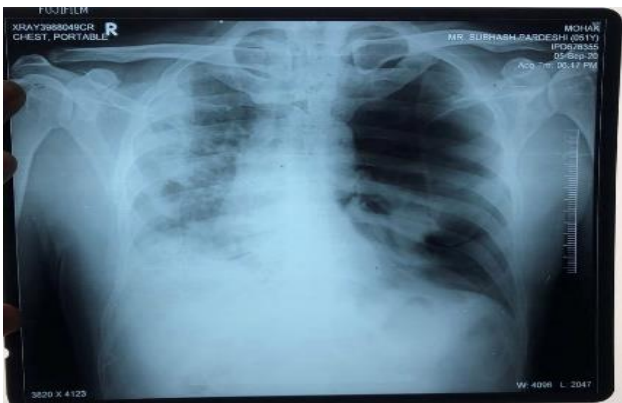


Figure 2: Digital skiagram of chest showing left side pneumothorax in a COVID-19 patient.

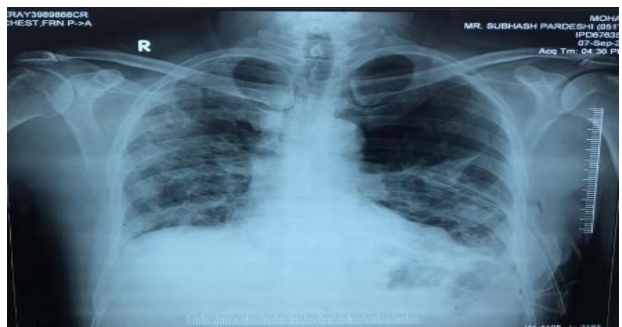

Figure 3: Digital skiagram of chest post left side ICD insertion.

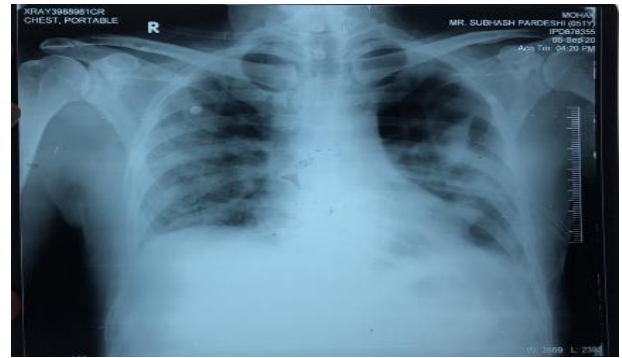


Figure 4: Digital skiagram of chest post left side ICD insertion.

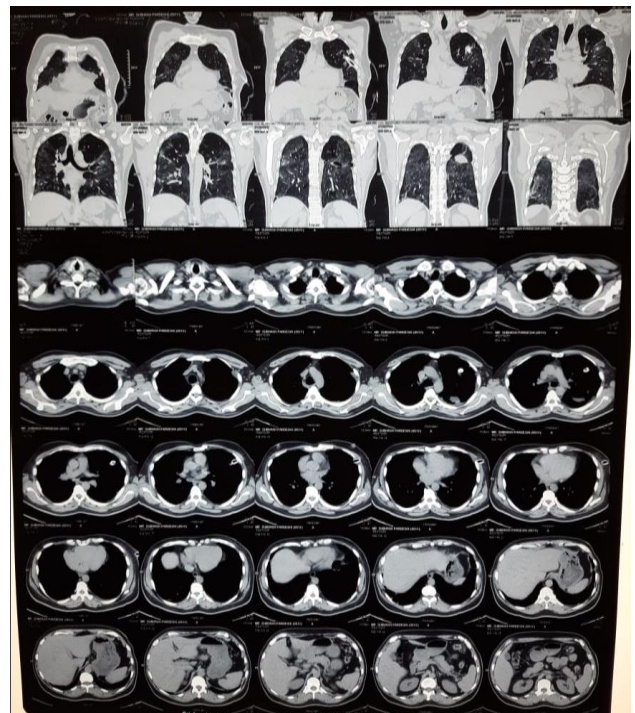


Figure 5: CT scan after left side ICD insertion was done.

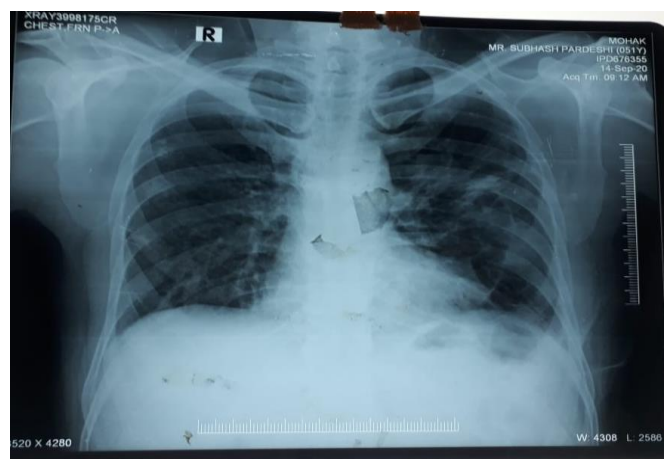


Figure 6: Digital skiagram of chest after left side ICD was removed.

DISCUSSION

As far as we know, there is no known correlation between COVID-19 infection and pneumothorax. few cases of pneumothorax after COVID-19 have been reported, including another case in Netherlands.^{1,2} Our case is about 65-year-old formerly healthy male with COVID-19 infection. This patient was readmitted to hospital for left sided pneumothorax which occurred after admission for COVID-19. A subsequent chest X-ray suggestive of extensive pneumothorax left side. We develop a hypothesis that alveolar damage caused by SARS COV 2 promotes severe destruction of alveolar tissue resulting in bulla formation thereby enhancing the risk of Pneumothorax.

Middle east respiratory syndrome (MERS), severe acute respiratory syndrome (SARS) and COVID-19 are three strains of corona virus. These three strains have ground glass opacity and consolidation as a common finding.³ Long term follows up studies of patients of SARS showed that ground glass opacities persisted for several years and progressed slowly into diffuse fine reticulation, but not bulla formation.⁴ As noticed, in SARS, these findings we were more often unilateral, focal/multifocal.

Whereas in MERS and COVID-19, these findings were bilateral and multifocal. fibrosis and pleural effusion occurred in 1/3rd of the patients with MERS, rarely seen in SARS.⁵ While pneumothorax is rare in both SARS and MERS it has been associated in MERS with poor prognosis. Viral pneumonitis such as influenza, measles, hantavirus and cytomegalovirus are also associated with bilateral ground glass opacity and consolidation, but bulla formation not reported.⁶ Pneumonitis caused by influenza virus caused is mostly ground glass attenuation with lobar distribution and formation and subsequent pneumothorax has been seen.^{7,8}

In a recent autopsy study, a comparison was done between pathological finding in lung tissue of COVID-19 positive patients, patients of H1N1 pneumonia, and patients without pneumonia. Diffuse alveolar damage (DAD) was found in both diseases. Extensive endothelial and vascular damage with microthrombi were evident in COVID-19 Infection which is not seen in uninfected lung. Pneumothorax can be a complication of positive airway pressure in patients with ARDS receiving mechanical ventilation. DAD seen in both ventilated and unventilated COVID-19 patients that can lead to bullae formation and subsequent pneumothorax.^{9,10}

Histopathology from autopsy studies in deceased COVID-19 patients report bilateral diffuse alveolar damage, evident desquamation of pneumocytes and high line membrane formation. Thrombosis microangiopathy and leukocyte infiltration, mostly consisting of lymphocytes, are also frequently reported.

CONCLUSION

The presented case suggests that COVID-19 pneumonia may lead to bullae formation and subsequent pneumothorax can occur and formally healthy lungs, which may not be related to initial severity of COVID-19, and received treatment and can occur during any stage of disease. This demonstrate that the possibility of pneumothorax should be kept in mind in patients with, or recovering from, COVID-19 disease with progressive dyspnea. We suggest that extensive alveolar destruction may lead to bullae formation resulting in subsequent pneumothorax. Long-term follow-up of COVID-19 patients is necessary to provide the knowledge about the course of pulmonary sequel and risk of pneumothorax.

Funding: No funding sources

Conflict of interest: None declared

Ethical approval: Not required

REFERENCES

1. Bloemen H, Hagmolen W, Clappers GGAL. COVID-19-pneumonie Chest pain and dyspnea during the recovery period of COVID-19 pneumonia. *Ned Tijdschr Geneeskd.* 2020;164:5095.
2. Sun R, Liu H, Wang X. Mediastinal Emphysema, Giant Bulla, and Pneumothorax Developed during the Course of COVID-19 Pneumonia. *Korean J Radiol.* 2020;21(5):541-4.
3. Hosseiny M, Kooraki S, Gholamrezanezhad A, Reddy S, Myers L. Radiology Perspective of Coronavirus Disease 2019 (COVID-19): Lessons From Severe Acute Respiratory Syndrome and Middle East Respiratory Syndrome. *AJR Am J Roentgenol.* 2020;214(5):1078-82.
4. Wu X, Dong D, Ma D. Thin-Section Computed Tomography Manifestations During Convalescence and Long-Term Follow-Up of Patients with Severe Acute Respiratory Syndrome (SARS). *Med Sci Monit.* 2016;22:2793-9.
5. Ketai L, Paul NS, Wong KT. Radiology of severe acute respiratory syndrome (SARS): the emerging pathologic-radiologic correlates of an emerging disease. *J Thorac Imaging.* 2006;21(4):276-83.
6. Kim EA, Lee KS, Primack SL, Yoon HK, Byun HS, Kim TS, et al. Viral pneumonias in adults: radiologic and pathologic findings. *Radiographics.* 2002;22:137-49.
7. Franquet T, Lee KS, Muller NL. Thin-section CT findings in 32 immunocompromised patients with cytomegalovirus pneumonia who do not have AIDS. *AJR Am J Roentgenol.* 2003;181(4):1059-63.
8. Koo HJ, Lim S, Choe J, Choi SH, Sung H, Do KH. Radiographic and CT Features of Viral Pneumonia. *Radiographics.* 2018;38(3):719-39.
9. Wichmann D, Sperhake JP, Lutgehetmann M, Steurer S, Edler C, Heinemann A, et al. Autopsy Findings and Venous Thromboembolism in Patients With COVID-19: A Prospective Cohort Study. *Ann Intern Med.* 2020;173(4):268-77.

10. Ackermann M, Verleden SE, Kuehnel M, Haverich A, Welte T, Laenger F, Vanstapel A, et al. Pulmonary Vascular Endothelialitis, Thrombosis, and Angiogenesis in Covid-19. *N Engl J Med.* 2020;383(2):120-8.

Cite this article as: Wajid S, Kela M, Bawal A, Harchandani R, Vora A, Bhandari V, et al. Spontaneous pneumothorax as a complication in COVID-19 recovered male patient: a case report from a tertiary care centre in Central India. *Int J Res Med Sci* 2021;9:1774-7.