

Implementation of Pre-processing and Efficient Blood Vessel Segmentation in Retinopathy Fundus Image

Keerti V

M.Tech Student, Dept. of DECS

VTU-CPGS Bangalore Region

VIAT Muddenahalli, Chickaballapura, Karnataka, India

avc.1509@gmail.com

Dr. Sarika Tale

Associate Professor, Dept. of DECS

VTU-CPGS Bangalore Region

VIAT Muddenahalli, Chickaballapura, Karnataka, India

raga.sarika@gmail.com

Abstract- The human retina is a light receptive tissue and its enormously rich in blood vessels for its high physiological stress and dysfunction of the retinal vasculature can effect from several diseases. Diabetic retinopathy is caused due to complications of diabetes, which can eventually develop new blood vessels at the back of the retina and it can lead to blur vision or loss of vision. This work describes the problems of retinopathy associated with diabetic patients and premature babies. We propose methods for the preprocessing and efficient segmentation method to support measurement of the openness of the MTA, including image enhancement techniques like morphological operations, efficient luminance component construction and bank of Gabor filters to segment retinal blood vessels. Finally an image cropping is used to separate inferior and superior part of this segmented image for the effective and detailed analysis of the vascular structure in the fundus eye images. Certain retinal disorders, if not detected in time, can cause serious problems like blur vision and blindness in patients. The implementation and the performance of the various edge detection methods like Canny, Sobel and Gabor filters are based on visual perception. It has been concluded that in case of natural images such as retinal fundus image a Gabor filter yielded better results in segmentation of blood vessels as compared to edge detection methods of Canny and Sobel.

Keywords- Diabetic retinopathy, image preprocessing, Blood vessels, Gabor filter, Segmentation

I. INTRODUCTION

The transparency of the retina makes it in a direct window for the human vasculature through an eye fundus examination. Thus, some systemic diseases cause changes in the retinal vessels which can be observed in retinal images. Diabetic retinopathy (DR) is one of the most significant complications of diabetes mellitus, which causes severe damages in the retina, subsequently visual loss and sometimes blindness if required medical treatment is not taken on time. One of the difficulties in this illness is that the patient with diabetes mellitus requires a continuous screening for early detection. So far, various methods have been planned by researchers to automate the recognition process of retinal blood vessels in analyzing retinal images such as color fundus images and fluorescein angiography images of retinal fundus images. In this way, with the increasing development of image processing techniques, retina imaging constitutes a key for diagnosis support. The problem of retinopathy is associated with diabetic patients and premature babies. A signal processing and image processing framework provides better diagnosis to the Ophthalmologists for the analysis of the blood vessel structure as accurately as possible. The vasculature of retinal fundus is the only region of human body that can be analyzed by using relatively simple and non-invasive instrumentation. At the thresholding stage the accuracy of the segmentation is dependent on the parameters used.

Alterations in the vascular structure of the retina can indicate the presence of several types of pathology, such as hypertension, arteriosclerosis, diabetes, myopia, and retinopathy of prematurity (ROP). The vessels in the retina are modified in terms of their width, shape, and tortuosity of the retinal diseases. Variations in the architecture of the major temporal arcade (MTA), in the form of a decrease in the angle of insertion of the MTA as well as straightening of the MTA, have been noted as manifestations of at least two types of pathology: as a sequela of ROP and as an indicator of the severity of myopia. In case of natural images such as retinal fundus image a Gabor filter gives better results compared to edge detection operators such as canny and sobel but in case of medical images like CT scan, X-ray and MRI, etc the Canny operator shows better results as it provides fine details of an image. Canny edge detector produces higher accuracy in detection of objects as compared to Sobel [1,21].

II. METHODOLOGY

Below are the main steps involved in the implementation and segmentation of the fundus image[21]

1) Preprocessing of images.

- Normalizing each color component in the original image.
- Computing the luminance component.

- Thresholding the luminance component to obtain the effective area.
- Expanding the luminance component beyond the effective area to avoid the detection of its edges.

2) Obtaining the segmentation of the fundus image

- Using 180 bank of Gabor filters over the range of $[-90^\circ, 90^\circ]$ to represent the MTA.
- Segmentation of the binary images.
- Applying the morphological process to filter its background.
- Rotating each segmented image by 180° , if the MTA opens to the left (i.e., the image is of the right eye).
- Obtaining the Gabor magnitude response image to represent the STA and the ITA, respectively.
- Cropping each segmented image horizontally.
- Applying Canny, Sobel edge detectors to the segmented image for comparative analysis.

Since the MATLAB is widely used interactive program developed to perform numerical computation and data visualization, our entire simulation program are written using the programming language MATLAB.

A. Image preprocessing

In this method, the color scale RGB images are first converted into grayscale for efficient computation. Since the exudates are visible with more contrast in grayscale an equalization procedure was performed on the images to obtain a local contrast i.e approximately, equal at all image intensities.

$$C(x, y) = f(x, y) - \text{median } \phi(x, y) \tag{2.1}$$

Where $C(x, y)$ is the estimated local contrast, $f(x, y)$ is the image gray level at (x, y) , $\text{median } \phi(x, y)$ is the median gray level within the neighborhood ϕ of (x, y) . This can be equated to a high pass spatial filter. The local contrast provides a measure of the high-frequency image noise[6].

B. Gabor filter

It acts as an excellent band pass filter. A complex Gabor filter is defined as the product of Gaussian kernels times a complex sinusoid.

$$\begin{aligned} g(t) &= ke^{j\theta} w(at)S(t) \\ w(t) &= e^{-\pi t^2 t i \theta} \\ s(t) &= e^{-j(2\pi f_0 t)} \end{aligned} \tag{2.2}$$

k, θ, f_0 are filter parameters. The real and imaginary components of Gabor filter are phase sensitive and allow frequency tuning. This enables noise filtering and vessel

enhancement in single step. θ is spanned from 0° to 360° over all four angles taken as pixel features. In [13], scale and orientation of selective Gabor filter are used to detect and classify the retina images into mild or severe case. The input image is first filtered through Gabor filter banks, the banks consist of several filters tuned to specific scales and orientation and the operation is performed in frequency domain, the output of which is the analyzed. Gabor filter response is the convolution of the FT of the Gaussian function and the Fourier transform of the harmonic function. Gabor filter has a real and imaginary components representing orthogonal directions. Thus image analysis with Gabor filters is analogous to the human visual perception system. Gabor filters are sinusoidally modulated Gaussian functions. A Gabor filter is defined by the STD valued of the Gaussian function in the X & Y directions (σ_x & σ_y) and the frequency f_0 of the modulating sinusoid as [8].

$$g(x, y) = \frac{1}{2\pi \sigma_x \sigma_y} \exp\left\{-\frac{1}{2}\left[\frac{x^2}{\sigma_x^2} + \frac{y^2}{\sigma_y^2}\right]\right\} \cos 2\pi f_0 X \tag{2.3}$$

As per design procedure, a variable named τ , representing the average thickness of the vessels to be detected by Gabor filters. We use $\tau = 16$ pixels (0.32mm) $f_0 = 1/\tau$ & σ_x is in relation to τ . A set of 180 Gabor filters spanning the range $[-90^\circ, 90^\circ]$ is prepared by rotating the basic Gabor function in equation . A magnitude response image is created by using the maximum value of the response of 180gabor filters for each pixel. The morphological operation of area open procedure also uses the concept of pixel connectedness to detect segments of connected pixels having less than 70 pixels and removes them. The main principle of this stage is to eliminate background variations in illumination from an image such that the forefront objects are more easily analyzed. Therefore the binary image is produced in which each pixel value is either 1 (blood vessel) or 0 (background)[7].

III. RESULTS AND DISCUSSION

The proposed blood vessel detection and segmentation methodology is applied on images available in DRIVE database and image collected from eye hospital. Hence, eye care specialists can analyze retinopathy in larger populations using this method. The results depicted in the below figures are experimented with the images collected from the standard Drive data base as well as the image collected from the eye hospital.

A. Normal eye results

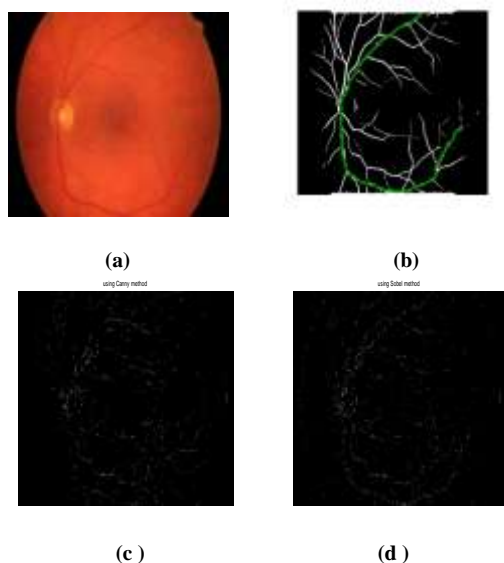


Fig: 1 Results of normal eye

In above Fig 1: (a) indicates Gabor filter response of normal eye (b) indicates the segmented image of Major Temporal Arcade(MTA) Fig (c) depicts the segmented result using Canny method and fig (d) shows the segmented result using Sobel method .

From the above results, in normal eye fundus image the blood vessel growth and MTA are normal.

B. Diabetic Retinopathy Results

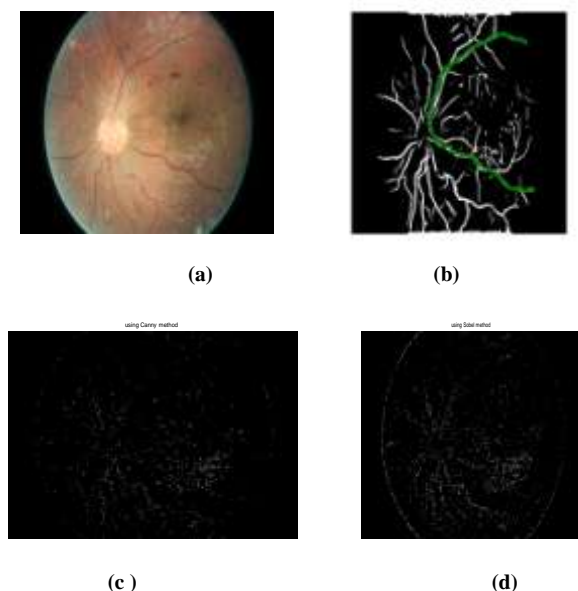


Fig 2: Diabetic Retinopathy results

In above Fig 2: (a) indicates Gabor filter response of severe diabetic retinopathy(DR) and (b) indicates the segmented image of Major Temporal Arcade(MTA), Fig (c) depicts the segmented result using Canny method and fig (d) shows

the segmented result using Sobel method . From the above result we observe that in DR eye fundus image, the blood vessel structure has overgrowth and MTA has decreased.

C. Severe Diabetic Retinopathy Results




Fig 3: Severe Diabetic Retinopathy results

In above Fig 3: (a) indicates Gabor filter response of severe diabetic retinopathy(DR) (b) indicates the segmented image of Major Temporal Arcade(MTA) Fig (c) depicts the segmented result using Canny method and Fig (d) shows the segmented result using Sobel method. In severe DR eye fundus image, the blood vessel structure has severe overgrowth and MTA has straightened.

The MTA diverges away from the Optic Nerve Head towards the macula and then converges down into the macular region. Furthermore, after the second or third branching point, it becomes difficult to distinguish between the original arcade and the new branch as they could be similar in diameter and branch erratically. The second and third branching points occur approximately over the macula[22].

A. Comparative analysis:

From the above results, we observe that Sobel operator has poor edge localization in segmented image. It is sensitive to noise and gives inaccurate results. Hence it is not an efficient method in analysis of the segmented blood vessels. Canny edge detector has adaptive thresholding and produces higher accuracy in detection of objects as compared to Sobel but Canny operator is time consuming and has complex computation. To overcome the above problem a filter bank consisting of 180 Gabor filters with cosine term having various scales and rotations of kernel functions are used. The Gabor Filter is very useful in image processing applications using edge detection and provides optimal localization in both the frequency and space domains. Gabor filter has better feature detection and produces thick edges.

Therefore Gabor filter gives better results as compared to Canny and Sobel in analyzing the segmented blood vessels of retinopathy with improved signal to noise ratio.

IV. CONCLUSION

Diabetic retinopathy is the leading cause of the blindness in diabetic populations. The effective segmentation of the eye funds image helps to detect and diagnose to help prognosis's treatment procedural plans if required for the ophthalmologists. In this work we have presented diabetic image segmentation technique using bank of Gabor filters with effective image enhancement technique like normalized gray scale conversion, masking and optic nerve head elimination. This framework also provides closer analysis of the superior and inferior arcade portions by cropping superior and inferior portions from the segmented image. The experimented results shows that the effectiveness of the image segmentation algorithm using bank of Gabor filters to keep only the blood vessels structures and avoids other artifacts. Generally Gabor filter gives better results than Canny and Sobel especially for natural images, where the objects are considered to be a big challenge to segment. Thus Gabor filter provides better result as the selected parameters produce the large magnitude and brighter intensity of the edges.

V. FUTURE SCOPE

Automatic retinopathy detection is a primary challenge in the today's world because of the feature extraction of the retinopathy images with and without diabetic retinopathy is very complicated using image processing techniques. Temporal screening of the fundus image is not more often recommended by the physicians. Therefore temporal feature extraction, regular temporal screening of fundus image and machine learning based automatic retinopathy detection is recommended as the future scope from this work.

ACKNOWLEDGMENT

Thanks to my Guide, family member and my friend Satyanarayana V who always support, help and guide during my dissertation work. Finally thanks to Dr. Bhargavi, consulting physician, Minto Eye Hospital Bangalore for providing necessary information about retinopathy.

REFERENCES

- [1] International Committee for the Classification of Retinopathy of Pre-maturity. The international classification of retinopathy of prematurity revisited. Archives of ophthalmology, 123:991-999, 2005.
- [2] Wilson CM, Cocker KD, Moseley MJ, Paterson C, Clay ST, Schulenburg WE, Mills MD, Ells AL, Parker KH,

- Quinn GE, Fielder AR, and Ng J. Computerized analysis of retinal vessel width and tortuosity in premature infants. Investigative Ophthalmology and Visual Science, 49(1):3577- 3585, 2008.
- [3] Jelinek HF and Cree MJ. Automated Image Detection of Retinal Pathology. CRC Press, Boca Raton, FL, 2010.
- [4] Patton N, Aslam TM, MacGillivray T, Deary IJ, Dhillon B, Eikelboom RH, Yogesan K, and Constable IJ. Retinal image analysis: Concepts, applications and potential. Progress in Retinal and Eye Research, 25(1):99-127, 2006.
- [5] Fledelius HC and Goldschmidt E. Optic disc appearance and retinal temporal vessel arcade geometry in high myopia, as based on follow-up data over 38 years. Acta Ophthalmologica, 88(5):514-520, March 2010.
- [6] Wilson C, Theodorou M, Cocker KD, and Fielder AR. The temporal retinal vessel angle and infants born preterm. British Journal of Ophthalmology, 90:702-704, 2006.
- [7] Reese AB, King MJ, and Owens WC. A classification of retrolental fibroplasia. American Journal of Ophthalmology, 36:1333-1335, 1953.
- [8] Cryotherapy for Retinopathy of Prematurity Cooperative Group. Multi-center trial of cryotherapy for retinopathy of prematurity: Ophthalmological outcomes at 10 years. Archives of Ophthalmology, 119:1110-1118, 2001.
- [9] Foracchia M, Grisan E, and Ruggeri A. Detection of optic disc in retinal images by means of a geometrical model of vessel structure. IEEE Transactions on Medical Imaging, 23(10):1189-1195, 2004.
- [10] Tobin KW, Chaum E, Govindasamy VP, and Karnowski TP. Detection of anatomic structures in human retinal imagery. IEEE Transactions on Medical Imaging, 26(12):1729-1739, December 2007.
- [11] Li H and Chutatape O. Automated feature extraction in color retinal images by a model based approach. IEEE Transactions on Biomedical Engineering, 51(2):246-254, 2004.
- [12] Fleming AD, Goatman KA, Philip S, Olson JA, and Sharp PF. Automatic detection of retinal anatomy to assist diabetic retinopathy screening. Physics in Medicine and Biology, 52:331-345, 2007.
- [13] D. Vallabha, R. Dorairaj, K.R. Namuduri and H. Thompson, "Automated Detection and Classification of Vascular Abnormalities in Diabetic Retinopathy", Conference Record of the 38th Asilomar Conference on Signals, Systems and Computers, Pacific Grove, CA, USA, vol.2, pp.1625-1629, Nov.2004.
- [14] R. O. Duda, P. E. Hart, and D. G. Stork, Pattern Classification, 2nd ed. New York: Wiley, 2001
- [15] J. Hayashi, T. Kunieda, J. Cole, R. Soga, Y. Hatanaka, M. Lu, T. Hara and H. Fujita, "A Development of Computer Aided Diagnosis System Using Fundus Images", Proceeding of the 7th International Conference on Virtual Systems and Multi Media, Berkeley, California, USA, pp.429-438, Oct.2001.
- [16] Ying H and Liu JC. Automated localization of macula-fovea area on retina images using blood vessel network topology. In Acoustics Speech and Signal Processing

- (ICASSP), 2010 IEEE International Conference on, pages 650–653, March 2010 .
- [17] Balmer A, Zografos L, Munier F; Diagnosis and current management of retinoblastoma. *Oncogene*. 2006 Aug 28;25(38):5341-9.
- [18] Oloumi F, Rangayyan RM, and Ells AL. Parametric representation of the retinal temporal arcade. In *The 10th IEEE International Conference on Information Technology and Applications in Biomedicine*, Corfu, Greece, November 2010.
- [19] DRIVE: Digital Retinal Images for Vessel Extraction. [http:// www. isi.uu.nl/ Research/ Databases/ DRIVE/](http://www.isi.uu.nl/Research/Databases/DRIVE/), accessed on March 24, 2008.
- [20] Image Processing and Analysis in Java, [http:// rsbweb. nih.gov/ ij/](http://rsbweb.nih.gov/ij/), accessed on September 3, 2008.
- [21] Rangayyan RM, Ayres FJ, Oloumi F, Oloumi F, and Eshghzadeh-Zanjani P. Detection of blood vessels in the retina with multiscale Gabor filters. *Journal of Electronic Imaging*, 17:023018:1–7, April-June 2008.
- [22] Rangayyan RM, Zhu X, Ayres FJ, and Ells AL. Detection of the optic nerve head in fundus images of the retina with Gabor filters and phase portrait analysis. *Journal of Digital Imaging*, 23(4):438–453, August 2010. Sample Image,[Online],Avaliable, <http://www.dambrosio-eye-care-boston.com/diabetic-retinopathy.html>, Aug. 2007.
- [23] M. Niemeijer, M. D. Abramoff, and B. v. Ginneken, “Segmentation of the optic disc, macula and vascular arch in fundus photographs,” *IEEE Trans. Med. Imag.*, vol. 26, no. 1, pp. 116–127, Jan. 2007.
- [24] F. Zana and J. Klein, “Segmentation of vessel-like patterns using mathematical morphology and curvature evaluation,” *IEEE Trans. Image Process.*, vol. 10, no. 7, pp. 1010–1019, Jul. 2001.
- [25] L. Gagnon, M. Lalonde, M. Beaulieu, and M.-C. Boucher, —Procedure to detect anatomical structures in optical fundus images in *Proc. SPIE Med. Imaging: Image Processing*, vol. 4322, 2001,pp. 1218–1225.