

A Review of Thyroid Disorder Detection Using Medical Images

Ms. Priti Dhaygude
Department Of E&TC
K.J.'s Educational Institute's TCOER, Pune
Maharashtra, India.

Mrs. S. M. Handore
Department Of E&TC
K.J.'s Educational Institute's TCOER, Pune
Maharashtra, India

Abstract: Thyroid is one of the largest endocrine gland. It is a small butterfly shaped gland which is located in the front portion of the neck. It is located just below the Adams apple. Thyroid gland produces hormones that help the body to control metabolism. There are various thyroid disorders. It includes Hyperthyroidism, Hypothyroidism, goiter and thyroid nodules (benign/malignant). Various modalities that are used to detect and classify abnormalities of the thyroid gland are Ultrasound imaging, Computer Tomography(CT),Magnetic Resonance Imaging(MRI) and Computer Aided Diagnosis (CAD).CAD help radiologists and doctors to increase the diagnosis accuracy, reduce biopsy ratio and save their time and effort. Medical image analysis has played an important role in many clinical procedures for detecting different types of human diseases. Thyroid medical images are utilized for the diagnosis process.

Keywords- *Thyroid, Thyroid disorders, Medical imaging, Segmentation, Classification, SVM, KNN.*

I. Introduction

Image processing is one of the form of signal processing in which the input is an image such as photograph or video frame. The output of image processing may be either an image or parameters related to the image. The input may be a photograph or video frame. In digital image processing the use of computer algorithms to perform image processing on digital images is done. Medical imaging is the technique which is used to create images of the human body for clinical purpose. It also contains medical science which includes the study of normal anatomy and physiology[3]. For diagnosing thyroid diseases, different Imaging technologies are:- Radiology, Magnetic resonance imaging (MRI), Nuclear medicine, Photo acoustic imaging, Tomography and Ultrasound imaging(US).The most commonly used method is ultrasound imaging because US imaging is less expensive, non-invasive and very easy to use. Image processing algorithms consists of different steps such as image preprocessing, segmentation, feature extraction, feature selection and classification.

The remaining paper is organized as:Section II covers the methodology used for disease diagnosis, Section III includes discussion of different thyroid disorders and their symptoms, Section IV presents the review of thyroid diseases. In Section IV the conclusion is given.

II. METHODOLOGY USED

Image Processing is an area that uses several techniques and algorithms in order to interpret and understand the information contained in a digital image. Most image processing algorithms consist of a few typical steps viz. image preprocessing, segmentation, feature extraction, feature selection and

classification. The methodology used for the thyroid disorder detection is as shown in the following flowchart.

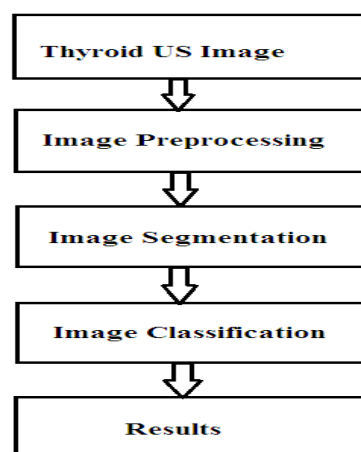


Fig.1 Flowchart for the methodology

First, thyroid US image is taken. Image processing step includes removal of noise using filters and to enhance the image. Image segmentation is the process of partitioning an image into multiple segment or set of pixels used to locate object and boundaries. Each of the pixels in a region is similar with respect to some characteristics such as color, intensity or texture. Image classification of thyroid nodule is done in order to eliminate operator dependency and to improve the diagnostic accuracy[1]. In digital image classification the conventional statistical approaches for image classification use only the gray values. Different advanced techniques in image classification are Artificial Neural Networks (ANN), Support Vector Machines (SVM), Fuzzy measures, Genetic Algorithms (GA), Fuzzy support Vector Machines (FSVM). SVM was found to be the best in the available machine learning algorithms in classifying high-dimensional data sets.

Image classification using neural networks is done by texture feature extraction and then applying the back propagation algorithm [19].

III. DIFFERENT THYROID DISORDERS AND THEIR SYMPTOMS

Thyroid gland produces hormones that are helpful for the body to control metabolism. In general, thyroid disease can be divided into two broad groups of disorders: First group is the one which primarily affect the function of the thyroid and the second one is the one which involve neoplasms, or tumors of the thyroid. Both types of disorders are common in the general population. Abnormalities of thyroid function are usually related to production of thyroid hormone.

There are four main types of thyroid diseases[2]-hyperthyroidism (too much thyroid hormone), hypothyroidism (too little thyroid hormone), benign (noncancerous) thyroid disease and thyroid cancer(malignant).

The symptoms of hypothyroidism includes fatigue, mental foginess and forgetfulness, feeling excessively cold, constipation, dry skin, fluid retention, non specific aches and stiffness in muscles and joints, excessive or prolonged menstrual bleeding (menorrhagia), and depression. Hyperthyroidism can be observed with different signs and symptoms. Common symptoms of hyperthyroidism includes excessive sweating, heat intolerance, increased bowel movements, tremor (usually a fine shake), nervousness, agitation, rapid heart rate, weight loss, fatigue, decreased concentration and irregular and scant menstrual flow.

IV. REVIEW ON THYROID DISORDERS

Deepika Koundal et al. [1] have provided the information about the existing automatic tools which are available to formulate the disease diagnosis part easier with efficient way. Also different performance evaluation metrics are studied. The future developments and trends are also investigated.

Nikita Singh and Alka Jindal [7] have concluded that SVM is better classifier as compared to KNN and Bayesian. Accuracy of SVM is about 84.62%.

Nasrul Humaimi Mahmood and Akmal [8] have provided a simple way to determine the thyroid lobes in the thyroid ultrasound image using a MATLAB. The thyroid have two lobes: right and left lobe. The image undergoes the contrast enhancement to suppress speckle that are present in US image. The enhanced image is used for segmentation of

the thyroid region by local region-based active contour. The thyroid region is segmented into two parts, which are right and left with the active contour method separately. Transverse view of thyroid ultrasound image is used therefore the measurements only involve the width, depth and area of the thyroid region. The result of thyroid measurement is calculated in pixel unit and then it is converted in centimetre (cm) unit. It shows that from five samples, different people have different size of thyroid.

Edgar Gabriel et al. [9] have proposed two parallel versions of a code that are used for texture-based segmentation of thyroid FNAC images which is a critical first step in realizing a fully automated CAD solution. An MPI version of the code is Developed to exploit distributed memory compute resources such as PC clusters M.

Savelonas et al. [10] have proposed active contour model named Variable Background Active Contour model. It is used for the detection of thyroid nodules in ultrasound images. The new model offers edge independency, smoothingless operation, ability for topological changes. It gives more accuracy when compared to the Active Contour Without Edges model. Accuracy can be improved by introducing as background a limited image subset which appropriately changes shape to reduce the effects of background inhomogeneity.

Preeti Aggarwal et al [12] suggested an automatic segmentation method. They have provided a summary of all the results obtained either by automatic tools as well as by applying specific algorithm (automatic) segmentation on both lung CT as well as on thyroid US .There are two tools: Analyze 10.0 and Mazda for segmentation of thyroid US images.

Nikita Singh et al. [13] have proposed classification using SVM, KNN and Bayesian. Also the information about segmentation and classification methods which are very important for medical image processing is also provided efficiently. The results shows that SVM gives better accuracy as compared to KNN and Bayesian

Eystratios G. et al.[14] have suggested a computer-aided diagnosis (CAD) system prototype named as TND (Thyroid Nodule Detector).It is used for the detection of nodular tissue in ultrasound (US) thyroid images and videos acquired during thyroid US examinations.

Eleonora Horvath et al. [15] have proposed a study using the TIRADS (Thyroid Imaging Reporting and Data System) and have established following categories :

- TIRADS 1: normal thyroid gland.
- TIRADS 2: benign conditions (0% malignancy).
- TIRADS 3: probably benign nodules (5% malignancy).
- TIRADS 4: Suspicious nodules (5–80% malignancy rate). A subdivision into 4a (malignancy between 5 and 10%) and 4b (malignancy between 10 and 80%) was optional.
- TIRADS 5: Probably malignant nodules (malignancy 80%).
- TIRADS 6: Category included biopsy proven malignant nodules.

Mary C. Frates et al. [16] have provided US features associated with thyroid cancer. They have also suggested that which nodules should be subjected to US-guided fine needle aspiration and which thyroid nodules need not be subjected to fine-needle aspiration. Different image classifiers are Artificial Neural Networks (ANN), Support Vector Machines (SVM), Fuzzy measures, Genetic Algorithms (GA), Fuzzy support Vector Machines (FSVM). The textural features in ANN helps to resolve misclassification. SVM is the best available machine learning algorithms in classifying high-dimensional data sets.

Won-Jin Moon et al. [17] have done the evaluation on the diagnostic accuracy of ultrasonographic (US) criteria for the depiction of benign and malignant thyroid nodules. It is done by using tissue diagnosis as the reference standard. They concluded that shape, margin, echogenicity and presence of calcification are important criteria for the discrimination of malignant from benign nodules.

Singh1 and Mrs Alka Jindal [18] have used the groups Benign (non-cancerous) and Malignant (cancerous) Thyroid Nodules images. The texture feature method like GLCM are very useful for classifying texture of images. These texture features are used to train the classifiers such as SVM, KNN and Bayesian. The experimental result shows the performance of the various classifiers and shows the best predictive value and efficiently identify the percentage of the non-cancerous or cancerous people. It also shows the best performance accuracy using the SVM classifier as compare to the KNN and Bayesian classifier. It uses the segmentation based algorithm localized based active contour (region based) method. It is basically to segment the local area of the images and to segment the nodule which gives the information about the type of nodule exist that is either benign or malignant. The classification accuracy is calculated in term of true positive (TP), true negative (TN), false positive (FP), false negative (FN) with respect to the ground truth.

V. CONCLUSION

The performance of our different body parts is greatly influenced by Thyroid hormones because these hormones are responsible to control the body metabolism. This review work provides knowledge about thyroid, thyroid diseases, thyroid diagnosis, different classifiers for better detection of thyroid disease diagnosis in medical images. Different researchers have developed various techniques to process thyroid medical images and to detect the disorder present in the thyroid. These techniques are helpful to the radiologists and doctors for efficiently diagnosing the nodules in thyroid images. It will reduce the false diagnosis of thyroid diseases. Different classifiers improve the performance of classifying thyroid nodules as cancer/non- cancerous. It will help to develop the better methods for the diagnosis of thyroid diseases.

REFERENCES

- [1] Deepika Koundal1 et al., Computer-Aided Diagnosis of Thyroid Nodule:A Review, International Journal of Computer Science & Engineering Survey (IJCSSES) Vol.3, No.4, August 2012
- [2] <http://www.nlm.nih.gov/medline/us/ency/article/000371.htm>
- [3] <http://www.wikipedia.com>
- [4] <http://thyroid.about.com/library/weekly/qathyroid101-e.htm>
- [5] <http://ww.medicinenet.com/script/main/at.asp>
- [6] Young Hun Lee, Dong Wook Kim, Hyun Sin In, Ji Sung Park, Sang Hyo Kim, Jae Wook Eom, Bomi Kim, EunJoo Lee, Myung Ho Rho, "Differentiation between Benign and Malignant Solid Thyroid Nodules Using an US Classification System" ISSN 1229-6929. ISSN 2005-8330 Korean J Radiol 2011;12(5):559-567.
- [7] Nikita Singh, Alka Jindal "A Segmentation Method and Comparison of Classification Methods for Thyroid Ultrasound Images " in International Journal of Computer Applications (0975 – 8887) Volume 50 – No.11, July 2012
- [8] Nasrul Humaimi Mahmood and Akmal, Segmentation and Area Measurement for Thyroid Ultrasound Image, International Journal of Scientific & Engineering Research Volume 2, Issue 12, December 2011
- [9] Edgar Gabriel et al. —Towards high performance cell segmentation in multispectral fine needle aspiration cytology of thyroid lesions, computer methods and programs in biomedicine, pp 1-10
- [10] M. Savelonas et al. —Variable Background Active Contour Model for Automatic Detection of Thyroid Nodules in Ultrasound Images, Dept. of Informatics and Telecommunication
- [11] Nasrul Humaimi Mahmood and Akmal, Segmentation and Area Measurement for Thyroid Ultrasound Image, International Journal of Scientific & Engineering Research Volume 2, Issue 12, December 2011
- [12] Preeti Aggarwal et al. —Role of Segmentation in Medical Imaging: A Comparative Study International Journal of Computer Applications (0975 – 8887) Volume 29– No.1, September 2011

-
- [13] Nikita Singh et al. — A Segmentation Method and Comparison of Classification Methods for Thyroid Ultrasound Images International Journal of Computer Applications (0975 – 8887) Volume 50 – No.11, July 2012
 - [14] Eystratios G.et al. TND: A Thyroid Nodule Detection System for Analysis of Ultrasound Images and Videos Springer Science+Business Media, LLC 2010
 - [15] Eleonora Horvath et al. An Ultrasonogram Reporting System for Thyroid Nodules Stratifying Cancer Risk for Clinical Management, J Clin Endocrinol Metab 90: 1748–1751, 2009
 - [16] Mary C. Frates et al. —Management of Thyroid Nodules Detected at US: Society of Radiologists in Ultrasound Consensus Conference Statement Management of Thyroid Nodules Detected at US Volume 237 , Number 3
 - [17] Won-Jin Moon et al. Benign and Malignant Thyroid Nodules: US Differentiation—Multicenter Retrospective Study Radiology: Volume 247: Number 3—June 2008.
 - [18] Singh1 and Mrs. Alka Jindal, A segmentation method and classification of diagnosis for thyroid nodules, . IOSR Journal of Computer Engineering (IOSRJCE) ISSN : 2278-0661 Volume 1, Issue 6 , PP 22-27,2012 .
 - [19] Sheeja Agustin A, S. Suresh Babu, A Review of Thyroid Disorder Detection, Segmentation and Classification on Medical Images . International Journal of Engineering and Advanced Technology (IJEAT) ISSN: 2249 – 8958, Volume-2, Issue-3, February 2013.