

Case Report

An unusual presentation of low ulnar nerve palsy: a case report

Eknoor Kaur*, Narender Saini

Department of Orthopedics, SMS Medical College, Jaipur, Rajasthan, India

Received: 14 December 2020

Revised: 21 January 2021

Accepted: 29 January 2021

*Correspondence:

Dr. Eknoor Kaur,

E-mail: dr.eknoor@gmail.com

Copyright: © the author(s), publisher and licensee Medip Academy. This is an open-access article distributed under the terms of the Creative Commons Attribution Non-Commercial License, which permits unrestricted non-commercial use, distribution, and reproduction in any medium, provided the original work is properly cited.

ABSTRACT

Ulnar nerve compression at the Guyon's canal is an uncommon cause of ulnar nerve neuropathy. Among various reasons like trauma, non-union of hook of hamate, anomalous muscle anatomy, thrombosis of the ulnar artery or pseudoaneurysm, ganglion is a common lesion which can compress the ulnar nerve at this site. With proper history taking and physical examination consisting of assessing motor functions and sensation of the hand, a clinician can localize the site of the lesion. Ultrasound is cheap and non-invasive technique which helps to localize the site of lesion and can suggest the nature of the lesion. Surgical decompression of the canal and careful removal of the lesion can help ameliorate the symptoms. In our study the patient presented with sudden onset weakness of the right hand and symptoms progressing within one and half month. With proper muscle charting, sensory examination and with the help of sonography, the main culprit was localized to Guyon's canal. Excision of the lesion helped in recovery of hand function within 5 months.

Keywords: Guyon's canal, Ulnar nerve, Ganglion

INTRODUCTION

The most common site of the ulnar nerve compression is at elbow in the region of cubital tunnel and less commonly at the wrist in the Guyon's canal. At the level of the wrist, the nerve travel superficial to the flexor retinaculum and enter the hand through the Guyon's canal and divide into superficial and deep branches. The site of nerve compression influences the symptoms. The nerve compressed proximal to the bifurcation yields both motor and sensory symptoms; compression along the deep motor branch produces pure motor symptom and the compression along the superficial branch produces pure sensory changes.

There are number of causes for ulnar nerve compression in Guyon's canal such as acute trauma, hamate hook non-union, anomalous muscle, or space occupying lesion like ganglion, thrombosis and pseudoaneurysms. Ganglion

itself is a very rare cause of ulnar nerve compression in Guyon's canal.¹



Figure 1: The ulnar nerve passes through the Guyon's canal between the volar carpal ligament and the transverse carpal ligament. ADQ, Abductor digiti quinti; FCU, Flexor carpi ulnaris; FDQ, Flexor digiti quinti; H, Hamate; ODQ, Opponens digiti quinti; P, Pisiform.

CASE REPORT

A 65 years old man presented with the chief complaint of acute onset of weakness in right hand, feeling of numbness and heaviness in little finger and nocturnal pain over ulnar volar aspect of wrist within one and half months following the event of performing the strenuous exercise. Other associated complaints were bilateral knee pain. Patient was taking drugs for hypertension and benign prostate hypertrophy.

On examination

Right elbow

There was full range of motion. There was no palpable swelling. Mild tenderness was present below the medial epicondyle. There was wasting of interossei muscles and clawing of the little and ring finger.

Motor examination

Flexor carpi ulnaris = 4/5

Flexor digitorum profundo's of little finger = 4/5

Hypothenar muscles = 0/5

Adductor pollicis brevis = 0/5

Flexor pollicis brevis = 0/5

Abductor pollicis brevis = 4/5

First dorsal interossei = 0/5

Sensory examination

Hypoesthesia was present along little and ring finger. Pin prick sensation was present. Two points discrimination was decreased. The patient couldn't appreciate upto 14 mm. Ulnar nerve was tender at the wrist.

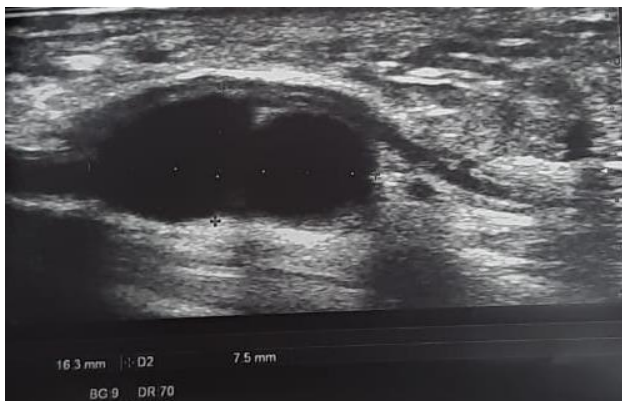

Figure 2: Ultrasound of the right ulnar nerve at the wrist level showing 16x8 mm cystic lesion compressing the ulnar nerve in the Guyon's canal.

An X-ray was done which was normal. An ultrasound of right ulnar nerve was done. It reported that a well-defined cystic lesion was seen in the Guyon canal appearing to arise from pisotriquetral joint causing compression over the ulnar nerve. The size of the cystic lesion was 16x8 mm. Ulnar nerve appeared to be normal along its course in arm and forearm.

The Guyon's canal was surgically explored. The neurovascular bundle was retracted. The ulnar nerve was carefully released through the Guyon's canal. A ganglion measuring about 18x10 mm was excised. The incision was closed and a bulky dressing was applied.

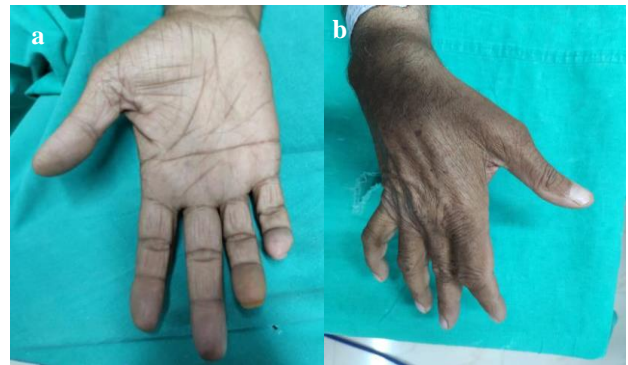

Figure 3: (a) Showing clawing of little and ring finger with wasting of hypothenar area and (b) showing wasting of first dorsal web space.

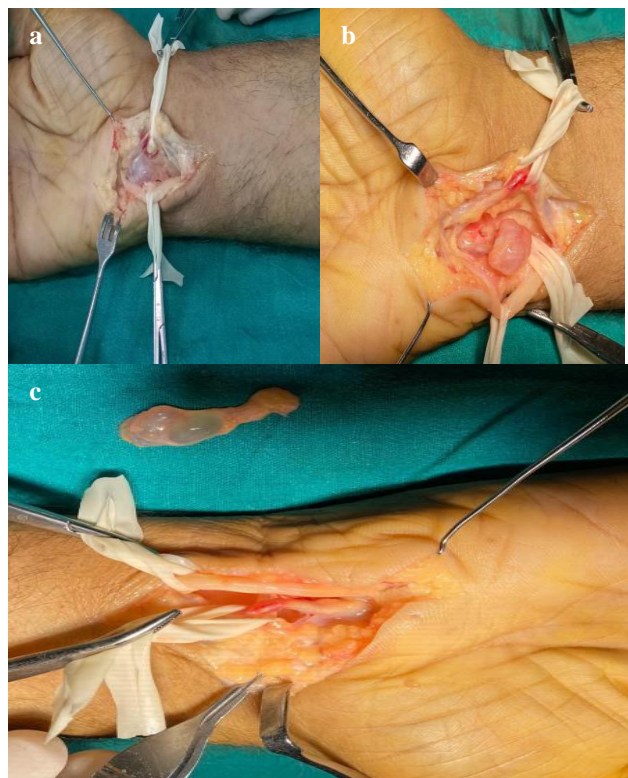


Figure 4: (a) The ulnar nerve and artery retracted in the Guyon's canal, (b) showing ganglion in the Guyon's canal and (c) Showing the excised ganglion.

At two weeks follow up suture were removed and the wound healed well. There was an improvement in sensation and the clawing persisted. At 5 months follow up time no clawing was present. There was no sensory deficit present and there was full motor recovery.

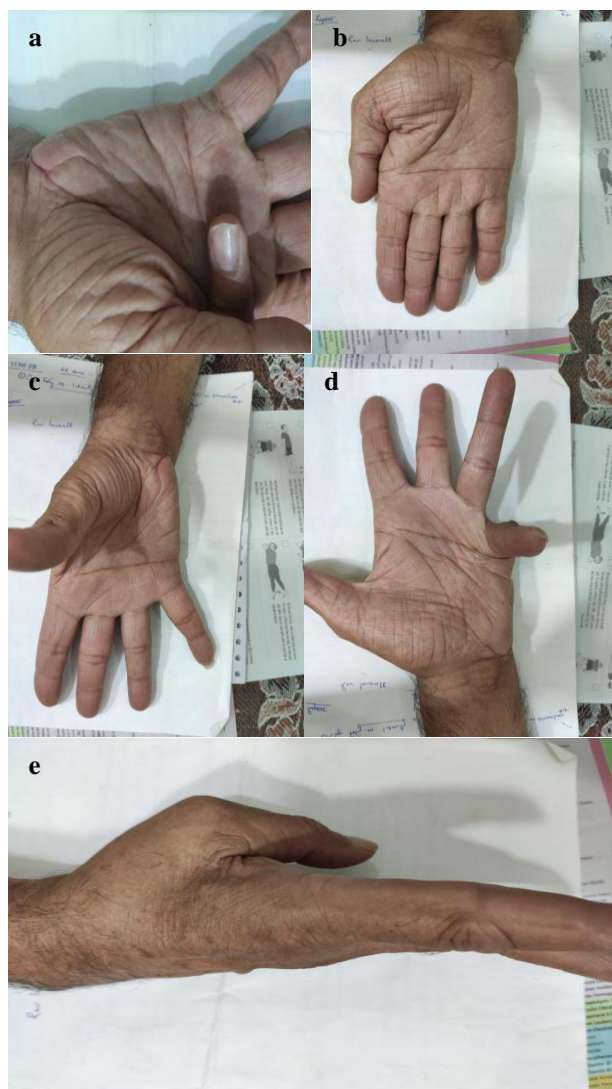


Figure 5: (a) Good recovery in flexor pollicis brevis, (b) good recovery in adductor pollicis, (c) recovery in abductor digiti minimi, (d) improved flexor digiti minimi function and (e) improved dorsal interossei muscles.

DISCUSSION

Guyon’s canal is a narrow anatomical space at the wrist through which passes the distal portion of the ulnar nerve. Its roof is formed by the volar carpal ligament and its floor by the transverse carpal ligament. Its ulnar boundary is formed by pisiform, pisohamate ligament and abductor digiti minimi. Its radial boundary is formed by the hook of hamate.² The canal is about 4 cm in length. The ulnar nerve divides into superficial sensory and deep motor branches as it passes through the canal. The course of ulnar nerve in Guyon’s canal is divided into three zones and compression

at each zone produces unique set of symptoms. Zone 1 is proximal to the nerve bifurcation into superficial and deep branch. Compression in this zone produces both mixed motor and sensory symptoms. Zone 2 is present distal to the bifurcation and any lesion in this zone compresses the deep motor branch of the nerve and produces motor symptoms. Lesion in zone 3 compresses the superficial sensory nerve hence producing sensory symptoms only.³

Injury to the distal ulnar nerve can be caused by ganglion cyst, hook of hamate fracture, tumors like lipoma, repetitive injury, aberrant muscle e.g., abductor digiti minimi and ulnar artery thrombosis or aneurysm (hypothener hammer syndrome).^{4,5}

The ulnar nerve compression in Guyon’s canal can often be confused with compression of the at the cubital tunnel. To distinguish between the two, the sensation over the dorsal ulnar aspect of the hand is checked. The dorsal ulnar cutaneous nerve provides sensation to this region and it does not pass through the Guyon’s canal and thus sensation will be preserved in case of ulnar nerve lesion in Guyon’s canal.⁶

Ganglion cysts account for 30% to 45% of Guyon syndrome cases.⁷ According to Kwak, ganglion cyst should be considered the most possible cause of ulnar nerve compression in sudden onset symptom.⁸

CONCLUSION

A thorough history and physical examination helps in making the diagnosis. Ultrasound is a cheap and non-invasive method of localizing the lesion along the ulnar nerve. Treatment is usually surgical with decompression of the ulnar nerve inside the canal and carefully excise the ganglion. Removal of the lesion helps in rapid recovery of the patient and attaining good hand function.

Funding: No funding sources

Conflict of interest: None declared

Ethical approval: Not required

REFERENCES

1. Tripathi SK, Nanda SN, Kumar S, Shah MS, Shiraz SM, Pradhan P. Compression of Ulnar Nerve by Ganglionic Cyst in Guyon’s Canal: A Case Report. *Ann Int Med Den Res.* 2016;2(4):52-3.
2. Ramage JL, Varacallo M. *Stat Pearls* [Internet], Stat Pearls Publishing; Treasure Island (FL): Nov 27, 2018. Anatomy, Shoulder and Upper Limb, Hand Guyon Canal.
3. Shea JD, McClain EJ. Ulnar-nerve compression syndromes at and below the wrist. *J Bone Joint Surg Am.* 1969;51:1095-103.
4. Depukat P, Mizia E, Kuniewicz M, Bonczar T, Mazur M, Pelka P, et al. Syndrome of canal of Guyon - definition, diagnosis, treatment and complication. *Folia Med Cracov.* 2015;55(1):17-23.

5. Brown CK, Stainsby B, Sovak G. Guyon Canal Syndrome: lack of management in a case of unresolved handlebar palsy. *J Can Chiropr Assoc.* 2014;58(4):413-20.
6. Coraci D, Loreti C, Piccinini G, Doneddu PE, Biscotti S, Padua L. Ulnar neuropathy at wrist: entrapment at a very "congested" site. *Neurol Sci.* 2018;39(8):1325-31.
7. Aleksenko D, Varacallo M. Stat Pearls, Stat Pearls Publishing; Treasure Island (FL): May 5, 2019. Guyon Canal Syndrome. 2019.
8. Kwak KW, Kim MS, Chang CH, Kim SH. Ulnar Nerve Compression in Guyon's Canal by Ganglion Cyst. *J Korean Neurosurg Soc.* 2011;49:139-41.

Cite this article as: Kaur E, Saini N. An unusual presentation of low ulnar nerve palsy: a case report. *Int J Res Orthop* 2021;7:416-9.