

## Original Research Article

# The role of newer anticoagulants in prevention of deep vein thrombosis following joint replacements

Anandha Prabu\*, Jambu N., Ganesh Babu

Department of Orthopaedics, Sri Ramachandra University, Porur, India

**Received:** 09 November 2016

**Accepted:** 25 November 2016

**\*Correspondence:**

Dr. Anandha Prabu,

E-mail: vaprabu@gmail.com

**Copyright:** © the author(s), publisher and licensee Medip Academy. This is an open-access article distributed under the terms of the Creative Commons Attribution Non-Commercial License, which permits unrestricted non-commercial use, distribution, and reproduction in any medium, provided the original work is properly cited.

### ABSTRACT

**Background:** Deep vein thrombosis following orthopedic surgeries particularly hip and knee arthroplasty is due to the accompanying blood vessel trauma, venous stasis, coagulation activation and older age in most of the patients. This study aims to study the efficacy of newer anticoagulants such as direct thrombin and direct factor Xa inhibitors in prevention of deep vein thrombosis (DVT) following arthroplasties.

**Methods:** Tablet Apixaban 2.5 mg twice daily was administered for 15 days following total knee replacement (TKR) and 30 days following total hip replacement (THR) or hemiarthroplasties. Patients were examined clinically and radiologically with colour doppler of both lower limbs from 5th-13th and 30th-42th day postoperatively during follow up.

**Results:** Only 3 out of 53 patients who underwent hip/knee arthroplasty developed DVT ( $p < 0.05$ ) which were found to be significant.

**Conclusions:** The prevention of DVT in hip and knee arthroplasty using newer anticoagulant Apixaban was more efficacious, well tolerated with low rate of bleeding.

**Keywords:** Deep vein thrombosis, Hip and knee arthroplasty, Apixaban

### INTRODUCTION

Venous thromboembolism comprises of deep vein thrombosis (DVT) and pulmonary embolism (PE). Exact incidence of venous thromboembolism is not known, approximately one third of these cases of pulmonary emboli and the remaining two third are non-fatal episodes of symptomatic deep vein thrombosis of pulmonary embolism.<sup>1</sup> The introduction of prophylactic anti-coagulant for patient undergoing hip and knee arthroplasties. Asymptomatic or symptomatic incidence of DVT is nearly 50% when no anti-coagulant is used. However there are limitations such as parenteral administration, need for lab monitoring and dose adjustment, hence newer anti-coagulants such as direct thrombin inhibitors (dabigatran etexilate) and direct

factor Xa inhibitors (Rivaroxaban, Apixaban) were developed to overcome the above limitations.<sup>2</sup>

### METHODS

This study included 53 patients above the age of 30 who had underwent joint replacement in Sri Ramachandra University, Porur from August 2013 to September 2015. Patients with history of trauma, DVT and hypercoagulable states were excluded from the study. Tablet Apixaban 2.5 mg was administered twice daily for 15 days following total knee replacement (TKR) and 30 days following total hip replacement (THR) or hemiarthroplasties (HEMI). Clinical and radiological assessment with Homan's sign and colour Doppler linear peripheral vascular probe of 12 megahertz were used preoperatively to rule out any pre-

existing condition and postoperatively at 5<sup>th</sup>-13<sup>th</sup> day and 30<sup>th</sup>-42<sup>nd</sup> day during follow up to diagnose any venous thromboembolism. All the patients were educated about DVT and were thought passive ankle mobilization exercises and were asked to be adequately hydrated.

**RESULTS**

Out of the 53 patients involved in the study of which 22 were male and 31 were female. 3 patients out of 53 developed DVT postoperatively. Out of the 5.7% of patients who developed DVT 66% of them had undergone hemiarthroplasty and the remaining total knee replacement.

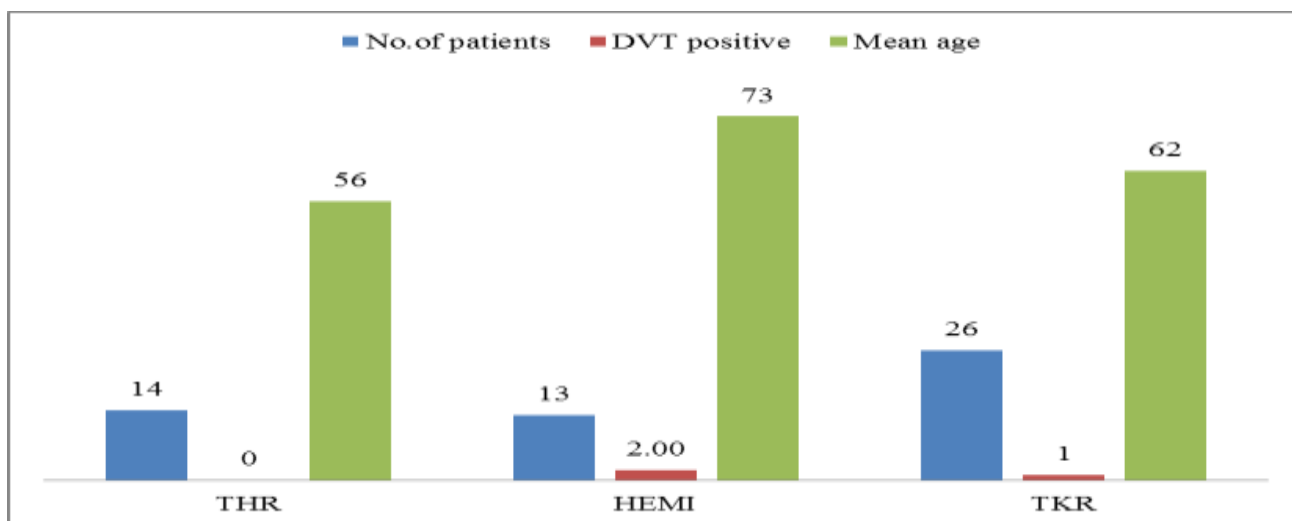
The incidence of DVT was found to be present in above 60 years of age with 66% being more than 70 years of age. Similarly in the group that was diagnosed to have DVT had a mean postoperative immobility period of 9.83 days whereas it was only 6.96 in case of those who had not developed DVT.

**Table 1: Age distribution.**

Age	No of patients	Percentage (%)	DVT positive	DVT %
<41	2	3.8	0	0
41-50	7	13.2	0	0
51-60	11	20.8	0	0
61-70	19	35.8	1	5.26
>70	14	26.4	2	14.28
<b>Total</b>	<b>53</b>		<b>3</b>	<b>5.7</b>

**Table 2: Mean age distribution based on surgery.**

Surgery	No of patients	Mean age	Std dev	DVT positive
<b>THR</b>	14 (26.4%)	56.35	12.82	0 (0%)
<b>HEMI</b>	13 (24.5%)	72.80	9.22	2 (15.4%)
<b>TKR</b>	26 (49.1%)	61.78	9.73	1 (3.8%)
<b>Total</b>	<b>53 (100%)</b>	<b>63.8</b>	<b>63.38</b>	<b>3 (5.7%)</b>



**Figure 1: Type of arthroplasty distribution.**

**Table 3: Mean postoperative immobility.**

Postoperative immobility	No of patients	Mean (days)
<b>DVT +group</b>	3	9.83
<b>DVT -group</b>	50	6.93

**DISCUSSION**

In our study the incidence of DVT in patients following joint arthroplasties after receiving newer anticoagulants was found to be 5.7%. Most of the studies on the incidence of DVT, the incidence is found to be high in western countries. Handley and Emerson et al reporting from United Kingdom showed prevalence of 45-85% of patients undergoing surgery round the hip and knee without usage of prophylactic anticoagulants.<sup>3</sup> Dhillon et al in Malaysia showed the incidence of deep vein thrombosis in patients who underwent surgery for

fracture of proximal femur or for total hip/knee replacement was 62.5%.<sup>4</sup> Though some groups claimed very high incidence of DVT others have shown it to be less in Asian and african community.<sup>5</sup> A prospective study done by SSR Murthy et al showed the overall incidence of deep vein thrombosis in Indians was 3.3% it was 1.3% by clinical methods and 2.65% by ultrasound examination alone.<sup>6</sup> However the methodology used by different authors vary, in this study clinical examination and colour Doppler were used.

Mean age group of people who developed in this study was 63.8 years similar studies done by Adis et al has shown that the risk of deep vein thrombosis increases with age and is extremely high in older patients who undergo major orthopaedic surgery without prophylaxis.<sup>7</sup> With the mean age for THR and TKR being 69 and 73 years respectively according to a study conducted by Bjonara et al.<sup>8</sup>

Our study showed an increased incidence of DVT in females similar to study by Bjornara et al, while the study by Rajagopalan et al showed an increased incidence in males.<sup>8,9</sup> Another parameter observed was that cemented replacements had greater chances of developing DVT than non cemented as in 2 out of 9 patients who underwent cemented hip arthroplasties developed DVT.

The mean postoperative immobility period was 9.83 in the patients who developed DVT whereas the post-op immobility period was 6.96 in case of people who had not developed DVT during follow up.<sup>10</sup>

The incidence of DVT in our study was 5.7% following the administration of Tablet Apixaban, a newer anticoagulant was more effective in preventing DVT without increasing bleeding events in our study. A similar study done by Lassen et al compared Apixaban and Enoxaparin for thromboprophylaxis following joint replacements. 1949 patients in the Apixaban (72%) and 1917 patients in the Enoxaparin group (71%) were evaluated for primary efficacy analysis. Of which 1.47% patients in the Apixaban group when compared to 3.9% in Enoxaparin hence showing that Apixaban to be more effective than the other.

## CONCLUSION

The prevention of deep vein thrombosis of hip and knee arthroplasty using newer anticoagulant Apixaban was more efficacious well tolerated based on clinical and radiological assessment.

*Funding: No funding sources*

*Conflict of interest: None declared*

*Ethical approval: The study was approved by the institutional ethics committee*

## REFERENCES

1. Heit JA, Cohen AT, Anderson FA. Estimated annual number incident and recurrent, non-fatal and fatal venous thromboembolism (VTE) events in the US. *ASH Annual Meeting Abstracts*. 2005;106(11):910.
2. Hirsh J, Donnell MO, Eikelboom JW. Beyond unfractionated heparin and warfarin: current and future advances. *Circulation*. 2007;116(5):552-60.
3. Dillon KS, Ashanker A, Doraisamy S. Postoperative deep vein thrombosis in Asian patients is not a rarity. *JBJS (Br)*. 1996;78(3):427-9.
4. Handley AJ, Emerson PA, Fleming PR. Heparin in the prevention of deep vein thrombosis after myocardial infarction. *Br Med J*. 1972;7:436.
5. Burkit DP. Varicose veins, deep vein thrombosis and hemorrhoids. *Epidemiology and suggested etiology*. *Br Med J*. 1972;2:556.
6. Murthy SSR, Rao PLNG, Sodhi JS. Postoperative deep vein thrombosis. *J Asso Phy Ind*. 1979;27:239-45.
7. Adis International. Increased Need for Thromboprophylaxis in older Orthopaedic surgery patients. *Drug and Ther Perspect*. 2000;16(8):12-6.
8. Bjornara BT, Godmundsen TE, Dahl OE. Frequency and timing of clinical venous thromboembolism after major surgery. *J Bone Joints (Br)*. 2006;88:386-91.
9. Rajagopalan N. Thromboprophylaxis by dalheparin sodium in elective major orthopaedic surgery. *Indian J Orthop*. 2003;37(2):94-7.
10. Pearse EO, Caldwell BF, Lockwood RJ, Hollard J. Early mobilization and conventional knee replacement may reduce the risk of postoperative venous thromboembolism. *J bone Joint Surg [Br]*. 2007;89:316-22.

**Cite this article as:** Prabu A, Jambu N, Babu G. The role of newer anticoagulants in prevention of deep vein thrombosis following joint replacements. *Int J Res Orthop* 2017;3:4-6.