

# An Efficient Approach of Optic Disc Normalization and Segmentation for Glaucoma Detection

Pooja Koushik M  
Pg Student, E & C Dept, Dbit  
Bangalore, Karnataka, India

Tejaswini M. L  
Asst. Professor, E & C Dept, Dbit  
Bangalore, Karnataka, India

**Abstract:**-Glaucoma is considered as one of the major eye disease which will lead to vision loss if it is not diagnosed at a right time. Hence it is required to recognize the stage of the disease as early as possible. The earlier methods called Intra ocular pressure(IOP) and Visual Field Test have a disadvantage of requirement of special equipment which will be available in only specialized hospitals and provide low accuracy. In this paper effective method called Sparse Dissimilarity Constrained Coding (SDC) have been used where it considers optic disc and cup called cup to disc ratio (CDR). In this approach the optic disc is localized and segmented which is followed by cup segmentation. From which the area of optic disc and optic cup is obtained. The method gives accurate CDR results and it is well suited for more population. From the obtained ratio the stage of the disease can be well predicted and suitable treatment required can be suggested. The retinal fundus images that are used for the method will be easily available in almost all the hospitals and medical centers for comparing the result with the reference CDR ratios. The method provides efficient and reliable result compared to the manual method. Hence the proposed method is an effective approach for glaucoma detection.

**Keywords:** IOP, Cup to Disc Ratio, Sparse Dissimilarity Constraint

\*\*\*\*\*

## INTRODUCTION

This paper focuses on computing the CDR from the disc. Motivated from the observation that similar discs often have very similar CDRs and the fact that many discs do not have obvious boundary between neuroretinal rim and the optic cup, we propose a sparse dissimilarity-constrained coding (SDC) to estimate the CDR for a new disc image. In comparison with the LLC method which uses the Gaussian distance, the proposed method computes the dissimilarities between the testing disc images and the reference disc images from their overall intensity changes and use them as the dissimilarity constraint in the SDC-based disc reconstruction. Several major factors that often affect the disc dissimilarity computation and the disc reconstruction have been considered, including BVs, uneven illumination within each disc image, and the illumination changes between different images. In addition, a sparsity constraint is also included in SDC inspired from the observation that a few reference disc images closest to the testing disc image are usually sufficient to estimate its CDR.

Optic disc segmentation from retinal fundus image is a fundamental but important step in many applications such as automated glaucoma detection. Very often, one method might work well on many images but fail on some other images and it is difficult to have a single method or model to cover all scenarios. Therefore, it is important to combine results from several methods to minimize the risk of failure.

However, it has a bias of underestimating large cups and overestimating small cups due to the dominance of medium sized cups used to train the model. Very often, these methods rely on the contrast between the cup and the neuro-retinal rim to find the cup boundary for CDR computation and can be challenging to use effectively when the contrast is weak.

## EXISTING SYSTEM

Assessment of raised intraocular pressure (IOP) is the method previously used to detect glaucoma. In the previous work on "Classifying glaucoma with image-based features from fundus photographs", the features are normally computed at the image-level and we use image features for a binary classification between glaucomatous and healthy subjects.

## PROPOSED SYSTEM

This paper is for the automated CDR assessment from 2-D fundus images. This paper focuses on computing the CDR from the disc. In order to compute the CDR using the proposed SDC, it is important to locate and segment the disc. The disc localization focuses on finding an approximate location of the disc, very often the disc center. In this paper, we segment the disc using the self-assessed disc segmentation method, which is a combination of three approaches (Superpixels Segmentation, Edge Detection and Circular Hough Transform). The disc normalization process which includes background removal and the Disc Uneven Illumination Correction is also to be done. It has been shown that the self-assessed approach achieves more accurate disc segmentation than the individual methods. Motivated from the observation that similar discs often have very similar CDRs and the fact that many discs do not have obvious boundary between neuro-retinal rim and the optic cup, we propose a sparse dissimilarity-constrained coding (SDC) to estimate the CDR for a new disc image.

## PROPOSED TECHNIQUE

- Contrast Limited Adaptive Histogram Equalization (CLAHE)
- Simple Linear Iterative Clustering (SLIC) Algorithm
- Canny Edge Detection

- Circular Hough Transform
- Sparse dissimilarity-constrained coding (SDC)
- Thresholding and Morphological operations

#### OPTIC DISK NORMALIZATION

All disc images from right eyes are flipped horizontally to avoid the difference between the left and right eyes. The mean intensity is also removed to avoid the difference due to different illuminations in different disc images. Besides that, we also conduct Blood Vessel (BV) removal and within disc uneven illumination correction.

#### OPTIC DISK SEGMENTATION

The optic disk is segmented by using Otsu thresholding algorithm. The thresholding level was computed. Based on the thresholding level, the grayscale retina image was converted to black and white image in which, the centre portion, i.e., the optic disk alone will be in white color and the background will be in black color.

#### OPTIC CUP SEGMENTATION

The cup is present inside the disk region. It was segmented by using morphological operations such as morphological opening, closing, dilation and erosion. Dilation-technique used to expand the pixel area in the image. Erosion-used to erode/reduce the pixel area

#### CUP TO DISK RATIO (CDR)

- Based on the Area occupied by the segmented disk and the cup, CDR is computed. The optic disk and optic cup segmented image is given as the input. The CDR ratio is obtained at the output.
- $CDR = \text{Area of cup} / \text{Area of Disc}$ .

#### PROPOSED ADVANTAGES

The proposed method computes the dissimilarities between the testing disc images and the reference disc images from their overall intensity changes and uses them as the dissimilarity constraint in the SDC-based disc reconstruction. Several major factors that often affect the disc dissimilarity computation and the disc reconstruction have been considered, including BVs, uneven illumination within each disc image, and the illumination changes between different images. we segment the disc using the disc segmentation method in which first preprocessing such as image filtration, color contrast enhancement are performed which is followed by a combined approach for image segmentation and classification using texture, thresholding and morphological operation for segmenting the Optic Cup. Based on the segmented disc and cup, CDR is computed for glaucoma screening.

#### EXPERIMENTAL RESULTS

For the below given input retinal image the obtained result is as follows:

Area of Optic Disc:3470

Area Of Optic Cup:2390

Cup to Disc Ratio:0.6888

According to the CDR value it has been diagnosed as severe Glaucoma.

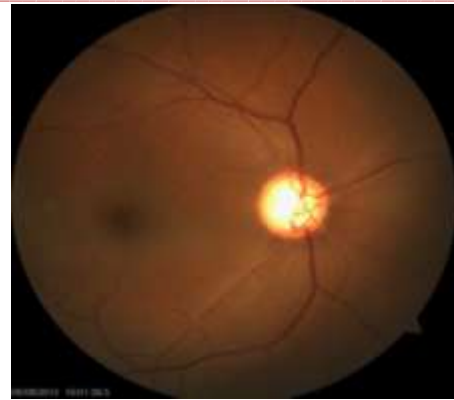




Fig: Input Retinal Image



(a) Extracted Disc  
(b)



(b) Extracted Cup

#### CONCLUSION

Glaucoma is one of the major causes which cause blindness but it was hard to diagnose it in early stages. The proposed method for cup to disc ratio (CDR) assessment using 2-D retinal fundus images approach is modular, we can expect further improvements by adding more preprocessing methods and normalization techniques. However, a proper screening system should contain other components, which is expected to increase the performance of this approach, as well.

#### ACKNOWLEDGEMENT:

I wish to express gratitude to my guide Mrs. Tejaswini M.L. who has helped me in preparing this paper.

## REFERENCES

- [1] H. A. Quigley and A. T. Broman, "The number of people with glaucoma worldwide in 2010 and 2020," *Brit. J. Ophthalmol.*, vol. 90, no. 3, pp. 262–267, 2006.
- [2] M. D. Abramoff *et al.*, "Automated segmentation of the optic disc from stereo color photographs using physiologically plausible features," *Investigative Ophthalmol. Vis. Sci.*, vol. 48, pp. 1665–1673, 2007
- [3] M. D. Abramoff *et al.*, "Automated segmentation of the cup and rim from spectral domain OCT of the optic nerve head," *Investigative Ophthalmol. Vis. Sci.*, vol. 50, pp. 5778–5784, 2009.
- [4] J. Meier *et al.*, "Effects of preprocessing eye fundus images on appearance based glaucoma classification," in *Proc. 12th Int. Conf. Comput. Anal. Images Patterns*, 2007, pp. 165–172.
- [5] "G. D. Joshi *et al.*, "Optic disk and cup segmentation from monocular color retinal images for glaucoma assessment," *IEEE Trans. Med. Imag.*, vol. 30, no. 6, pp. 1192–1205, Jun. 2011.
- [6] F. Yin *et al.*, "Automated segmentation of optic disc and optic cup in fundus images for glaucoma diagnosis," in *Proc. IEEE Int. Symp. Comput.-Based Med. Syst.*, 2012, pp. 1–6.
- [7] J. Cheng *et al.*, "Superpixel classification based optic disc and optic cup segmentation for glaucoma screening," *IEEE Trans. Med. Imag.*, vol. 32, no. 6, pp. 1019–1032, Jun. 2013.
- [8] M. Abramoff, M. Niemeijer, M. Suttorp-Schulten, M. A. Viergever, S. R. Russel, and B. van Ginneken, "Evaluation of a system for automatic detection of diabetic retinopathy from color fundus photographs in a large population of patients with diabetes," *Diabetes Care*, vol. 31, pp. 193–198, 2008.
- [9] A. D. Fleming, K. A. Goatman, S. Philip, G. J. Prescott, P. F. Sharp, and J. A. Olson, "Automated grading for diabetic retinopathy: A large-scale audit using arbitration by clinical experts," *Br. J. Ophthalmol.*, vol. 94, no. 12, pp. 1606–1610, 2010.
- [10] H. J. Jelinek, M. J. Cree, D. Worsley, A. Luckie, and P. Nixon, "An automated microaneurysm detector as a tool for identification of diabetic retinopathy in rural optometric practice," *Clin. Exp. Optom.*, vol. 89, no. 5, pp. 299–305, 2006.



Tejaswini M L Received BE degree (Telecommunication Engineering) from APS College of Engineering, VTU, Bangalore, India in 2004. The MTech degree from Dayanandasagar college of engineering (VLSI Design and Embedded Systems), VTU, Bangalore, India in 2008. Currently working as Assistant Professor in Department of ECE, DBIT, Bangalore, India.



Pooja Koushik M Received BE degree from Dr. Ambedkar Institute Of Technology, VTU, Bangalore, India in 2013. Currently PG student in Don Bosco Institute Of Technology, Bangalore, India.