

Original Research Article

Evaluation of functional outcome of lumbar spondylolisthesis treated with posterior lumbar interbody fusion with instrumentation

K. S. Raja, M. Ravi*

Department of Orthopaedics, Government Dharmapuri Medical College and Hospital, Dharmapuri, Tamil Nadu, India

Received: 07 March 2018

Revised: 15 April 2018

Accepted: 17 April 2018

***Correspondence:**

Dr. M. Ravi,

E-mail: ravi.ortho@yahoo.co.in

Copyright: © the author(s), publisher and licensee Medip Academy. This is an open-access article distributed under the terms of the Creative Commons Attribution Non-Commercial License, which permits unrestricted non-commercial use, distribution, and reproduction in any medium, provided the original work is properly cited.

ABSTRACT

Background: Spondylolisthesis with or without spondylolysis occurs in 5% to 8% of the adult population. It is commonly believed that spondylolysis does not exist at birth. The incidence is 4.4% to 5% at the age of 6 years, increasing to 6% at the age of 18 years, which is quite similar to that observed in adulthood. To analyze the functional outcome of posterior stabilization by pedicle screws with decompression and interbody fusion by PLIF (Posterior Lumbar Interbody Fusion) technique in adult single level spondylolisthesis. In this study our aim is to analyze the correlation between the degrees of fusion with functional outcomes.

Methods: This is a prospective study of 20 patients carried out in the Department of Orthopaedics, Govt. Dharmapuri Medical College Hospital, Dharmapuri from January 2016 to December 2017. All patients were evaluated with anteroposterior, lateral and oblique radiographs of the lumbosacral spine. Dynamic plain radiographs of all our patients showed instability. CT/MRI evaluation of all patients was done.

Results: In our study four patients (20%) had a complete reduction of the preoperative slip, fourteen patients (70%) showed a reduction of slip by one grade, while in two patients (10%) there was no change from the preoperative slip percentage.

Conclusions: Further, three dimensional multislice thin section CT scans with multiplanar reconstruction are ideal to study the incorporation of the bone graft within the disc space.

Keywords: Lumbar spondylolisthesis, Computed tomography, Posterior lumbar interbody fusion

INTRODUCTION

Spondylolisthesis is defined as forward displacement of a cephaloid vertebra over a vertebra caudal to it. The term spondylolisthesis is derived from two Greek words: spondylosis, meaning 'vertebra', and olisthenein, meaning 'to slip or to slide'.¹ The term 'spondylolysis' represents a local bony defect in the pars interarticularis of the vertebra that may be either unilateral or bilateral.² In a complete bilateral pars defect, spondylolysis may lead to spondylolisthesis, whereby the vertebral body together with the pedicles, the transverse processes and the superior articular facets are separated from the

laminae, the spinous process and the inferior articular facets.³ Spondylolisthesis (anterolisthesis) may occur with a defect in the vertebral arch (spondylolysis spondylolisthesis) or without a defect in the vertebral arch (non-spondylolysis spondylolisthesis). Spondylolisthesis with or without spondylolysis occurs in 5% to 8% of the adult population.⁴

It is commonly believed that spondylolysis does not exist at birth. The incidence is 4.4% to 5% at the age of 6 years, increasing to 6% at the age of 18 years, which is quite similar to that observed in adulthood.⁵ The lumbar spine and the lumbosacral junction are the keystone of

the axial skeleton. They function to provide stability by supporting physiologic loads, preventing no physiologic motion, and protecting the neural elements.⁶ In static and dynamic equipoise, stability of the spine is rendered by the overall coronal and sagittal balance of the spinal column and the integrity of the osteo-discal-ligamentous complex.⁷ At the lumbosacral junction, stability is dependent on the spatial orientation of L5 to the sacrum, as well as an intact osteo-discal-ligamentous complex. Because spinal parameters are dependent on pelvic parameters, a condition like spondylolisthesis, which produces an alteration in the spatial orientation can produce global spinal imbalance.⁸ Progression of spondylolisthesis increases with age, beginning at about 8 years in girls and 12 years in boys. At first, the condition is asymptomatic, and by the time pain is experienced, 90% of the patients show a slippage of less than 30%.⁹

These patients are treated initially by conservative measures, failing which surgical intervention is mandatory. Numerous studies prove that reduction of severe high grade spondylolisthesis is essential, whereas low grade listhesis depending on the etiology, can be managed by no operative or in unrelenting cases by a wide array of operative methods.¹⁰ The spectrum of available surgical options include pars repair in spondylosis, instrumented in situ fusion, instrumented reduction and fusion or instrumented in situ fusion which may be a posterior, posterolateral, anterior or circumferential fusion that could be achieved by a variety of techniques.¹¹

We in our study have managed spondylolisthesis in adults with posterior stabilization by pedicle screws with decompression and interbody fusion by posterior lumbar interbody fusion (PLIF) techniques. In addition to the routine clinical, radiological and functional outcome evaluations, we have correlated the interbody fusion with patient's functional outcome, by using standard scoring systems.¹²

METHODS

This is a prospective study of 20 patients carried out in the Department of Orthopaedics, Govt. Dharmapuri Medical College Hospital, Dharmapuri from January 2016 to December 2017. The inclusion criteria were Symptomatic Meyerding Grade I to Grade IV spondylolisthesis, patients with single level spondylolisthesis between L3-S1 with failure to respond with conservative treatment and the age group was 20 to 65 years. The exclusion criteria were Pathologic and traumatic spondylolisthesis, meyerding Grade V spondylolisthesis or spondyloptosis, and age <20 and >65 years patients with previous lumbar surgery.

All our twenty patients had unrelenting back pain that had not responded to conservative treatment and associated with or without neurogenic intermittent claudication. The mean duration of symptoms during the

initial presentation was one year. Neurology was unremarkable in most of our patients. Six out of twenty patients presented with EHL, FHL weakness. Two patients presented with weakness of ankle dorsiflexion.

All patients were evaluated with anteroposterior, lateral and oblique radiographs of the lumbosacral spine. Dynamic plain radiographs of all our patients showed instability. CT/MRI evaluation of all patients was done to evaluate facet joint pathology, sacralisation/lumbarisation, the condition of the disc, neural canal and foramina stenosis and nerve root involvement. Detailed observations with regard to complications encountered if any during the intraoperative, postoperative periods and during follow up visits were noted.

Patients were followed up regularly every month during the first 3 months and thereafter every 3 months during the first year. A complete physical examination was done during each follow up visit. The straight leg-raising test was performed and was considered positive if it caused radiating pain from the lower back to leg below knee level. Muscle strengths for great toe extension and ankle dorsiflexion and plantar flexion (normal/decreased/absent) were tested together with skin touch sensitivity (normal/decreased/absent) in the dermatomes of L3-S1. Radiographic evaluation was done in the immediate post-operative period and at 1 month, 6 months, 12 months and at 24 months using plain anteroposterior and lateral radiographs. Reduction of slip and maintenance of disc height was assessed in the immediate post-operative period and during the first and final follow up visits.

Functional outcome evaluation was done during the final follow up using ODI (Oswestry disability index). In our study all patients were subjected to a multiline helical computed tomography scan with multiplanar reconstruction, at an average time of 14 months post-surgery to analyse posterior lumbar interbody fusion, bone graft retropulsion and screw position. The correlation between the degree of fusion and the patient's functional outcome during the final follow up was analysed.

RESULTS

In our study the commonest level involved was L4- L5 with 10 cases, 50% of the total cases followed by L5- S1 level (8 cases, 40%) and L3-4 level (2 cases, 10%).

There was predominance of Grade II listhesis in our study. 10 out of 20 patients 50% have Grade II listhesis. 6 patients 30% have Grade III listhesis. 4 patients 20% have Grade I listheis.

There was predominance of degenerative listhesis in our study. 12 out of 20 patients 60% have degenerative listhesis. 8 patients 40% have isthmic type of spondylolisthesis.

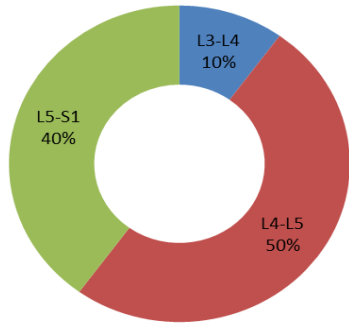


Figure 1: Shows the level involvement.

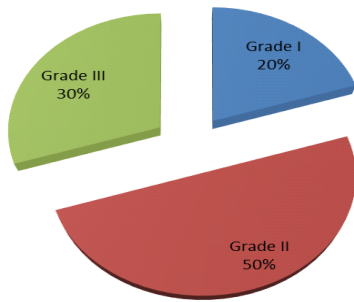


Figure 2: Shows the grade of listhesis.

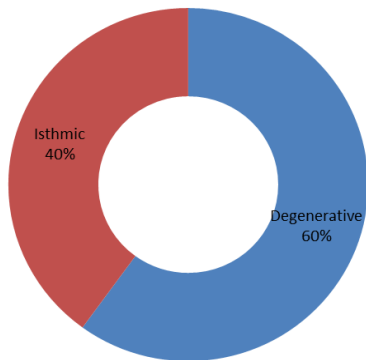


Figure 3: Type of listhesis.

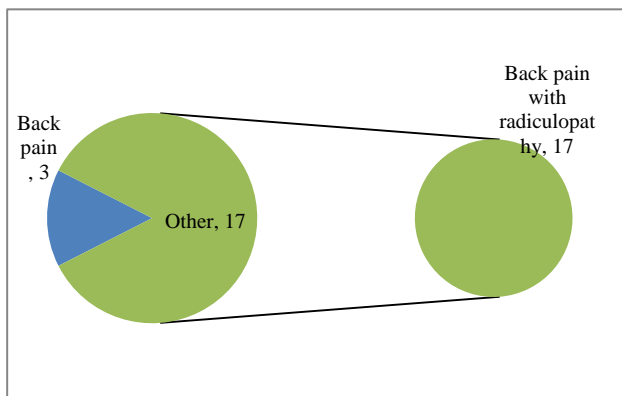


Figure 4: Clinical presentation.

All twenty patients had unremitting back pain that had not responded to conservative treatment. Three patients (15%) presented with back pain as their only symptom. Four patients (20%) also had back pain with pain radiating to one or both lower limbs. Thirteen patients (65%) presented with back pain, radiculopathy with neurogenic claudication.

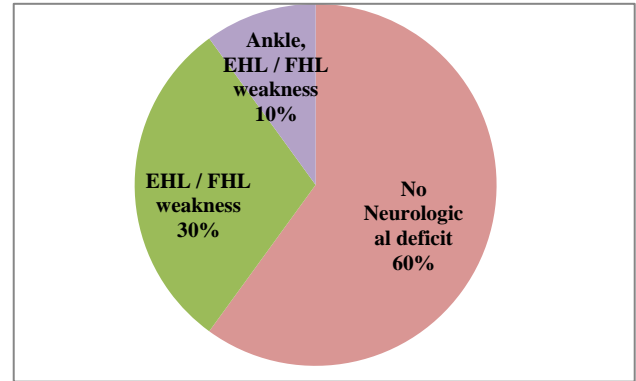


Figure 5: Neurology presentation.

Neurology was unremarkable in twelve patients (60%). six out of twenty patients (30%) presented with EHL and FHL weakness. Two patients (10%) presented with weakness of ankle dorsiflexion, EHL and FHL weakness.

In our study we used morselized posterior element as bone graft in ten patients (50%) and posterior iliac graft used as bone graft in 10 patients (50%) for interbody fusion.

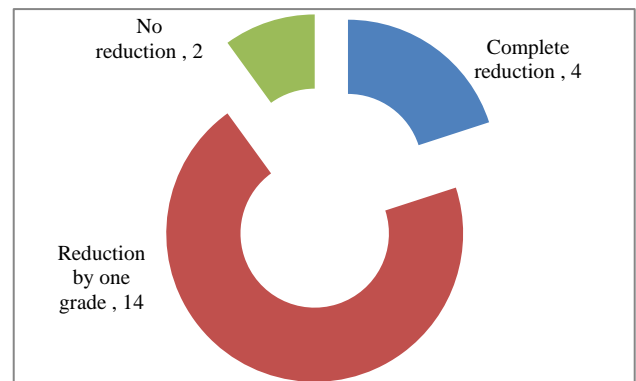


Figure 6: Reduction of slip.

In our study four patients (20%) had a complete reduction of the preoperative slip, fourteen patients (70%) showed a reduction of slip by one grade, while in two patients (10%) there was no change from the preoperative slip percentage.

The wound infection was noticed in the postoperative period in our study was 1 case (5%) which was superficial and treated with regular dressing and intravenous antibiotics.

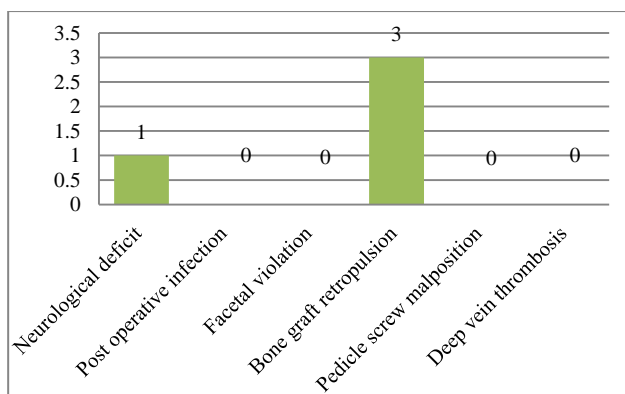


Figure 7: Complications.

DISCUSSION

The goal of stabilizing the spondylolytic level is accomplished by arthrodesis from a posterior, anterior, or combined approach; depending on the severity and clinical features of the spondylolisthesis.¹³ The interbody fusion immediately produces a biomechanically stable postoperative spine, thus enhancing the opportunity for arthrodesis. Traditionally interbody fusion has been assessed with plain radiographs.¹⁴ For many years, dynamic lateral flexion and extension radiographs have been used to monitor the progression of an interbody arthrodesis. These films have significant intra- and inter observer variation. Measurement accuracy is also largely dependent on obtaining true lateral views; suboptimal radiographs are often obtained. Interpretation of plain radiographs is further complicated by the difficulty in judging fusion progression.¹⁵ In a study analysing the interbody fusion with plain radiographs, Dai et al found that although plain radiographs showed evidence of fusion at 6 months, only 33% were subsequently judged fused on histologic examination.¹⁶ Because of the metallic artefact associated with fixation devices, it is often difficult to evaluate spinal fusion. CT has developed into the preferred method of assessing interbody fusion. CT is rapid, offers the potential for high quality reformatted images in the coronal and sagittal planes, and provides exquisite bone detail.¹⁷ Hardware artefacts can compromise the quality of images in CT, however, the new generation metallic fusion devices using titanium result in less pronounced degradation by artefact compared with earlier stainless steel implants.¹⁸ Five patients (25%) who showed evidence of incomplete fusion on CT correlated with fair outcome scores at the final follow up.^{19,20}

CONCLUSION

In our study there was a good correlation between interbody fusion and functional outcomes. A long term study with a larger patient population with a detailed analysis of different types of interbody fusion devices could be done in future to establish the definitive role of CT in the assessment of interbody fusion.

Funding: No funding sources

Conflict of interest: None declared

Ethical approval: The study was approved by the institutional ethics committee

REFERENCES

1. Aorta Y, Kumano K, Hirabashi S. Posterior fusion instability at the adjacent segments alter rigid pedicle screw fixation for degenerative lumbar spinal disorders. *J Spinal Disorder.* 1995;8(6):464-73.
2. Bassewitz H, Herkowitz H. Lumbar stenosis with spondylolisthesis: current concepts of surgical treatment. *Clin Orthop Relat Res.* 2001;384:54-60.
3. Beckers L. Buck's operation for treatment of spondylolisthesis. 2011: 819-823.
4. Belfi LM, Ortiz AO, Katz DS. Computed tomography evaluation of spondylolysis and spondylolisthesis in asymptomatic patients. *Spine.* 2006;31(24):907-10.
5. Bendo JA, Ong B. Importance of correlating static and dynamic imaging studies in diagnosing degenerative lumbar spondylolisthesis. *Am J Orthop.* 2001;30(3):247-50.
6. Berlemann U, Jeszenszky DJ, Buhler DW, Harms J. The role of lumbar lordosis, vertebral end-plate inclination, disc height, and facet orientation in degenerative spondylolisthesis. *J Spinal Disord.* 1999;12(1):68-73.
7. Berven S, Tay BB, Colman W, Hu SS. The lumbar zygapophyseal (facet) joints: a role in the pathogenesis of spinal pain syndromes and degenerative spondylolisthesis. *Semin Neurol.* 2002;22(2):187-96.
8. Beutler WJ, Fredrickson BE, Murtland A, Sweeney CA, Grant WD, Baker D. The natural history of spondylolysis and spondylolisthesis: 45-year follow-up evaluation. *Spine.* 2003;28(10):1027-35.
9. Boachie-Adjei O, Twee D, Rawlins B. Partial lumbosacral kyphosis reduction, decompression, and posterior lumbosacral transfixation in high-grade isthmic spondylolisthesis. Clinical and radiological results in six patients. *Spine.* 2002;27:161-8.
10. Boden SD, Riew KD, Yamaguchi K, Branch TP, Schellinger D, Wiesel SW. Orientation of the lumbar facet joints: association with degenerative disc disease. *J Bone Joint Surg Am.* 1996;78(3):403-11.
11. Booth KC, Bridwell KH, Eisenberg BA, Baldus CR, Lenke LG. Minimum 5-year results of degenerative spondylolisthesis treated with decompression and instrumented posterior fusion. *Spine.* 1999;24(16):1721-7.
12. Buck J. Direct repair of the defect in spondylolisthesis. Preliminary report. *J Bone Joint Surg.* 1970;52:432-7.

13. Kimura M. My method of filling the lesion with spongy bone in spondylolysis and spondylolisthesis. *Seikei Geka.* 1968;19:285-96.
14. Cloward RB. The treatment of ruptured lumbar intervertebral disc by vertebral body fusion: indications, operative technique, after care. *J Neurosurg.* 1953;10:195-202.
15. Crawford NR, Cagli S, Sonntag VK, Dickman CA. Biomechanics of grade I degenerative lumbar spondylolisthesis. Part 1: in vitro model. *J Neurosurg.* 2001;9:45-50.
16. Dai LY, Jia LS, Yuan W, Ni B, Zhu HB. Direct repair of defect in lumbar spondylolysis and mild isthmic spondylolisthesis by bone grafting, with or without facet joint fusion. *Eur Spine J.* 2001;10(1):78-83.
17. Davne SH, Myers DL. lumbar spinal fusion with transpedicular instrumentation. *Spine.* 1992;17:184.
18. Deguchi M, Rapoff. Biomechanical comparison of spondylolysis fixation techniques. *Spine.* 2007;24:328–33.
19. Lauerma WC, Bradford DS, Ogilvie JW, Transfeldt EE. Results of lumbar pseudarthrosis repair. *J Spinal Disorder.* 2011;5:149–57.
20. Waddell G, Kummel EG, Lotto WN, Graham JD, Hall H, McCulloch JA. Failed lumbar disc surgery and repeat surgery following industrial injuries. *J Bone Joint Surg [Am].* 2012;61:201–7.

Cite this article as: Raja KS, Ravi M. Evaluation of functional outcome of lumbar spondylolisthesis treated with posterior lumbar interbody fusion with instrumentation. *Int J Res Orthop* 2018;4:629-33.